

Images in medicine

Bone lesion in Adult T Cell Lymphoma Leukemia

Zahra Mozaheb^{1,&}

¹Hematology-Oncology Department, Imam-Reza Hospital, Mashhad University of Medical Science, Mashhad, Iran

[&]Corresponding author: Zahra Mozaheb, Hematology-Oncology Department, Imam-Reza Hospital, Mashhad University of Medical Science, Mashhad, Iran

Key words: Bone lesion, Adult T Cell Lymphoma Leukemia, lytic bone lesion, HTLV1, Iran

Received: 08/04/2013 - Accepted: 04/11/2013 - Published: 04/11/2013

Pan African Medical Journal. 2013 16:76. doi:10.11604/pamj.2013.16.76.2706

This article is available online at: <http://www.panafrican-med-journal.com/content/article/16/76/full>

© Zahra Mozaheb et al. The Pan African Medical Journal - ISSN 1937-8688. This is an Open Access article distributed under the terms of the Creative Commons Attribution License (<http://creativecommons.org/licenses/by/2.0>), which permits unrestricted use, distribution, and reproduction in any medium, provided the original work is properly cited.

Image in medicine

A 57-year-old man from Khorasan Razavi presented with severe hypercalcemia and fever, with temperature up to 40°C, over a 2-week period. He also had severe headache and generalized bone pain. He was admitted and treated for hypercalcemia. After two days hypercalcemia and fever were controlled and bone pain decreased mildly but his headache continued severely. At first day of admission he was not anemic but one week later he became anemic and thrombocytopenic with atypical lymphocyte in peripheral blood smear. During patient assessment we found, hyperuricemia, elevated ESR,CRP and LDH. Skeletal radiographies showed severe lytic bone lesion, and brain CT scan was normal. Based on these data, bone marrow exam was done and serum anti HTLV1 was requested. After 3 days we noticed several depressions on the scalp and forehead of the patient because of severe bone resorption. Bone marrow exam showed a patchy lymphocyte infiltration, and serum anti HTLV1 antibody was positive. CD4 also was positive in flowcytometry. All this findings were compatible with Adult T cell Lymphoma Leukemia secondary to HTLV1 infection which is endemic in Khorasan Razavi, Iran. The patient was died before beginning of induction therapy

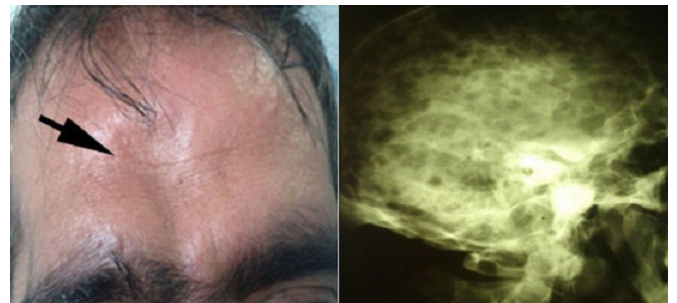


Figure 1: Bone lesion in adult T cell lymphoma leukemia