

Research

Mammographic parasitic calcifications in South West Nigeria: prospective and descriptive study

Adenike Temitayo Adeniji-Sofoluwe^{1,&}, Millicent Olunmi Obajimi¹, Abideen Olayiwola Oluwasola², Temitope O Soyemi¹

¹University of Ibadan, College of Medicine, Department of Radiology & University College Hospital, Ibadan, Nigeria, ²University of Ibadan, College of Medicine, Department of Pathology & University College Hospital, Ibadan, Nigeria

[&]Corresponding author: Adenike Temitayo Adeniji-Sofoluwe, University of Ibadan, College of Medicine, Department of Radiology & University College Hospital, Ibadan, Nigeria

Key words: Parasite, mammography, calcification

Received: 12/06/2013 - Accepted: 16/07/2013 - Published: 08/08/2013

Abstract

Introduction: Lymphatic filariasis caused by nematode parasite *Wuchereria bancrofti* and *Brugia Malayi* is endemic in the tropics. In Nigeria, 25% of the population is infected. Lymph edema and elephantiasis are the predominant manifestations. Its infrequent manifestation is in the breast. This paper discusses the epidemiology, reviews literature, imaging options and mammographic appearances of these parasitic nematodes. **Methods:** This prospective descriptive study reports on 39 cases of parasitic calcifications seen during mammography in the Radiology Department, University College Hospital between 2006 and 2012 in Ibadan, South West Nigeria. Each mammogram was reported by MO and ATS: assigned a final Bi-RADs category. Parasitic calcifications were further evaluated for distribution, and types of calcification. **Results:** A total of 527 women had mammography done between 2006 and 2012. Thirty-nine women (7.4%) had parasitic breast calcifications. The ages of the women ranged between 38-71 years - mean of 52.36±8.72 SD. Twenty-three (59%) were post-menopausal, 16(41%) were pre-menopausal. The majority (31; 79.5%) were screeners while 8(20.5%) were follow up cases. Approximately half (51.3%) of the women had no complaints. Pain (23.1%) was the commonest presentation in the remaining half. Solitary calcifications were predominant (20) while only 3 cases had 10 calcifications. Left sided calcifications (53.8%) were the majority. Calcifications were subcutaneous in 2/3rds of the women (66.7%) while the Yoruba tribe (84.6%) was principal. **Conclusion:** Parasitic breast calcifications can be misdiagnosed on mammography for suspicious micro-calcification. This publication should alert radiologists in a tropical country like Nigeria to increase diagnostic vigilance thereby preventing unnecessary anxiety and invasive work-up procedures.

Pan African Medical Journal. 2013; 15:126. doi:10.11604/pamj.2013.15.126.2958

This article is available online at: <http://www.panafrican-med-journal.com/content/article/15/126/full/>

© Adenike Temitayo Adeniji-Sofoluwe et al. The Pan African Medical Journal - ISSN 1937-8688. This is an Open Access article distributed under the terms of the Creative Commons Attribution License (<http://creativecommons.org/licenses/by/2.0>), which permits unrestricted use, distribution, and reproduction in any medium, provided the original work is properly cited.

Introduction

Filariasis is common in most tropical and subtropical countries [1]. In Nigeria, the epidemiology of the disease is complicated because of the multiplicity of the environmental conditions of the different regions [2]. The distribution is more extensive than has been described because of deteriorating drainage systems, large-scale dam and irrigation projects which have created suitable breeding sites for filarial vectors in various parts of Nigeria³. In the past six decades, various levels of endemicity of filariasis have been documented in different parts of Nigeria including Benue, Plateau, Taraba, Oyo, and Bauchi states [2-4]. One out of every three sufferers of filariasis in the tropics lives in the Federal Republic of Nigeria [5].

Lymphatic filariasis is caused by the nematode parasite *Wuchereria bancrofti* and *Brugia malayi*. Other studies show filariasis due to *Mansonella perstans* and *Mansonella streptocerca* infections vastly recorded in different parts of Nigeria [6]. It is endemic throughout the tropics [7]. It is equally distributed in both sexes [8] and affects an estimated 120 million people worldwide⁷. In Nigeria as much as 25% of the population are infected [9]. The predominant manifestations of the infection are caused by obstruction of the lymphatics which leads to lymphedema, hydrocele and elephantiasis. An infrequent manifestation is lymphatic filariasis involving the female breast [10-13].

This study of mammographic findings in 39 women in Ibadan South West Nigeria with parasitic calcification of the breast is aimed at increasing the diagnostic vigilance for the parasites thereby preventing misdiagnosis for suspicious micro-calcifications in a country that is endemic for the disease.

Methods

A prospective descriptive study carried out in the Radiology Department of the University College Hospital between 2006 and 2012. Thirty-nine (39) women were involved, out of 527 women who presented for both screening and diagnostic mammography. Informed consent was obtained from the identified women; after which an assisted questionnaire was administered before a physical examination was performed. Two standard views MLO and CC were obtained utilizing the General Electric senographe 2000 machine. Additional Spot magnification views were also obtained for evaluation of these calcifications. MO and AA reported these

mammograms and assigned a final Bi-RADs category. Details of distribution and types of calcification as well as demographics of the women with the parasitic calcifications were described. Breast ultrasound scan was additionally performed with a linear-array, 10 MHz transducer.

Results

A total of 527 women had mammography done between 2006-2012. Thirty-nine women (7.4%) had parasitic calcifications in their breast. The ages of the women ranged between 38-71years with a mean of 52.36(SD=8.725). Twenty-three (59%) were post-menopausal while 16(41%) women were pre-menopausal.

The majority 31 (79.5%) were screeners while 8(20.5%) were follow up cases. About half of the women (51.3%) had no complaints at presentation. However pain (23.1%) was the most common presentation in the remaining half.

Solitary calcifications were present the majority (20) of cases while only 3 cases had more than 10 calcifications. Parasitic calcifications were most commonly left sided (53.8%) whereas both breasts were least frequently affected (12.8%). Most calcifications seen were located in the LIQ and UOQ (38.5% and 30.8% respectively). The four quadrants of the breast were involved in only one patient. Two-thirds (66.7%) of the parasitic calcifications were subcutaneous in location (**Figure 1, Figure 2, Figure 3, Figure 4, Figure 5, Figure 6, Figure 7**).

The women were predominantly of the Yoruba tribe (84.6%) and domiciled in Ibadan (74.5%). The size of the calcifications ranged between 1-4mm. Whole breast ultrasound was performed on all women but showed no abnormality.

Discussion

Filariasis is uncommon in developed countries; where it is seen occasionally in travel immigrants from endemic areas of the disease [9, 14]. The prevalence of lymphatic filariasis is over 40 million in sub-Saharan African accounting for about 40% of all cases worldwide [15]. It is endemic in the tropics where Nigeria is situated. In Oyo state, four major rivers flow through one of the

local government areas in a north to south direction, the Ogun, Oyan, Ofiki and Opeki and these have been documented as *Simulium* breeding sites [16]. A detailed history revealed that the women are domiciled in Ogun, Ondo, Lagos and Ibadan which are in the South West geopolitical zone of Nigeria [17]. A history of previous community screening for the disease was elicited with endemicity of filarial disease in the towns of their nativity but no form of treatment for the disease was obtained from the women [3, 16].

Though peripheral blood film was negative for microfilaria in these women making clinical diagnosis difficult. However a negative peripheral blood smear does not preclude the diagnosis of filariasis. This was confirmed in a study conducted by Ogunba [18] in Nigerians infected with loa loa, with up to half of the cases with low peripheral microfilaria levels. Other techniques that may be useful for the diagnosis are tests for antifilarial antibodies/circulating parasitic antigens and polymerase chain reaction (PCR) which is expensive and not frequently performed in Nigeria [15]. No biopsy was performed in the patients.

Fredman and Kalisher [9], reported transmission of filariasis by means of a bite from a mosquito (that has previously bitten an infected host). The mosquito then deposits infective larvae on the skin. The larvae migrate through the puncture wound to reach the subcutaneous vessels where they mature into the adults over a period of 6-months to 2 years. The patient's infection can remain dormant for decades which are likely in these women. The adult worms mate and produce microfilaria which circulates in the blood stream with a periodicity that generally matches the feeding habits of the mosquito vector [14]. The life cycle is completed when the microfilaria are ingested by the mosquito. *W. bancrofti* the predominant variant of the two types is more common in Nigeria. The other variant *B. Malayi* is responsible for infection in parts of Asia [14]. The clinical presentation of the infection is due to lymphatic dysfunction, inflammation and obstruction. Later, this region drained by the local lymphatic system is prone to secondary bacteria and superficial fungal infection resulting in further lymphatic damage the so-called granulomatous *lymphangitis* and may lead to skin changes called elephantiasis [7, 9, 14].

The breast is a recognized though infrequent site of involvement [14]. In the breast, granulomatous lymphangitis develops in the tissue adjacent to the lymphatic vessel [11] and eventually block the vessels which are soon replaced with fibrous tissue [8] and the

patient may present with a palpable breast mass, the filarial granuloma or mass and microcalcifications. In a review of 131 cases of filarial granuloma of the breast [11], it was reported that in most cases, the solitary and superficial filarial nodule was palpable and in more than half the cases the clinical impression was suggestive of a breast tumour, one patient even underwent a simple mastectomy. However, none of these patients presented with a palpable mass rather, their mammograms demonstrated tortuous, ring-like microcalcifications like the report by Chow et al [14]. The above typical mammographic appearance and endemicity of the disease supported the diagnosis of filariasis. Filarial calcifications of the breast can be found anywhere in the breast including the nipple and the retroareolar region [8]. This is reiterated in our patients, where calcifications were found in virtually all the quadrants within the breast parenchyma as well as in the retroareolar region.

However, their mammographic features differ from the nematodal infections caused by *Onchocerca volvulus* (*Onchocerciasis*), *loa loa* and *Trichinella spiralis* (*trichinosis*) [19]. The filarial infection of *O.volvulus* and *Loa loa* are distinguished from the infection of *W.bancrofti* on the basis of the location and appearance of the organisms. While *Wuchereria bancrofti* reside in the breast parenchyma, *onchocerca volvulus* organisms are found in spaces just beneath the skin epithelium and occasionally in lymphatic vessels and lymph nodes where their calcifications form intricate tangles [8]. The calcifications of loiasis differ from those of *W. bancrofti* on the basis of their appearance as either short or long continuous or beaded fine calcifications, when the worm is extended. Loiasis may also appear as hair-like whorls of calcifications. Peculiarly, *Trichinosis* calcifications are located only in the pectoral muscles, they are however much smaller, more numerous and not serpiginous when compared with those of filariasis [20].

Records show that the skin over the parasitic nodule may be hyperaemic with changes of *peau d'orange* and axillary nodal enlargement which may mimic a suspicious breast lesion. However, in a multinational and multicenter study carried out in 1997 in Oyo state -Nigeria, a nodule prevalence rate of 59% was found in the three Ibarapa local government areas in the state, but [21] none of these women had nodules or hyperaemia.

These skin and axillary changes are known features of breast cancer and could lead to a misdiagnosis in our setting where mammographic breast imaging is in its infancy. These suspicious

features are then over treated as reported by Chen [10] more so in a developing country that lacks the full complement of further comprehensive breast work-up with Magnetic Resonance Imaging (MRI), stereotactic biopsy and needle localization.

On the overall, benign dystrophic calcifications common in the breast can also be differentiated from those of parasitic diseases on the bases of their coarse, dense and irregular appearance [8].

Chen and Xie [10] also warned that foci of calcification of worm are frequent presentation rather than the occasional calcifications of the whole and entire worms. These foci of calcifications could simulate suspicious comedo calcifications and could be wrongly treated as a cancer. In this instance, it is recommended that other stigmata of cancer be considered before a final diagnosis is made. Previously, the full worm calcifications were considered intermediate; which led to localization and excision biopsy [14]. Now with increased awareness of the disease, diagnosis is likely to be more accurate as other ancillary investigative tools could be utilized for final diagnosis. Recent advances in breast Imaging has made sonomammography invaluable adjunct in the evaluation of breast disease considering its usefulness in the evaluation of the axilla. There is however a dearth of literature of this imaging tool in the assessment of filarial disease. Evaluation of the breasts with sonography confirmed no definite mass and demonstrated no calcifications, reaffirming the latter's insensitivity in the evaluation of calcifications in breast disease and making mammography [22] the gold standard for screening.

One of the complications of excisional biopsy is the appearance of residual calcifications in follow-up mammograms. The residual micro-calcifications of degenerating and calcifying nematodes may also be confused with malignant calcification [14].

It is therefore important that filarial calcifications are critically assessed, diagnosed accurately and properly categorized to avoid an unnecessary, expensive, invasive procedure like excision biopsy.

Conclusion

This paper illustrates that wormlike calcifications are also visible on mammograms. Radiologists should be aware of the endemic nature of filariasis in the country. As routine mammography becomes available in Nigeria, there is a need for a high level of suspicion for parasitic calcifications in the breast parenchyma in mammographic

images so that the infection will not be misdiagnosed for a malignant breast lesion.

Competing interests

We declare that we have no competing interests.

Authors' contributions

Conception and design: Adenike Temitayo Adeniji-Sofoluwe and Millicent Olubunmi Obajimi. Acquiring the data: Temitope O Soyemi and Adenike Temitayo Adeniji-Sofoluwe. Analysing the data: Adenike Temitayo Adeniji-Sofoluwe. Interpreted the data: Millicent Olubunmi Obajimi, Abideen Olayiwola Oluwasola and Adenike Temitayo Adeniji-Sofoluwe. Millicent Olubunmi Obajimi, Abideen Olayiwola Oluwasola and Adenike Temitayo Adeniji-Sofoluwe drafted the article, revised critically for important intellectual content; and final version to be published.

Acknowledgments

We wish to thank all the residents in the department of Radiology, involved in the retrieval of the mammograms for evaluation; radiographers especially Ada Odita and Mrs. Adepoju as well as the dark room technicians for their contributions.

Tables and figures

Figure 1: Presenting complaints of women

Figure 2: Location of calcifications

Figure 3: Number of parasitic calcifications

Figure 4: Quadrant of Breast Involved

Figure 5: Patterns of parasitic calcifications seen at mammography on an MLO view

Figure 6: Patterns of parasitic calcifications seen at mammography on a CC view

Figure 7: Spot Magnification Mammographic view showing linear, tubular parasitic calcifications

References

1. Anosike JC, Onwuliri COE, Onwuliri VA. Human filariasis in Dass local government area of Bauchi state, Nigeria. *Tropical Ecology*.2003; 44(2): 217-227. **PubMed | Google Scholar**
2. Bradley AK. Effects of Onchocerciasis on settlements in middle Hawal valley, Nigeria. *Transactions of the Royal Society for Tropical Medicine & Hygiene*. 1976;70(3):225-9. **PubMed | Google Scholar**
3. Crosskey RW. A review of *Simulium damnosum* SL and human onchocerciasis in Nigeria with special reference to geographical distribution and the development of Nigerian National Control Campaign. *Tropical Medicine and parasitology*.1981; 32(1): 2-16. **PubMed | Google Scholar**
4. Gemade EI and Dipeolu OO. Onchocerciasis in the Benue State of Nigeria, Prevalence of the disease among the Tivs living in the Kwande local government area. *Annals of Tropical Medicine & Parasitology*.1983;77(5): 513-516. **PubMed | Google Scholar**
5. Edungbola LD, Babata AL, Aliyu RA et al. Leopard skin and onchocerciasis. *Nigerian Journal of Parasitology*.1988-90; 9-11: 77-82. **PubMed | Google Scholar**
6. Ottesen EA. Filarial infections. *Infect Dis Clin North Am*. 1997;7(3):619-633. **PubMed | Google Scholar**
7. Maegraith B G. Adams and Maegraith. *Clinical tropical diseases-9th Edition*. 1989. Boston Massachusetts. Blackwell Science. **PubMed | Google Scholar**
8. Paul D, Friedman DO and Kalisher L. Case 43: Filariasis. *Radiology*. 2002; 222(2):515- 17.. **PubMed | Google Scholar**
9. Chen Y and Xie Q. Filarial granuloma of the female breast, a histo pathologic study of 131 cases. *Am J Trop Med. Hyg*. 1981;30(6):1206-1210. **PubMed | Google Scholar**
10. Figueredo-Silva J P and Dreyer. Bancroftian lymphangitis in North Eastern Brazil: A histopathologic study of 17 cases. *J Trop Med. Hyg*. 1992;95(2):114-118. **PubMed | Google Scholar**
11. Lang AP, Luchsinger IS, Rawling EG. Filariasis of the breast. *Arch Pathol Lab Med*. 1987;111(8):757-759. **PubMed | Google Scholar**
12. Lahiri VL. Microfilariae in nipple secretion. *Acta Cytol*.1975:19: 154-155. **PubMed | Google Scholar**
13. Chow CK, Mc Carthy JS, Neatfie. Mammography of lymphatic filariasis. *AJR. Am J. roent genol* .1996; 167(6):1425-1426. **PubMed | Google Scholar**
14. Lenhart A, Eigege A, Kal A et al .Contributions of different mosquito species to the transmission of lymphatic filariasis in central Nigeria: implications for monitoring infection by PCR in mosquito pools. *Filarial Journal*. 2007; 6:14. **PubMed | Google Scholar**
15. Wyatt GB. Onchocerciasis in Ibarapa, western state, Nigeria. *Annals of Tropical Medicine & Parasitology*. 1971; 65(4):513-523. **PubMed | Google Scholar**
16. Federal Republic of Nigeria Official gazette. 2007;24:B194-195. **Google Scholar**
17. Ogunba EO. Loa loa microfilaraemia in the Nigeria population. *Tropical and Geographical Medicine*.1977; 29(1): 51-55. **PubMed | Google Scholar**
18. Suneja, SK. Olopoenia L, Teal JS et al. Mammographic calcifications due to filarial disease. *Trop Doct*. 1990; 20(3): 143-144. **PubMed | Google Scholar**
19. Ikeda D and Siklis E. Mammographic demonstration of pectoral muscle. Micro calcifications. *Am J Roetgenol*. 1988; 151(3): 475-476. **PubMed | Google Scholar**
20. Brieger WR, Ososanya OO, Kale OO et al. Gender and ethnic differences in onchocercal skin disease in Oyo State, Nigeria.

Tropical Medicine and International Health.1997; 2(6): 529-534. **PubMed | Google Scholar**

21. Tabar L, Gad A, Holmberg LH et al. Reduction in Mortality from breast cancer after mass screening with mammography. The Lancet. 1985; 1(8433):829-832.. **PubMed | Google Scholar**

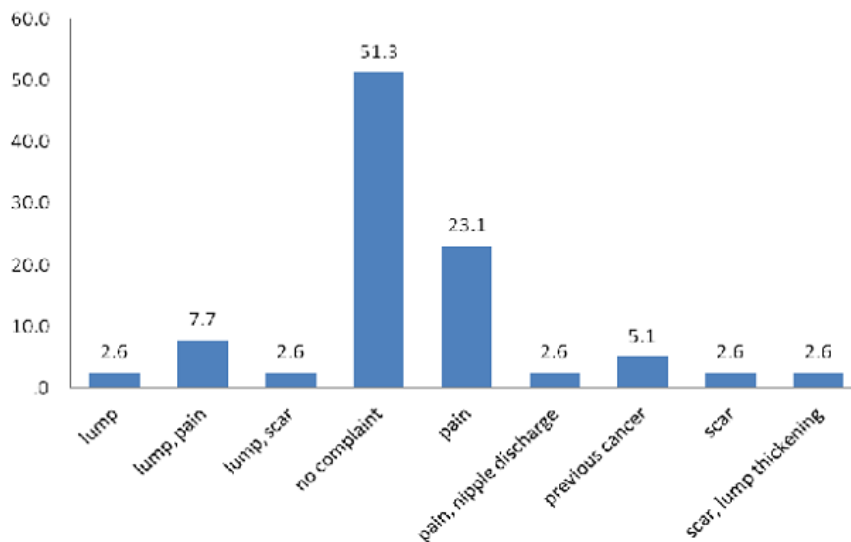


Figure 1: Presenting complaints of women

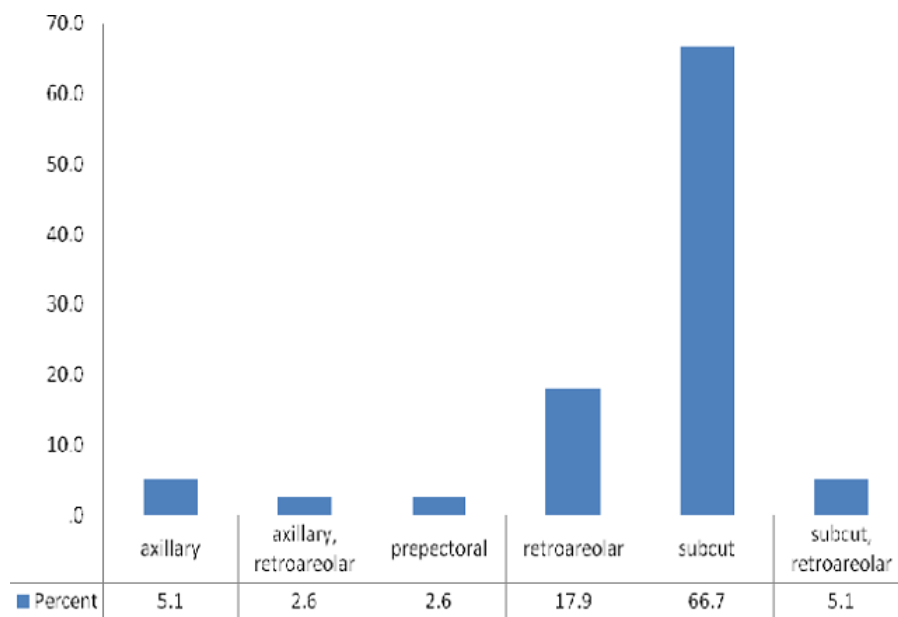


Figure 2: Location of calcifications

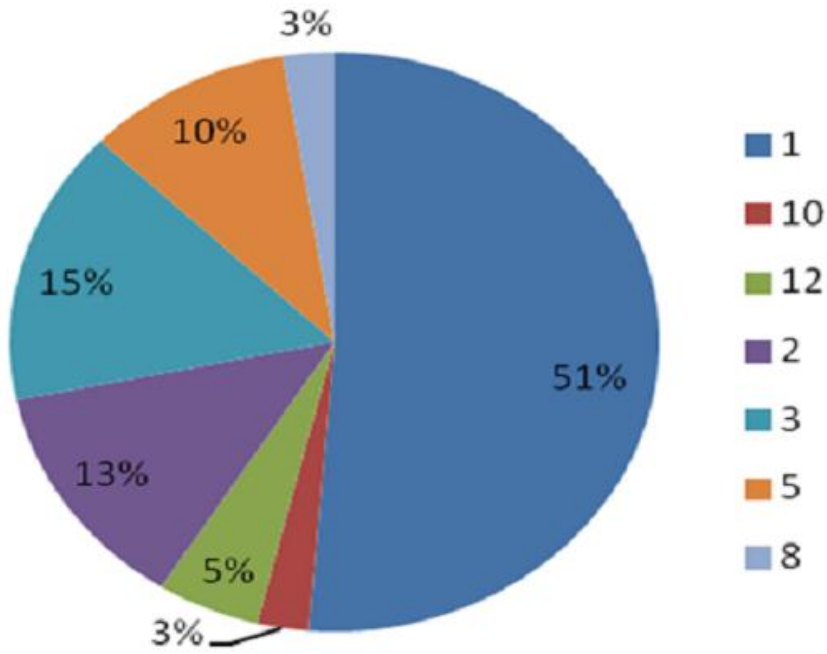


Figure 3: Number of parasitic calcifications

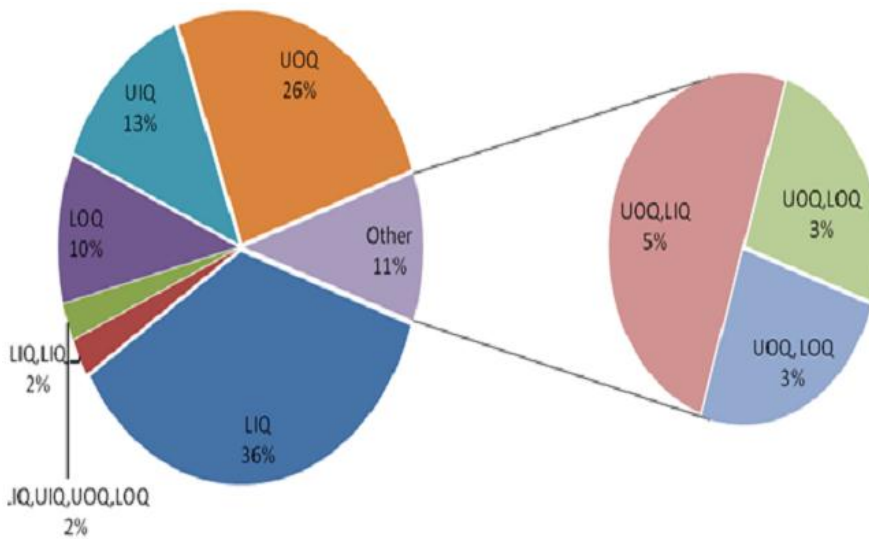


Figure 4: Quadrant of Breast Involved

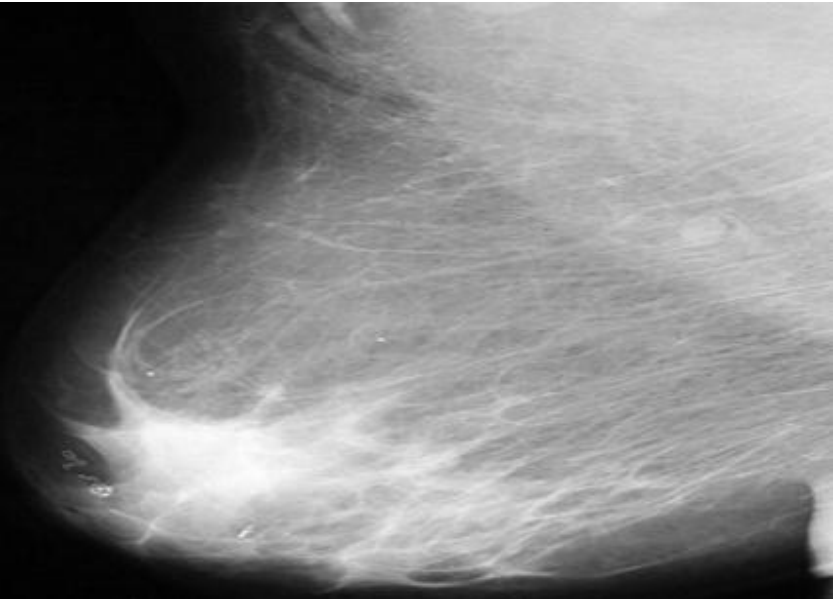


Figure 5: Patterns of parasitic calcifications seen at mammography on an MLO view

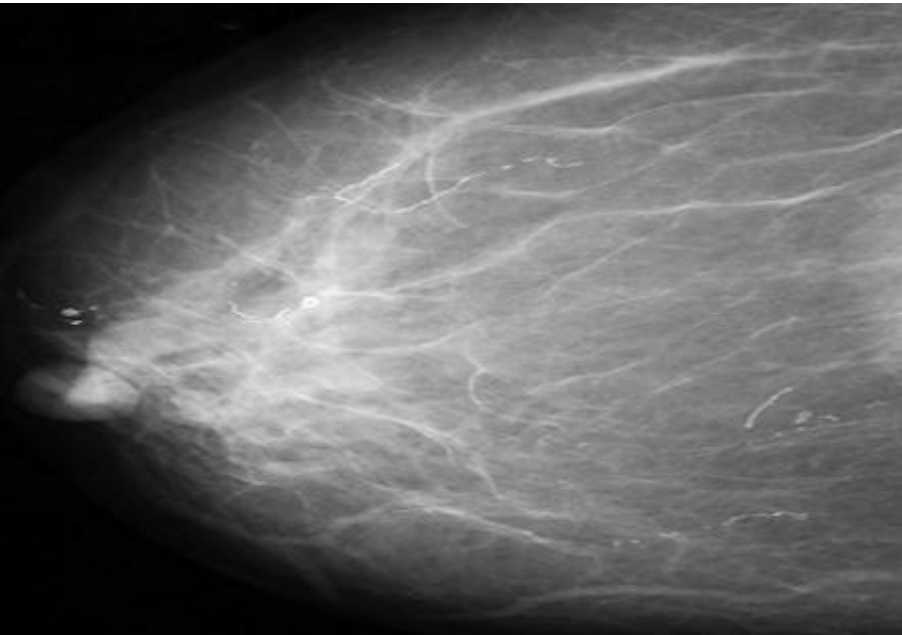


Figure 6: Patterns of parasitic calcifications seen at mammography on a CC view

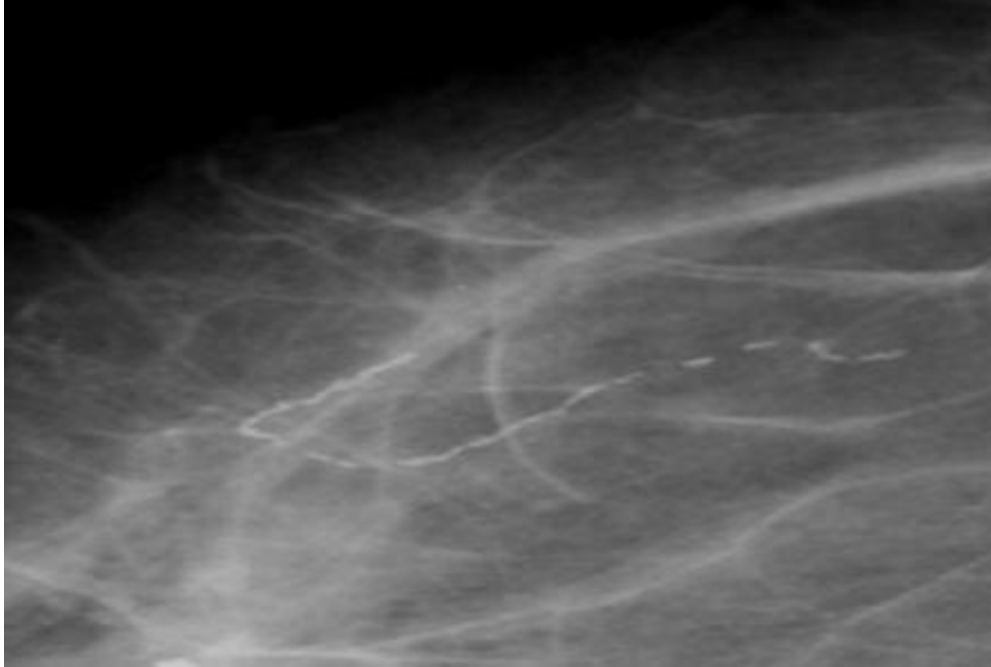


Figure 7: Spot Magnification Mammographic view showing linear, tubular parasitic calcifications