

Submitted: 30/04/2019

Accepted: 14/10/2019

Published: 29/11/2019

## Successful unilateral vasectomy reversal in a lion (*Panthera leo*)

Marcelo Marconi<sup>1\*</sup>, José Manuel de la Torre<sup>2</sup>, Cristian Palma<sup>3</sup>, Hector Gallegos<sup>1</sup>, Evelyn Soto<sup>4</sup>, Sebastián Celis<sup>5</sup>, Camila de la Torre<sup>5</sup>, Carolina Ortiz<sup>5</sup>, Alberto Duarte<sup>5</sup> and Ignacio Idalsoaga<sup>5</sup>

<sup>1</sup>Andrology Unit, Department of Urology, Pontificia Universidad Católica, Santiago, Chile

<sup>2</sup>Department of Urology, El Carmen Hospital, Santiago, Chile

<sup>3</sup>Department of Urology, Clínica Las Condes, Santiago, Chile

<sup>4</sup>Andromed, Santiago, Chile

<sup>5</sup>Department of Veterinary Medicine, Buin Zoo, Buin, Chile

### Abstract

**Background:** In 2016, the veterinarian team of Buin Zoo in Chile decided to try to increase the lion population. At that time, the zoo had three lions; two females and one male. The 9-year-old male had been vasectomized 5 years ago at the same institution for birth control. Considering the fact that in humans, vasectomy reversal has excellent reproductive outcomes, a team of human urologists, highly experienced in vasectomy reversal was contacted to perform the procedure.

**Case description:** Surgery was performed on June 16, 2016 under general anesthesia, with the vasectomy site accessed through the previous scar localized in the lower groin. After opening the skin, dartos and tunica vaginalis, we were able to identify the previous vasectomy site. After liberating both vas ends and checking for permeability, a microsurgical anastomosis (magnification 25×) was performed. The surgery took 80 minutes with minimal bleeding, and no surgical complications were observed. After 2 weeks, the lion joined the lionesses and reproductive follow-up was started. Seven months after surgery, one lioness became pregnant, and 4 months later gave birth to two female lion cubs, with no incidents at the zoo. Both cubs were healthy and are still living at the zoo.

**Conclusion:** Vasectomy reversal constitutes a valid perspective to reassume fertility in previous vasectomized lions.

**Keywords:** Lion, Microsurgery, Vasectomy, Vasectomy reversal.

### Introduction

In humans, vasectomy is the most common male contraceptive method, with more than 500,000 procedures per year in the United States (Machen *et al.*, 2018). This procedure is advantageous as it is a minimally invasive procedure with low complication rates, extremely effective as a contraceptive method, maintains undisturbed the endocrinological function of the testes, and it is potentially reversible. In zoo animals, where reproductive control is occasionally necessary, vasectomy has been reported in different species, i.e., gorillas (*Gorilla gorilla*), chimpanzees (*Pan troglodytes*), Bush dogs (*Speothos venaticus*), and lions (*Panthera leo*) (Robinson *et al.*, 1975; Silber *et al.*, 2013).

Approximately 5% of vasectomized men eventually seek procedures to reach fertility (Dickey *et al.*, 2015). In these patients, the preferred method to restore fertility is vasectomy reversal (Shridharani and Sandlow, 2010), given that the success rate, meaning the presence of motile sperm in the semen analysis after surgery is extremely high (Dickey *et al.*, 2015). The most important factors impacting the success rate of vasectomy reversal are: (1) time elapsed since the original vasectomy was performed, (2) experience of the surgeon, and (3) intraoperative findings, such as the

presence of a sperm granuloma as well as the presence of sperm in the vas fluid (Namekawa *et al.*, 2018). If the vasectomy was performed less than 10 years ago, the success rate for an experienced surgeon is approximately 90%. After 10 years, patency rates tend to decline, but are still extremely high (approximately 80%) (Grober *et al.*, 2014). In animals, vasectomy reversal for fertility has been published in the scientific literature for bush dogs (*S. venaticus*), chimpanzees (*P. troglodytes*), gorillas (*G. gorilla*), Sika deer (*Cervus nippon*), and Przewalski's horse (*Equus przewalski*); however, patency and pregnancy rates are not reported (Silber *et al.*, 2013).

The case reported herein describes the management of a lion (*P. leo*), with a history of vasectomy, after undergoing a successful vasectomy reversal surgery.

### Case Details

A 9-year-old vasectomized male lion was kept at the Buin Zoo (Buin, Chile). The animal was surgically vasectomized 5 years prior for birth control at the same institution. Castration was not elected as a form of birth control in this case, because it is associated with loss of the mane (Pocock, 1930; West and Packer, 2002). Briefly, vasectomy was performed under general anesthesia through two separate low-groin

\*Corresponding Author: Marcelo Marconi. Andrology Unit, Red Salud UC Christus, Cruz del Sur 177, Las Condes, Santiago 7550000, Chile. Email: [mmarconi@andro.cl](mailto:mmarconi@andro.cl)

incisions. The vas deferens was cut off and both ends were ligated, with no complications observed. Due to population management policy changes 5 years later, surgical vasectomy reversal was elected as a method to attempt increasing the lion population. The surgical procedure was approved by the ethical committee of the zoo.

#### **Surgical technique**

The lion had a 12-hour fasting period, with water deprivation for 2 hours before surgery. After using a dart for sedation with ketamine (3 mg/kg) and medetomidine (0.03 mg/kg), the lion was placed in the operation theater. Once anesthesia was achieved, an endotracheal tube (n°18) was placed, and isoflurane (2%) gas was administered throughout all surgical procedures. Adequate measures were taken to minimize pain or discomfort during the surgery and follow-up. Once anesthesia was achieved, the scrotal area was shaved to prevent the confusion of the hair with the fine sutures and needles used in the vas deferens anastomosis (Nylon 9.0). After washing the genital area and applying an antiseptic solution, the surgical field was prepared. The vasectomy site was accessed through the previous scar, localized in the lower groin under the level of the external inguinal ring (Fig. 1). After the cutaneous incision was performed, dartos and tunica vaginalis, the previous vasectomy site was identified; both ends of the vas deferens were scarred, with a gap between them of approximately 2.5 cm (Fig. 2). After dissecting both ends, the tension-free microsurgical anastomosis was performed. The proximal end of the vas (abdominal) was sectioned with a scalpel, while its permeability was checked by injecting saline solution through its lumen, using a 24-gauge branula (Fig. 3). Once proximal permeability was confirmed, the distal end of the vas (testicular) was dissected and after performing a gentle massage of the epididymis, the outflow of a whitish consistency fluid was observed (Fig. 4). This fluid was analyzed in a standard laboratory microscope, revealing the presence of motile sperm. After both ends had proven permeability, the microsurgical phase of the surgery was initiated. Using a vas deferens approximator, both ends were approached, and under magnification of 25× the microsurgical anastomosis was performed (Fig. 5). The needle was passed through the vas lumen, securing all the layers of the vas in a one-layer suture (Fig. 6). After anastomosis was completed, four separated stitches to the outer fascia of the vas in order to increase resistance and support. Using an electrocoagulator, careful hemostasis was performed and the spermatic cord was placed in the scrotum. The dartos and skin were closed with Vycril 1.0 separated stitches. The surgery of the left side took 80 minutes with minimal bleeding. Due to prolonged surgical and anesthetic time, surgery was discontinued; therefore, only the reversal of the left side was performed. For anesthetic reversal, isoflurane

was discontinued and intramuscular atipamezole (75 µg/kg) was administered.

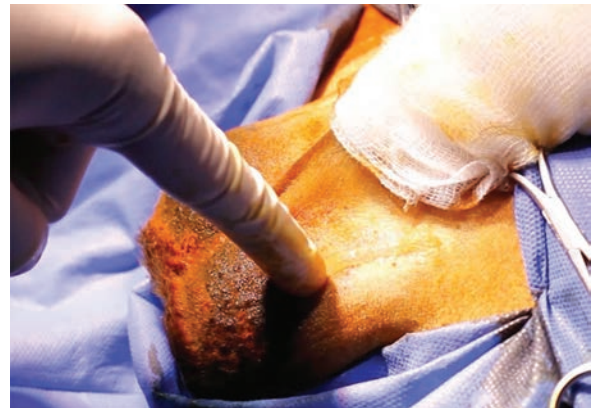
The patient had no surgical complications, and during the follow-up, no problems were detected. After 2 weeks, the lion joined the lionesses (two) and reproductive follow-up was initiated.

#### **Follow-up**

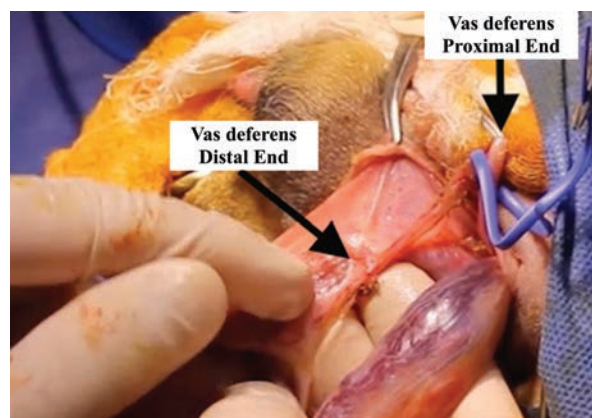
In the following months, the only lion with which the lionesses had contact was our patient. Seven months after surgery, one of these lionesses was noted to be pregnant, and after 4 months, two female lion cubs were born with no incidents at the zoo (Fig. 7). Both cubs were healthy and are currently living at the zoo.

#### **Discussion**

Even though vasectomies are not recommended for management interventions of free-ranging lion populations (Miller *et al.*, 2013), these procedures have been reported in zoo lions since the 70s (Robinson *et al.*, 1975). In captive lions, vasectomy is

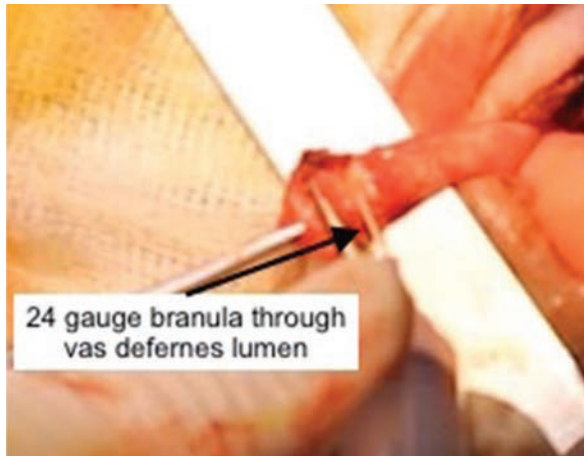

**Fig. 1.** Vasectomy reversal surgery performed in a captive lion (*P. leo*). Vasectomy site was accessed through the previous scar localized in the lower groin under the level of the external inguinal ring.

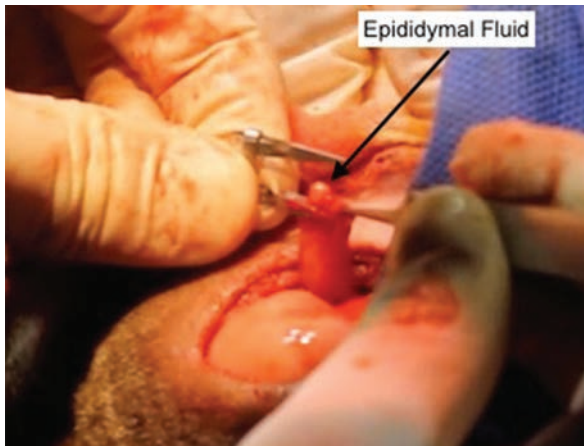


**Fig. 2.** Ends of the vas deferens with a gap between them of approximately 2.5 cm.

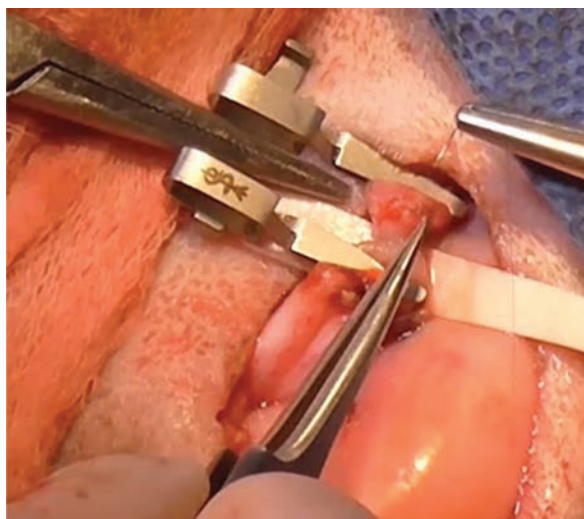





**Fig. 3.** Permeability check using a 24-gauge branula through the vas lumen.



**Fig. 4.** Outflow of whitish consistency fluid from the epididymal end of the vas.



**Fig. 5.** External view of the microsurgical anastomosis.



**Fig. 6.** Microsurgical view (magnification 25×), needle passed through the vas lumen taking all the layers of the vas together in a one-layer suture.



**Fig. 7.** Female lion cubs born after vasectomy reversal.

preferred over physical and chemical castration since the latter is associated with side-effects such as weight gain and loss of the mane (Munson, 2006; West and Packer, 2002).

Data on vasectomy and continued fertility in animals are extremely scarce, although in humans, this subject has been extensively reported and discussed. For previously vasectomized men who desire fertility, two options are available: vasectomy reversal or sperm retrieval plus intracytoplasmic sperm injection (ICSI). In men with less than 10 years of vasectomy and couples younger than 39-years-old, vasectomy reversal constitutes the first option, with high patency and pregnancy rates, as reported in the literature (Gerrard *et al.*, 2007; Grober *et al.*, 2014). In men with more than 10 years since vasectomy and in reproductively older couples (>39-years-old), or partners who are unable to achieve spontaneous pregnancy irrespective of their age (i.e., bilateral tubal obstruction or premature ovarian failure), sperm retrieval associated with ICSI appears to be a competitive alternative to vasectomy reversal (Hinz *et al.*, 2008; Shridharani and Sandlow, 2010). In the first scenario, previous analyses demonstrate that vasectomy reversal is more cost-effective than ICSI to achieve a pregnancy (Pavlovich and Schlegel, 1997).

Based on this evidence, and considering the fact that ICSI was deemed to be more complicated, riskier, and more expensive, vasectomy reversal was considered the first option.

After an extensive literature review of scientific journals and books, we found that vasectomy reversal had not been described in lions; however, it was reported in other zoo animals as previously reported (Silber *et al.*, 2013). In bush dogs, chimpanzees, and gorillas, the animals had an open-ended vasectomy, a technique used in humans to render the procedure more easily reversible. This technique leaves the distal (testicular) end open to allow leakage, decreasing the epididymal intraluminal pressure, which is preferable to epididymal physiology and reversal than complete obstruction. This approach is associated with >90% reversal success in a large series of >4,000 humans (Silber *et al.*, 2013). In Sika deer and Przewalski's horse, and similar to the case reported herein, a traditional non open-ended vasectomy was performed, which slightly decreases its success; however, reversal success remains over 80% in humans with this type of vasectomy, so with experienced surgeons to revert both vasectomies techniques, we followed the initial surgical plan.

As such, we used the scar as a guide to search for the vasectomy site, which was an excellent surgical approach. The anatomical structures were similar to those in humans; yet, we noticed that the vas deferens was smaller by approximately 20%, making the microsurgical anastomosis technically more difficult, and explaining why the surgical time was greater than the mean time to perform one side in humans (approximately 45 minutes). With the assistance of only surgical loupes, and a mean magnification of 2.5 to 6.0×, we suspect that anastomosis would have been extremely difficult or almost impossible. We recommend the use of a surgical microscope (magnification 20 to 25×), as it is done with humans.

Although only one side could be reversed due to prolonged surgical time, the procedure was extremely successful for two reasons: first, motile sperm were observed in the vassal fluid, and second, during the microsurgical phase of surgery, we could see the epididymal fluid flow through the vas while performing the anastomosis.

In humans, surgical success is determined by the presence of motile sperm in semen analyses during follow-up (Namekawa *et al.*, 2018). In our case, patency could be demonstrated with a semen analysis by electroejaculation, requiring general anesthesia, or by the lion's attempt to copulate with an artificial vagina. None of these options were available, therefore, allowing spontaneous pregnancy and monitoring was elected. Since the females had no other contact with males, besides our patient, pregnancy would corroborate a successful vasectomy reversal.

In conclusion, vasectomy reversal constitutes a valid technique to resume fertility in previous vasectomized lions. As with humans, surgery should be performed by experienced microsurgeons, with the assistance of a surgical microscope and microsurgical instruments.

#### Acknowledgments

The authors would like to acknowledge the expert assistance of the veterinary technicians of Buin Zoo during the surgical procedure and follow-up.

#### Conflict of interest

The authors declare that there is no conflict of interest.

#### Author contribution

Marcelo Marconi and José Manuel de la Torre were contacted to perform surgery. Cristian Palma assisted in the surgery. Hector Gallegos and Evelyn Soto assisted in the draft of the manuscript and photo edition. Sebastián Celis, Camila de la Torre, Carolina Ortiz, Alberto Duarte, and Ignacio Idalsoaga assisted in all the surgical procedures and follow-up of the lion and cubs.

#### References

- Dickey, R.M., Pastuszak, A.W., Hakky, T.S., Chandrashekar, A., Ramasamy, R. and Lipshultz, L.I. 2015. The evolution of vasectomy reversal. *Curr. Urol. Rep.* 16, 40.
- Gerrard, E.R., Sandlow, J.I., Oster, R.A., Burns, J.R., Box, L.C. and Kolettis, P.N. 2007. Effect of female partner age on pregnancy rates after vasectomy reversal. *Fertil. Steril.* 87, 1340–1344.
- Grober, E.D., Karpman, E. and Fanipour, M. 2014. Vasectomy reversal outcomes among patients with vasal obstructive intervals greater than 10 years. *Urology* 83, 320–323.
- Hinz, S., Rais-Bahrami, S., Kempkensteffen, C., Weiske, W.H., Schrader, M. and Magheli, A. 2008. Fertility rates following vasectomy reversal: importance of age of the female partner. *Urol. Int.* 81, 416–420.
- Machen, G.L., Bird, E.T., Kavoussi, P.K. 2018. Analysis of urban versus rural vasectomy demographics: a multi-institutional, retrospective comparison. *Transl. Androl. Urol.* 7, 931–934.
- Miller, S.M., Bissett, A., Burger, A., Courtenay, B., Dickerson, T., Druce, D.J. and Zimmermann, D. 2013. Management of reintroduced lions in small, fenced reserves in South Africa: an assessment and guidelines. *South Afr. J. Wildl. Res.* 43, 138–154.
- Munson, L. 2006. Contraception in felids. *Theriogenology.* 66, 126–134.
- Namekawa, T., Imamoto, T., Kato, M., Komiya, A. and Ichikawa, T. 2018. Vasovasostomy and vasoepididymostomy: review of the procedures, outcomes, and predictors of patency and pregnancy over the last decade. *Reprod. Med. Biol.* 22, 343–355.

- Pavlovich, C.P. and Schlegel, P.N. 1997. Fertility options after vasectomy: a cost-effectiveness analysis. *Fertil. Steril.* 67, 133–141.
- Pocock, R.I. 1930. The Lions of Asia. *J. Bombay Nat. His. Soc.* 34, 638–665.
- Robinson, P., Sedgewick, C. and Lochner, F. 1975. Vasectomy: solution to the overpopulation problema in captive African lions? *Vet. Med. Small Anim. Clin.* 70, 1356–1356.
- Shridharani, A. and Sandlow, J.I. 2010. Vasectomy reversal versus IVF with sperm retrieval: which is better? *Curr. Opin. Urol.* 20, 503–509.
- Silber, S.J., Barbey, N., Lenahan, K. and Silber, D.Z. 2013. Applying clinically proven human techniques for contraception and fertility to endangered species and zoo animals: a review. *J. Zoo Wildl. Med.* 44, 111–122.
- West, P. and Packer, C. 2002. Sexual selection, temperature, and the Lion's Mane. *Science.* 297, 1339.