

Submitted: 24/07/2018

Accepted: 10/03/2019

Published: 25/03/2019

Adjuvant electrochemotherapy with bleomycin and cisplatin combination for canine soft tissue sarcomas: A study of 30 cases

Enrico P. Spugnini^{1,*}, Bruno Vincenzi², Bruno Amadio³ and Alfonso Baldi^{4,5}

¹Biopulse srl, Naples, Italy

²Medical Oncology Department, University Campus Bio-Medico of Rome, Rome, Italy

³SAFU service, Regina Elena Cancer Institute, Rome, Italy

⁴Department of Environmental, Biological and Pharmaceutical Sciences and Technologies Campania University "Luigi Vanvitelli", Caserta, Italy

⁵Institute of Biosciences and BioResources, CNR, Naples, Italy

Abstract

Electrochemotherapy (ECT) couples the administration of anticancer drugs with the delivery of electric pulses that increase the drug uptake through the cell membranes, thus resulting in an improved efficacy. This study has evaluated the tolerability and efficacy of the combination of systemic bleomycin and local cisplatin as ECT agents for incompletely excised canine soft tissue sarcoma (STS). Thirty dogs with incompletely excised STSs were enrolled. The dogs received intravenous 20 mg/m² bleomycin, and the tumor bed and margins were infiltrated with cisplatin at the dose of 0.5 mg/cm². Then, trains of permeabilizing biphasic electric pulses were applied under sedation. More precisely, 5 min after the injection of the chemotherapy agents, sequences of eight biphasic pulses lasting 50 + 50 µsec each, were delivered in bursts of 1,300 V/cm using caliper electrodes. A second session was performed 2 wk later. The treatment was well tolerated and side effects were minimal. Twenty-six dogs had no evidence of recurrence at the time of manuscript writing; four had recurrence and one of the four recurring dogs died of lung metastases. Median estimated disease free was 857 d. Perivascular wall tumors response was compared to that of the other STSs, but the difference in outcome was not significant. ECT using combination of bleomycin and cisplatin appears to be effective in the treatment of incompletely resected STSs in dogs. This therapeutic approach could be a useful addition to the current options in consideration of its low cost, limited toxicity, and ease of administration.

Keywords: Bleomycin, Cisplatin, Dog, Electrochemotherapy, Sarcoma.

Introduction

Soft tissue sarcomas (STSs) are an assorted pool of solid tumors categorized together due to their clinical and histopathological features (Ehrhart, 2005; Bray *et al.*, 2014). STSs represent approximately 15% of all canine skin cancers, with a yearly incidence of 35 cases per 100,000 patients at risk (Liptak and Forrest, 2013). These tumors usually present as soft or firm masses with poorly defined margins and frequent infiltration of the neighboring tissues (Dernell *et al.*, 1998). Therefore, conservative surgery is unable to achieve a complete eradication of the tumor, thus frequently resulting in recurrence (Mayer and LaRue, 2005). Some prognostic factors for recurrence have been identified, such as incompleteness of resection versus radical excision (Chase *et al.*, 2009), or tumor grade (Bray *et al.*, 2014). Hematological dissemination is a common event, being observed in up to 20% of cases (Liptak and Forrest, 2013). Response to chemotherapy and radiation therapy is mostly limited to neoplasms smaller than 5 cm in diameter (Liptak and Forrest, 2013). The most commonly adopted strategies aimed at increasing local control involved the combination

of surgery with adjuvant therapies, such as radiation therapy (Forrest *et al.*, 2000; McKnight *et al.*, 2000), sometimes associated with hyperthermia (Thrall *et al.*, 2005), adjuvant chemotherapy (Selting *et al.*, 2005), and electrochemotherapy (ECT) (Spugnini *et al.*, 2007a, 2008a, 2011). ECT is an anticancer therapy that couples the administration of chemotherapy agents with the delivery of trains of permeabilizing electric pulses having an appropriate waveform (Spugnini *et al.*, 2014, 2016, 2017). These pulses induce transient perturbation and rearrangement of the cell membrane, resulting in increased cross-flow of material through the cytoplasmic membrane, including low permeant molecules, such as bleomycin and cisplatin (Silve and Mir, 2011). Direct electrical destruction of cells is a negligible effect, caused by the inability of some cells to sequester calcium within the sarcoplasmic reticulum (Silve and Mir, 2011). The improved chemotherapy uptake by cancer cells induces tumor apoptotic death (Silve and Mir, 2011). Local cisplatin has been used to increase local control with good results, especially for grade I and II STS (Bergman *et al.*, 2016). Nevertheless, since the first ECT studies, it has been shown that

*Corresponding Author: Enrico P. Spugnini. Biopulse srl, Naples, Italy. Email: info@enicospugnini.net

electroporation greatly increases the efficacy of cisplatin, compared to controls treated with cisplatin alone (Sersa *et al.*, 1998; Tozon *et al.*, 2001). Several studies have been investigating ECT for the treatment of STS in pets showing that it was a useful addition to surgery (Spugnini *et al.*, 2007b, 2008a, 2011). In this study, we evaluated the tolerability and effectiveness of a combined ECT protocol involving local and systemic administration of chemotherapy agents (cisplatin and bleomycin, respectively) in dogs carrying incompletely excised STS.

Materials and Methods

Thirty-three dogs with histopathologically confirmed, incompletely excised sarcomas were referred for adjuvant ECT. A patient present with a large grade II peripheral nerve sheath tumor of the left foreleg was shown in Figure 1A. Patients, staged according to the World Health Organization (WHO) grading system, were treated if they fulfilled the following criteria: i) accessibility of the neoplasm location; ii) absence of distant metastases; iii) absence of other life-threatening diseases such as cardiac disease and renal failure; and iv) absence of bone involvement. Patients were staged through the measurement of the surgical field, histopathological exam of tumor, regional lymph node fine-needle aspiration biopsy (when feasible), complete blood cell count, chemistry profile, urinalysis, chest radiographs, and abdominal ultrasonography. Canine patients received two sessions of ECT 2 weeks apart, starting at the time of suture removal (10–14 d after surgery). Dogs were pre-medicated with acepromazine, butorphanol, and medetomidine, followed by propofol to effect. Bleomycin was intravenously injected as a bolus at the dose of 20 mg/m². Moreover, aiming at improving local control, the tumor bed (a surface of two centimeters deep under the surgical scar, or in case of leg location, as deep as feasible and two additional centimeters of margins at each side), was infiltrated with cisplatin at the dose of 0.5 mg/cm². Five minutes after the chemotherapy injections, sequences of eight biphasic pulses lasting 50 + 50 μsec each, were delivered in bursts of 1,300 V/cm using caliper electrodes until the treatment coverage was achieved as elsewhere described (Spugnini *et al.*, 2011). An application of plate electrodes on the tumor bed of a patient is shown in Figure 1B. Pulses were generated using an electroporator certified for veterinary use (Onkodisruptor®) (. 1C). Contact between the patients and the electrodes was optimized using an electroconductive gel. The treatment was repeated after 2 weeks. During the ECT sessions, the patients were monitored using a cardiac monitor and pulse oximeter.

Results

Thirty-three patients were referred for adjuvant treatment over a period of 4 yr. Three dogs were lost to follow-up, leaving 30 patients for statistical

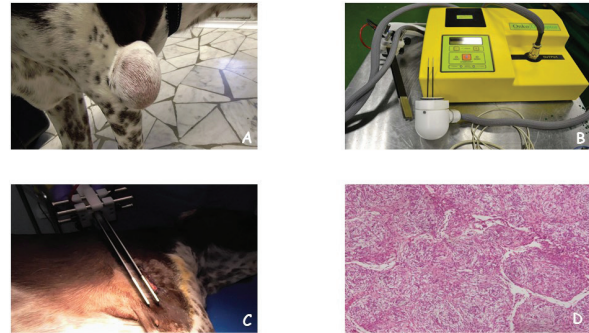


Fig. 1. (A) A dog with a large grade II peripheral nerve sheath tumor of the left foreleg at the presentation. (B) Permeabilizing electric pulses are administered using plate electrodes. (C) The electroporator used for the therapies. (D) The histopathology of the tumor showing the typical alternating Antoni A and B areas (Hematoxylin and Eosin; original magnification ×10).

analysis. Specifically, the remaining dogs belonged to the following breeds: 20 mixed breed dogs, one Rottweiler, one Beagle, one dobermann, one bulldog, one hunting dog, one German shepherd, two dachshunds, and two Abruzzese shepherd. Age varied from 3 to 14 yr with a median of 10 yr. Tumor histotypes were the following: nine perivascular wall tumors, six peripheral nerve sheath tumors, six fibrosarcomas, three chondrosarcomas, two hemangiosarcomas, two liposarcomas, and two undifferentiated sarcomas. The histological features of a peripheral nerve sheath tumor are depicted in Figure 1D. Patients characteristics including histological grade and site of the tumour are summarized in Table 1. The treatment was well tolerated and side effects were confined to local inflammation in three dogs that were controlled through the administration of an anti-inflammatory drug (firocoxib as per manufacturer's instructions). Systemic side effects were not identified. In terms of response, twenty-six dogs (86.6%) had no evidence of recurrence at different times (Table 1), four had recurrence, and one of the four recurring dogs (affected by hemangiosarcoma) died of lung metastases (Table 1). Two of the twenty-six responders died of unrelated causes at different times. Median disease free was not reached at the time of writing: the Kaplan–Meier estimated disease free of 857 d for all the canine population (Fig. 2A). In the attempt to identify prognostic factors, a comparison between the larger cohort of tumors (perivascular wall tumors) versus all the other tumor histotypes was performed since they are also considered the best responders to therapy (Stefanello *et al.*, 2008; Avallone *et al.*, 2014). Again, median disease free was not reached and the calculated estimated disease free values were: 1,162 d versus 992, respectively ($p = 0.222$) (Fig. 2B).

Table 1. Patients' characteristics and outcome.

Age (Years)	Tumor site	T stage	Histotype	Disease free*	Outcome
8 1/2	Left foreleg	T3	PWT Grade II	483	NED
13	Right foreleg	T3	U-SA	93	Recurrence, euthanasia
2 1/2	Right hindleg	T2	HSA	1053	NED
9	Head	T3	PNST Grade II	1505	NED
8	Thorax	T3	FSA Grade II	1249	NED
9	Right foreleg	T2	PWT Grade I	1298	NED
10	Left foreleg	T2	PWT Grade II	1235	NED
3	Right foreleg	T3	U-SA	366	Recurrence, amputation
4	Abdomen	T3	CSA	856	Dead, renal failure
10	Lumbar	T3	PWT Grade II	840	NED
10 1/2	Head	T2	HSA	366	Recurrence,metastasis
10	Right hindleg	T3	LipoSA	443	Recurrence, amputation
8	Left hindleg	T3	PWT Grade II	692	NED
6	Right foreleg	T2	PWT Grade II	660	NED
14	Thorax	T3	PNST Grade II	413	Dead, cardiac disease
4	Flank	T3	LipoSA	604	NED
6	Flank	T3	FSA Grade II	574	NED
13 1/2	Head	T2	CSA	513	NED
10	Left hindleg	T2	PWT Grade II	370	NED
13	Perineum	T2	FSA Grade II	370	NED
7	Perineum	T3	FSA Grade II	338	NED
8	Flank	T3	CSA	286	NED
10	Right foreleg	T3	PNST Grade III	283	NED
11	Left foreleg	T2	PNST Grade II	269	NED
10	Abdomen	T3	PNST Grade II	584	NED
3	Flank	T3	FSA Grade II	212	NED
6	Right foreleg	T2	PWT Grade II	209	NED
5	Left foreleg	T2	FSA Grade II	209	NED
8	Right foreleg	T2	PWT Grade II	205	NED
8	Flank	T3	PNST Grade II	149	NED

(PWT): perivascular wall tumor; (U-SA): undifferentiated sarcoma; (HSA): hemangiosarcoma; (PNST): peripheral nerve sheat tumor; (FSA): fibrosarcoma; (CSA): chondrosarcoma; (LipoSA): liposarcoma; (NED): no evidence of disease; (*): Days.

Discussion

Our results provide valuable insight into long-term outcome of dogs with STS treated with combination adjuvant ECT. In STS surgery, clean resection margins remain the gold standard, with several studies claiming increased overall and disease-free survival times with wider surgical margins (Kuntz *et al.*, 1997; Dernell *et al.*, 1998; Ehrhart, 2005). General orientation for canine STSs calls for en-block resection with 2–3 cm of lateral margins, and the inclusion of one fascial plane deep to the tumor bed (Chase *et al.*, 2009; Bray *et al.*, 2014; Hohenhaus *et al.*, 2016). However, this optimal surgical procedure is rarely accomplished with most

canine sarcomas still being marginally excised (Kuntz *et al.*, 1997; Dernell *et al.*, 1998; Ehrhart, 2005; Bray *et al.*, 2014). Recent clinical evidence suggests that increasing the extension of surgical excision is not enough to improve the treatment success for all STSs (Bray *et al.*, 2014). Moreover, beside the aggressiveness of surgical technique, other factors play a pivotal role in STSs control, including size, histotype, and histologic grade (McSporran, 2009; Bray *et al.*, 2014). Other management options include a combination of surgery plus radiotherapy and chemotherapy (Forrest *et al.*, 2000; McKnight *et al.*, 2000; Simon *et al.*, 2007; Demetriou *et al.*, 2012). Radiotherapy is currently the elective adjuvant treatment for

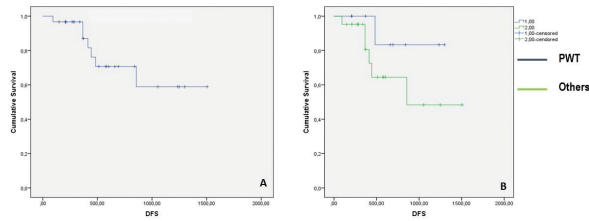


Fig. 2. (A) Kaplan–Meyer curve showing the time to recurrence for 30 dogs with STS treated with adjuvant ECT. (B) Kaplan–Meyer curve showing the time to recurrence for dogs with peripheral wall tumors versus other sarcomas.

incompletely excised solid tumors. However, it has some limitations: 1) availability of a radiation facility, 2) cost of the treatment, and 3) possibility of serious but non-life-threatening local complications such as wound dehiscence, self-trauma, and osteonecrosis of underlying bone (Demetriou *et al.*, 2012). ECT is an anticancer therapy that associates the systemic and/or local administration of chemotherapy agents with the delivery of permeabilizing electric pulses with specific amplitude, duration, and waveforms (Spugnini *et al.*, 2016, 2017). This strategy is helpful to increase the efficacy of lipophobic drugs that often have a narrow therapeutic index, thus minimizing patient toxicoses while maintaining adequate anticancer efficacy (Spugnini *et al.*, 2014). ECT has been described as a useful adjuvant therapy for the treatment of both feline and canine STSs [Reviewed in Spugnini *et al.* (2016)]. Regarding its application in STSs, ECT is almost exclusively used in an adjuvant modality since these neoplasms show a limited response to ECT alone (Spugnini *et al.*, 2016). Consequently, ECT has been adopted as an adjuvant therapy after surgical excision of STSs in several canine and feline studies (Spugnini *et al.*, 2007b, 2008a, 2011). In these studies, the chemotherapy agent (either bleomycin or cisplatin) was injected in the tumor bed. All these studies evidenced a clear clinical gain in terms of local control. In all these adjuvant studies, side effects were limited to local inflammation and occasional wound dehiscence, with the exception of a previously radiated cat that experienced a radiation recall (Spugnini *et al.*, 2007a, 2008b, 2009, 2011). This is the first report of a combined ECT approach in veterinary medicine with cisplatin and bleomycin. Systemic bleomycin administration increased the likelihoods of drug distribution in the deeper layers of the tumor bed, while the local injection of cisplatin was aimed at increasing ECT efficacy in the superficial layers. Our results show that this combination can improve the control of aggressive STS with limited side effects, even better than our previous published canine protocol. In terms of response, we have 86.6% of the treated subjects, still in remission at the time of writing compared to 50% of the previous study (Spugnini *et al.*, 2007a).

Furthermore, the estimated disease free interval in the current study is 859 d (median time not reached), while it was of 730 d in the previous study (Spugnini *et al.*, 2007a). Moreover, we observed a greater disease-free interval for perivascular wall tumors compared to other STSs although this phenomenon was not statistically significant. Generally speaking, perivascular wall tumors are less prone to recurrence than other histotypes, especially if they are located in the extremities (Stefanello *et al.*, 2011). In particular, it has been underlined that for those neoplasms, size, grade (>I), and location of the tumor were significant prognostic factors, while status of margins had only a clinically relevant hazard ratio (Stefanello *et al.*, 2011). In our patients cohort, the tumors we treated were mostly grade II or higher and had also a considerable size (T2 or T3) although most of the perivascular wall tumors (PWTs) were located in the extremities. This supports the increased local control obtained with ECT in our patients. Surgery remains the cornerstone for the treatment of STSs, being most of the time able to achieve local control by itself, especially for certain types such as the PWTs (Stefanello *et al.*, 2008, 2011; Bray *et al.*, 2014). In case of incomplete excision for tumors that are likely to recur, adjuvant therapies are advocated, and among them, ECT displays a reasonable ratio between cost and benefits, as also shown by the current literature (Spugnini *et al.*, 2007a, 2011). In the future studies, we plan to increase the number of cases treated with this combination protocol and to expand the tumor histotypes analyzed, in order to confirm the data presented and to identify subgroups that are more responsive. In conclusion, our data suggest that ECT can be considered an additional adjuvant therapy to increase local control of canine STS. We propose to consider it an effective addition to the current anticancer strategies for STS in veterinary medicine.

Acknowledgments

Partially presented at the ACVIM Forum 2018, June 14–16, Seattle USA. Enrico P. Spugnini and Alfonso Baldi are stockholders of Biopulse S.r.l.

References

- Avallone, G., Boracchi, P., Stefanello, D., Ferrari, R., Rebughini, A. and Roccabianca, P. 2014. Canine perivascular wall tumors: high prognostic impact of site, depth, and completeness of margins. *Vet. Pathol.* 51, 713–721.
- Bergman, N.S., Urie, B.K., Pardo, A.D. and Newman, R.G. 2016. Evaluation of local toxic effects and outcomes for dogs undergoing marginal tumor excision with intralesional cisplatin-impregnated bead placement for treatment of soft tissue sarcomas: 62 cases (2009–2012). *J. Am. Vet. Med. Assoc.* 248, 1148–1156.

- Bray, J.P., Polton, G.A., McSporran, K.D., Bridges, J. and Whitbread, T.M. 2014. Canine soft tissue sarcoma managed in first opinion practice: outcome in 350 cases. *Vet. Surg.* 43, 74–82.
- Chase, D., Bray, J., Ide, A. and Polton G. 2009. Outcome following removal of canine spindle cell tumours in first opinion practice: 104 cases. *J. Small Anim. Pract.* 50, 568–574.
- Demetriou, J.L., Brearley, M.J., Constantino-Casas, F., Addington, C. and Dobson J. 2012. Intentional marginal excision of canine limb soft tissue sarcomas followed by radiotherapy. *J. Small Anim. Pract.* 53, 174–181.
- Dernell, W.S., Withrow, S.J., Kuntz, C.A. and Powers, B.E. 1998. Principles of treatment for soft tissue sarcoma. *Clin. Tech. Small Anim. Pract.* 13, 59–64
- Ehrhart, N. 2005. Soft-tissue sarcomas in dogs: a review. *J. Am. Anim. Hosp. Assoc.* 41, 241–246.
- Forrest, L.J., Chun, R., Adams, W.M., Cooley, A.J. and Vail DM. 2000. Postoperative radiotherapy for canine soft tissue sarcoma. *J. Vet. Intern. Med.* 14, 578–582.
- Hohenhaus, A.E., Kelsey, J.L., Haddad, J., Barber, L., Palmisano, M., Farrelly, J. and Soucy, A. 2016. Canine cutaneous and subcutaneous soft tissue sarcoma: an evidence-based review of case management. *J. Am. Anim. Hosp. Assoc.* 52, 77–89.
- Kuntz, C.A., Dernell, W.S., Powers, B.E., Devitt, C., Straw, R.C. and Withrow, S.J. 1997. Prognostic factors for surgical treatment of soft-tissue sarcomas in dogs: 75 cases (1986–1996). *J. Am. Vet. Med. Assoc.* 211, 1147–1151.
- Liptak, J.M. and Forrest, L.J. 2013. Soft tissue sarcomas. In *Small animal clinical oncology*, 4th ed. Eds., Withrow, S.J., Vail, D.M. and Page, R.L., Elsevier, St Louis, Missouri, USA, pp: 356–380.
- Mayer, M.N. and LaRue, S.M. 2005. Soft tissue sarcomas in dogs. *Can. Vet. J.* 46, 1048–1052.
- McKnight, J.A., Mauldin, G.N., McEntee, M.C., Meleo, K.A. and Patnaik, A.K. 2000. Radiation therapy for incompletely resected soft tissue sarcomas in dogs. *J. Am. Vet. Med. Assoc.* 217, 205–210.
- McSporran, K.D. 2009. Histologic grade predicts recurrence for marginally excised canine subcutaneous soft tissue sarcomas. *Vet. Pathol.* 46, 928–933.
- Selting, K.A., Powers, B.E., Thompson, L.J., Mittleman, E., Tyler, J.V., Lafferty, M.H. and Withrow, S. 2005. Outcome of dogs with high-grade soft tissue sarcomas treated with and without adjuvant doxorubicin chemotherapy: 39 cases (1996–2004). *J. Am. Vet. Med. Assoc.* 227, 1442–1448.
- Sersa, G., Stabuc, B., Cemazar, M., Jancar, B., Miklavcic, D. and Rudolf, Z. 1998. Electrochemotherapy with cisplatin: potentiation of local cisplatin antitumour effectiveness by application of electric pulses in cancer patients. *Eur. J. Cancer* 34, 1213–1218.
- Silve, A. and Mir, L.M. 2011. Cell electropermeabilization and cellular uptake of small molecules: the electrochemotherapy concept. In *Clinical aspects of electroperoration*, 1st ed. Eds., Kee, S.T., Gehl, J., Lee, E.W., Springer, New York, NY, USA, pp: 69–82.
- Simon, D., Ruslander, D.M., Rassnick, K.M., Wood, C.A., Frimberger, A.E., Cotter, S.M., King, N.W. and Moore, A.S. 2007. Orthovoltage radiation and weekly low dose of doxorubicin for the treatment of incompletely excised soft-tissue sarcomas in 39 dogs. *Vet. Rec.* 160, 321–326.
- Spugnini, E.P., Vincenzi, B., Citro, G., Santini, D., Dotsinsky, I., Mudrov, N., Montesarchio, V., Laieta, M.T., Esposito, V. and Baldi, A. 2007a. Adjuvant electrochemotherapy for the treatment of incompletely excised spontaneous canine sarcomas. *In Vivo* 21, 819–822.
- Spugnini, E.P., Baldi, A., Vincenzi, B., Bongiorno, F., Bellelli, C., Citro, G. and Porrello, A. 2007b. Intraoperative versus postoperative electrochemotherapy in high grade soft tissue sarcomas: a preliminary study in a spontaneous feline model. *Cancer Chemother. Pharmacol.* 59, 375–381.
- Spugnini, E.P., Vincenzi, B., Betti, G., Cordahi, F., Dotsinsky, I., Mudrov, N., Citro, G. and Baldi, A. 2008a. Surgery and electrochemotherapy of a high-grade soft tissue sarcoma in a dog. *Vet. Rec.* 162, 186–188.
- Spugnini, E.P., Dotsinsky, I., Mudrov, N., Citro, G., Caruso, G., Cardelli, P. and Baldi, A. 2008b. Electrochemotherapy-induced radiation recall in a cat. *In Vivo* 22, 751–753.
- Spugnini, E.P., Renaud, S.M., Buglioni, S., Carocci, F., Dragonetti, E., Murace, R., Cardelli, P., Vincenzi, B., Baldi, A. and Citro, G. 2011. Electrochemotherapy with cisplatin enhances local control after surgical ablation of fibrosarcoma in cats: an approach to improve the therapeutic index of highly toxic chemotherapy drugs. *J. Transl. Med.* 9, 152.
- Spugnini, E.P., Melillo, A., Quagliuolo, L., Boccellino, M., Vincenzi, B., Pasquali, P. and Baldi, A. 2014. Definition of novel electrochemotherapy parameters and validation of their in vitro and in vivo effectiveness. *J. Cell Physiol.* 22, 1177–1181.
- Spugnini, E.P., Azzarito, T., Fais, S., Fanciulli, M. and Baldi, A. 2016. Electrochemotherapy as first line cancer treatment: experiences from veterinary medicine in developing novel protocols. *Curr. Cancer Drug Targets* 16, 43–52.
- Spugnini, E.P., Fais, S., Azzarito, T. and Baldi, A. 2017. Novel instruments for the implementation of electrochemotherapy protocols: from bench side to veterinary clinic. *J. Cell Physiol.* 232, 490–495.

- Stefanello, D., Morello, E., Roccabianca, P., Iussich, S., Nassuato, C., Martano, M., Squassino, C., Avallone, G., Romussi, S. and Buracco, P. 2008. Marginal excision of low-grade spindle cell sarcoma of canine extremities: 35 dogs (1996–2006). *Vet. Surg.* 37, 461–465.
- Stefanello, D., Avallone, G., Ferrari, R., Roccabianca, P. and Boracchi, P. 2011. Canine cutaneous perivascular wall tumors at first presentation: clinical behavior and prognostic factors in 55 cases. *J. Vet. Intern. Med.* 25, 1398–1405.
- Thrall, D.E., LaRue, S.M., Daohai, Y., Samulski, T., Sander, L., Case, B., Rosner, G., Azuma, C., Poulson, J., Pruitt, A.F., Stanley, W., Hauck, M.L., Williams, L., Hess, P. and Dewhirst, M.W. 2005. Thermal dose is related to duration of local control in canine sarcomas treated with thermoradiotherapy. *Clin. Cancer Res.* 11, 5206–5214.
- Tozon, N., Sersa, G. and Cemazar, M. 2001. Electrochemotherapy: potentiation of local antitumour effectiveness of cisplatin in dogs and cats. *Anticancer Res.* 21, 2483–2488.