

Submitted: 12/10/2017

Accepted: 14/05/2018

Published: 01/06/2018

## Keratomycosis in captive red pandas (*Ailurus fulgens*): 2 cases

Hayley August Volk<sup>1,\*</sup>, Anu O'Reilly<sup>1</sup>, Kate Bodley<sup>2</sup> and Helen McCracken<sup>2</sup>

<sup>1</sup>Melbourne EyeVet, 9-11 Miles Street, Mulgrave, VIC 3170, Australia

<sup>2</sup>The Royal Melbourne Zoo, Elliot Ave, Parkville, VIC 3052, Australia

### Abstract

Two cases of keratomycosis in captive red pandas (*Ailurus fulgens*) were diagnosed and treated at a zoo in Melbourne, Australia across a 9-year period. Both cases presented with severe unilateral ocular pain and stromal abscessation of the cornea. A superficial keratectomy was performed in both cases and the diagnosis was confirmed with either cytology or histopathology. Following surgery, a combination of oral, topical and subconjunctival medical therapy contributed to a successful outcome.

**Keywords:** Captivity, Fluconazole, Fungal keratitis, Melbourne, Red panda.

### Introduction

Fungal keratitis, also known as keratomycosis, is a condition reported in many species, including dogs, horses, rabbits, cows, alpacas and humans (Elligott *et al.*, 2006; Bhartiya *et al.*, 2007; Ledbetter *et al.*, 2013; Voelter-Ratson *et al.*, 2013; Bourguet *et al.*, 2016; Nevile *et al.*, 2016). It is a debilitating ocular disease that can lead to vision loss and subsequent loss of the globe if secondary uveitis, glaucoma and/or endophthalmitis develops. It is therefore imperative that it is treated early and aggressively. Successful treatment often requires a combination of both topical and systemic medications, as well as surgical therapy in some cases (Xie *et al.*, 2001; Bunya *et al.*, 2007; Rogers *et al.*, 2013). In non-domesticated species, the use of topical medical therapy is a difficult obstacle to overcome due to both the stress it causes the animal, as well as prioritizing handler safety. While voluntary acceptance of topical medications can be trained in some captive zoological species with operant conditioning, this behavior takes a significant amount of time and training to develop and is therefore not practical in an acute presentation. Presented here are 2 cases of fungal keratitis in the red panda (*Ailurus fulgens*) seen by a referral ophthalmology service at the Royal Melbourne Zoo in July 2008 and March 2017.

### Case Details

#### Case 1

In July 2008, a 7-year-old male red panda (5.5kg) presented with a corneal opacity in the right eye. There was no known history of trauma and the level of apparent discomfort was deemed to be severe, based on marked blepharospasm and epiphora from the affected eye.

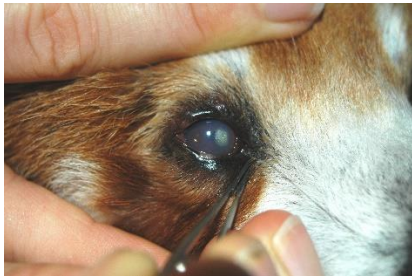Under a general anesthetic, the right eye was examined and found to have mild, diffuse corneal edema,

hyphema and a 3mm diameter focal area of stromal abscessation that was partially epithelialized (Fig. 1). The lesion was swabbed for cytology and culture and sensitivity. No abnormalities were found on examination of the fellow eye. A complete blood count and biochemistry were unremarkable and an in-house Difil test (Vetoquinol Australia, 6-12 Boronia Rd, QLD, Australia) was negative for heartworm. In-house urinalysis was also unremarkable. Topical atropine sulfate (Atropt 1% eye drops, Aspen Pharma Pty Ltd, St Leonards, NSW, Australia) was applied at the time of examination. Subconjunctival gentamicin (15mg; Gentocin®, Schering-Plough Pty Ltd, 66 Waterloo Rd, Macquarie Park, NSW, Australia) was administered and a third eyelid flap was placed using 4/0 nylon suture (Ethicon, Route 22 West, Somerville, NJ, USA). Subcutaneous carprofen (10mg; Carprive®, Norbrook Laboratories, 7/1 Trade Park Dr, Tullamarine, VIC, Australia) was administered. Oral doxycycline (25mg PO BID; Vibravet®, Zoetis Australia, 1/45 Poplar Rd, Parkville, VIC, Australia) and carprofen (10mg PO SID) was commenced.

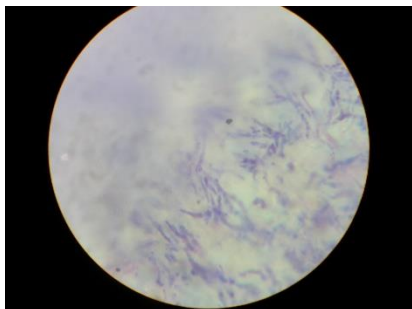
Two days later, under a second general anesthetic, the lesion was assessed by an ophthalmologist (AOR) and found to have marked corneal neovascularization and stromal abscessation that appeared to extend to 50% stromal depth. The pupil was miotic and hyphema was still present in the anterior chamber. Using an operating microscope, a superficial keratectomy was performed using an ophthalmic disc knife (Alcon, 6201 South Fwy, Fort Worth, TX, USA) to remove any grossly abnormal tissue. This was submitted for cytology, histopathology and culture. A conjunctival pedicle flap was not placed due to the axial location of the lesion, as it would have impaired vision post-operatively. Subconjunctival injections of gentamicin (15mg) and

\*Corresponding Author: Hayley August Volk, Melbourne EyeVet, 9-11 Miles Street, Mulgrave, VIC 3170, Australia.  
Tel.: +613 9545 0103; +614 3303 2255. Email: [hayleyaugust@yahoo.com.au](mailto:hayleyaugust@yahoo.com.au)

atropine (0.06mg; Atrosite, Troy-Ilium, 31-35 Glendenning Rd, Glendenning, NSW, Australia), as well as subcutaneous carprofen (10mg) were administered, followed by replacement of the third-eyelid flap. The histopathology results were consistent with severe, extensive, ulcerative, necrotizing fungal keratitis. Cytology demonstrated numerous filamentous fungal hyphae that were suggestive of *Aspergillus* species, though culture was negative (Fig. 2). The day after surgery, oral doxycycline (25mg PO BID) and carprofen (10mg PO) were continued and oral fluconazole (50mg PO SID; Symbion, 737 Bourke St, Docklands, VIC, Australia) therapy was commenced, however all oral therapy was then ceased 24 hours later, when the animal suffered from a T14-L1 Hansen's Type II disc prolapse. Therefore, a further 2 general anesthetics were performed 4 and 6 days after the initial assessment for imaging and spinal surgery, respectively. During both anesthetics, the third eyelid flap was let down and a generous amount of silver sulfadiazine 1% ointment (Flamazine®, Smith & Nephew Pty Ltd, 315 Ferntree Gully Rd, VIC, Australia) was applied to the affected cornea prior to replacing the third eyelid flap. The third eyelid flap was left in place for one week in total. Following spinal surgery, the animal was placed on carprofen (5mg PO SID for 5 days) and tramadol (5mg PO TID for 5 days; Symbion, 737 Bourke St, Docklands, VIC, Australia). Four weeks after the initial ocular lesion was noted, the lesion had healed with only a mild amount of fibrosis present. There was no evidence of vision loss or ongoing discomfort. All medication was discontinued.



**Fig. 1.** Epithelial plaque and stromal abscessation in the right eye of a male red panda (case 1).



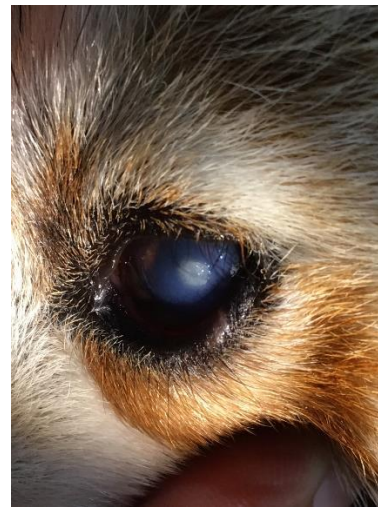**Fig. 2.** Cytology of affected corneal tissue in case 1, demonstrating filamentous fungal hyphae typical in appearance of *Aspergillus* spp.

### Case 2

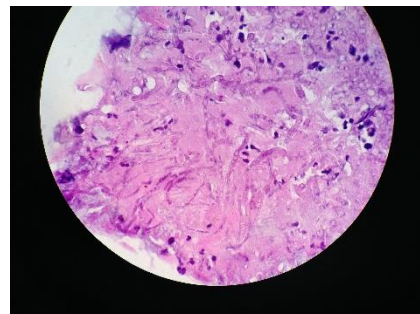
In March 2017, a 1-year-old female red panda (4.5kg) presented with marked blepharospasm of the left eye and a 4mm axial corneal opacity. There was no known history of trauma and the degree of discomfort was considered to be severe, as the animal had become inappetent and lethargic.

The following day, under a general anesthetic, the affected eye was assessed by an ophthalmologist (AOR) and was found to have diffuse corneal edema and an ulcerated 4mm diameter plaque over the axial cornea with corneal neovascularization from the dorsal limbus and aqueous flare (Fig. 3). Ophthalmic examination of the fellow eye was unremarkable. Using an operating microscope, a keratectomy was performed to remove the affected tissue, which extended to one-quarter stromal depth. Tissue samples were submitted for cytology, histopathology and culture.

Cytology results were inconclusive and culture was negative. Histopathology results were diagnostic of ulcerative fungal keratitis with an abundance of filamentous, branching fungal hyphae (Fig. 4). The fungi were not typical in appearance of *Aspergillus* spp.



**Fig. 3.** Epithelial plaque and stromal abscessation in the left eye of a female red panda (case 2).



**Fig. 4.** Histopathology of affected corneal tissue in case 2, demonstrating filamentous fungal hyphae, 100x magnification, oil immersion.

Gentamicin (10mg) and atropine (0.06mg) were administered subconjunctivally, and silver sulfadiazine 1% ointment was applied topically. A single temporary tarsorrhaphy suture was placed adjacent to the lateral canthus using 6/0 polyglactin 910 (Ethicon, Route 22 West, Somerville, NJ, USA). Meloxicam (1mg; Metacam®, Australia Boehringer Ingelheim Pty Ltd, 78 Waterloo Rd, North Ryde, NSW, Australia) and buprenorphine (0.045mg; Temvet®, Troy-Ilium, 31-35 Glendenning Rd, Glendenning, NSW, Australia) were administered intramuscularly.

The following day, oral fluconazole (50mg PO SID), doxycycline (13mg PO BID) and meloxicam (0.45mg PO SID) therapy was commenced.

Ten days after the surgery, the temporary tarsorrhaphy was removed as it had dislodged and was causing corneal irritation. At this time, the lesion was fluorescein negative with only mild fibrosis. Subconjunctival injections of gentamicin (10mg) and atropine (0.06mg) were repeated. Tricin® eye and ear ointment (Jurox, 85 Gardiner St, Rutherford, NSW, Australia) and silver sulfadiazine 1% ointment were applied topically. Fluconazole (50mg PO SID) continued for a further 10 days (20 day course in total) before all medication was discontinued. At this time, the degree of corneal fibrosis was considered to be mild and there was no apparent vision loss or ocular discomfort.

### Discussion

The red panda is an arboreal mammal native to Nepal and other areas of the eastern Himalayan region. It is unique in that its metabolism relies on a diet comprised entirely of bamboo to meet its nutritional requirements, despite its taxonomic classification within the order Carnivora (Panthi *et al.*, 2015; Fei *et al.*, 2017). Both its arboreal lifestyle and plant-based diet may have been contributing factors to the development of fungal keratitis seen here. This is because ocular trauma is the most frequently implicated cause of fungal keratitis and, specifically, bamboo-related trauma leading to the development of keratomycosis has been reported in humans (Gopinathan *et al.*, 2002; Lin *et al.*, 2005; Lan *et al.*, 2013; Qiu and Yao, 2013). The temperate climate in Melbourne, Australia may also be a risk factor for the development of fungal keratitis (Bhartiya *et al.*, 2007).

Though fungal culture in both cases was negative, histopathology results demonstrated an abundance of filamentous fungal organisms, which are typically associated with vegetative matter (Bhartiya *et al.*, 2007). Both *Aspergillus* and *Fusarium* spp. are thin, branching filamentous organisms of plant origin that have been associated with trauma-induced fungal keratitis (Cuero, 1980; Lin *et al.*, 2005; Richardson and Warnock, 2012; Chidambaram *et al.*, 2017). Treatment of plant-based fungal keratitis usually requires

aggressive, prolonged topical medical therapy in addition to surgery in some cases (Lin *et al.*, 2005). As prolonged topical medical therapy was not an option in either case presented here, surgery was performed early and oral antifungal therapy was instituted. Fluconazole was chosen as an adjunctive antifungal therapy due to its low-toxicity and high water-solubility that allows it to reach aqueous humor (Vaden *et al.*, 1997; Yee *et al.*, 1997).

The dose of 50mg PO q24h was extrapolated from its use in cats with ocular cryptococcosis (Malik *et al.*, 1992; O'Brien *et al.*, 2006). While fluconazole has been shown to have some efficacy against *Aspergillus* spp. (O'Day *et al.*, 1992), it is not typically the treatment of choice for managing keratomycosis caused by filamentous fungal organisms, for which topical medications are favored (Brooks *et al.*, 1998; Kalavathy *et al.*, 2005). Used here, oral fluconazole was well tolerated and easily administered in food, however its efficacy as an oral antifungal agent in managing filamentous keratomycosis cannot be determined as it was used as a single dose in the first case, which still had a successful outcome.

In both cases, topical silver sulfadiazine ointment was liberally applied to the affected cornea at the time of general anesthesia because it has been shown to have efficacy against fungal organisms in cases of equine keratomycosis (Betbeze *et al.*, 2006). Since topical medication could only be applied under general anesthetic, ointment was chosen for a longer-lasting effect than an antifungal in drop formulation. Subconjunctival injections were also utilized at the time of anesthesia to provide sustained, slow-release of medications, such as atropine, to the anterior segment. This technique is invaluable in species that can only be handled intermittently.

In both cases, the authors believe that early surgical intervention was the biggest contributor to a successful outcome. Careful and regular observation of these animals in their enclosures by zoo personnel was invaluable to the diagnosis and successful management of these cases.

### Conclusion

Early surgical intervention combined with a mixture of topical, oral and subconjunctival medications contributed to a successful, visual outcome in two cases of keratomycosis in the red panda.

### Conflict of interest

The Authors declare that there is no conflict of interest.

### References

- Betbeze, C.M., Wu, C.C., Krohne, S.G. and Stiles, J. 2006. In vitro fungistatic and fungicidal activities of silver sulfadiazine and natamycin on pathogenic fungi isolated from horses with keratomycosis. *Am. J. Vet. Res.* 67, 1788-1793.

- Bhartiya, P., Daniell, M., Constantinou, M., Islam, F.M. and Taylor, H.R. 2007. Fungal keratitis in Melbourne. *Clin. Exp. Ophthalmol.* 35, 124-130.
- Bourguet, A., Guyonnet, A., Donzel, E., Guillot, J., Pignon, C. and Chahory, S. 2016. Keratomycosis in a pet rabbit (*Oryctolagus cuniculus*) treated with topical 1% terbinafine ointment. *Vet. Ophthalmol.* 19, 504-509.
- Brooks, D.E., Andrew, S.E., Dillavou, C.L., Ellis, G. and Kubilis, P.S. 1998. Antimicrobial susceptibility patterns of fungi isolated from horses with ulcerative keratomycosis. *Am. J. Vet. Res.* 59, 138-42.
- Bunya, V.Y., Hammersmith, K.M., Rapuano, C.J., Ayres, B.D. and Cohen, E.J. 2007. Topical and oral voriconazole in the treatment of fungal keratitis. *Am. J. Ophthalmol.* 143, 151-153.
- Chidambaram, J.D., Prajna, N.V., Larke, N., Macleod, D., Srikanthi, P., Lanjewar, S., Shah, M., Lalitha, P., Elakkiya, S. and Burton, M.J. 2017. In vivo confocal microscopy appearance of *Fusarium* and *Aspergillus* species in fungal keratitis. *Br. J. Ophthalmol.* 101, 1119-1123.
- Cuero, R.G. 1980. Ecological distribution of *Fusarium solani* and its opportunistic action related to mycotic keratitis in Cali, Colombia. *J. Clin. Microbiol.* 12, 455-461.
- Elligott, C.R., Wilkie, D.A., Kuonen, V.J., Bras, I.D. and Neihaus, A. 2006. Primary *Aspergillus* and *Fusarium* keratitis in a Holstein cow. *Vet. Ophthalmol.* 9, 175-178.
- Fei, Y., Hou, R., Spotila, J.R., Paladino, F.V., Qi, D. and Zhang, Z. 2017. Metabolic rate of the red panda, *Ailurus fulgens*, a dietary bamboo specialist. *PLoS One*, 12, e0173274. doi: 10.1371/journal.pone.0173274.
- Gopinathan, U., Garg, P., Fernandes, M., Sharma, S., Athmanathan, S. and Rao, G.N. 2002. The epidemiological features and laboratory results of fungal keratitis - A 10-year review at a referral eye care center in south India. *Cornea* 21, 555-559.
- Kalavathy, C.M., Parmar, P., Kaliyamurthy, J., Philip, V.R., Ramalingam, M.D., Jesudasan, C.A. and Thomas, P.A. 2005. Comparison of topical itraconazole 1% with topical natamycin 5% for the treatment of filamentous fungal keratitis. *Cornea* 24, 449-452.
- Lan, L., Wang, F.Y. and Zeng, G. 2013. Staining with methylthioninium chloride for the diagnosis of fungal keratitis. *Exp. Ther. Med.* 6, 1229-1232.
- Ledbetter, E.C., Montgomery, K.W., Landry, M.P. and Kice, N.C. 2013. Characterization of fungal keratitis in alpacas: 11 cases (2003-2012). *J. Am. Vet. Med. Assoc.* 243, 1616-1622.
- Lin, H.C., Chu, P.H., Kuo, Y.H. and Shen, S.C. 2005. Clinical experience in managing *Fusarium solani* keratitis. *Int. J. Clin. Pract.* 59, 549-554.
- Malik, R., Wigney, D.I., Muir, D.B., Gregory, D.J. and Love, D.N. 1992. Cryptococcosis in cats: clinical and mycological assessment of 29 cases and evaluation of treatment using orally administered fluconazole. *J. Med. Vet. Mycol.* 30, 133-144.
- Nevile, J.C., Hurn, S.D. and Turner, A.G. 2016. Keratomycosis in five dogs. *Vet. Ophthalmol.* 19, 432-438.
- O'Brien, C.R., Krockenberger, M.B., Martin, P., Wigney, D.I. and Malik, R. 2006. Long-term outcome of therapy for 59 cats and 11 dogs with cryptococcosis. *Aust. Vet. J.* 84, 384-392.
- O'Day, D.M., Head, W.S., Robinson, R.D., Williams, T.E. and Gedde, S. 1992. The evaluation of therapeutic responses in experimental keratomycosis. *Curr. Eye Res.* 11, 35-44.
- Panthi, S., Coogan, S.C., Aryal, A. and Raubenheimer, D. 2015. Diet and nutrient balance of red panda in Nepal. *Naturwissenschaften* 102, 54. doi: 10.1007/s00114-015-1307-2.
- Qiu, W.Y. and Yao, Y.F. 2013. Mycotic keratitis caused by concurrent infections of *exserohilum mcginisii* and *candida parapsilosis*. *BMC Ophthalmol.* 13, 37. doi: 10.1186/1471-2415-13-37.
- Richardson, M.D. and Warnock, D.W. 2012. Keratomycosis. *Fungal Infection*. Wiley-Blackwell.
- Rogers, G.M., Goins, K.M., Sutphin, J.E., Kitzmann, A.S. and Wagoner, M.D. 2013. Outcomes of Treatment of Fungal Keratitis at the University of Iowa Hospitals and Clinics: A 10-Year Retrospective Analysis. *Cornea* 32, 1131-1136.
- Vaden, S.L., Heit, M.C., Hawkins, E.C., Manaugh, C. and Riviere, J.E. 1997. Fluconazole in cats: pharmacokinetics following intravenous and oral administration and penetration into cerebrospinal fluid, aqueous humour and pulmonary epithelial lining fluid. *J. Vet. Pharmacol. Ther.* 20, 181-186.
- Voelter-Ratson, K., Pot, S.A., Florin, M. and Spiess, B.M. 2013. Equine keratomycosis in Switzerland: a retrospective evaluation of 35 horses (January 2000-August 2011). *Equine Vet. J.* 45, 608-612.
- Xie, L., Dong, X. and Shi, W. 2001. Treatment of fungal keratitis by penetrating keratoplasty. *Br. J. Ophthalmol.* 85, 1070-1074.
- Yee, R.W., Cheng, C.J., Meenakshi, S., Ludden, T.M., Wallace, J.E. and Rinaldi, M.G. 1997. Ocular Penetration and Pharmacokinetics of Topical Fluconazole. *Cornea* 16, 64-71.