

Submitted: 24/08/2015

Accepted: 05/01/2016

Published: 09/02/2016

## Cardiotoxicity of *Senna occidentalis* in sheep (*Ovis aries*)

D.I.S. Lopes<sup>1</sup>, M.G. Sousa<sup>2\*</sup>, A.T. Ramos<sup>3</sup> and V.M. Maruo<sup>1</sup>

<sup>1</sup>Federal University of Tocantins (UFT), College of Veterinary Medicine and Animal Science, Araguaina, TO, Brazil

<sup>2</sup>Federal University of Paraná (UFPR), Department of Veterinary Medicine, Curitiba, Paraná, Brazil

<sup>3</sup>Federal University of Santa Catarina (UFSC), College of Veterinary Medicine, Curitibanos, Santa Catarina, Brazil

### Abstract

The cardiotoxicity of Coffee senna (*Senna occidentalis*) was investigated in sheep that were fed diets containing its seeds, which are recognized as the most poisonous part of such weed. Dianthrone, the main toxic component of *S. occidentalis*, is known to impair mitochondrial oxidative phosphorylation, leading to myofiber degeneration. In this study, fifteen ewes were fed 0%, 2% or 4% of seeds of *S. occidentalis* for 63 days. Non-specific markers of myocyte injury and electrocardiograms were undertaken at baseline, and at 14, 35, and 63 days after the animals were first fed the diets, while histopathology of heart samples was performed at the very end of the study. Our results showed an increase in serum AST and LDH over time, while CK-MB did not change significantly. Changes that could be ascribed to myocardial damage were not documented in the electrocardiograms. Cardiac histopathology demonstrated only mild-to-moderate vacuolar degeneration, myofiber edema and disarray, structural disorganization, and cellular necrosis. In conclusion, *S. occidentalis* caused myocardial fiber degeneration in a dose-dependent fashion, but the electrocardiogram was not able to identify these lesions non-invasively. Because the markers of myofiber injury used in this study lack specificity, they may not be used to support cardiac impairment objectively, despite some of them did change over time.

**Keywords:** Coffee senna, Electrocardiogram, Myofiber disarray, Plant toxicity.

### Introduction

*Senna occidentalis*, a weed belonging to the family *Caesalpinoideae*, is recognized as one of the most important poisonous plants in veterinary medicine (Tasaka *et al.*, 2000; Górnjak, 2008). This leguminous plant is commonly found in summer crops, therefore having its seeds contaminate the harvest, which will later be consumed together with the feed (Riet-Correa *et al.*, 1998; Haraguchi *et al.*, 2003). Poisoning can occur when all the plant is ingested, but most commonly it occurs indirectly when its seeds are not separated from cereal grains. Therefore, it is a concern even for animals under intensive confinement (Górnjak, 2008). Although all parts of *S. occidentalis* are poisonous, the seeds are thought to be more toxic (Haraguchi *et al.*, 1998) because of the elevated concentrations of dianthrone, an anthraquinone that interferes with the function of mitochondria, leading to swelling and impairment of its inner structure (Barbosa-Ferreira *et al.*, 2005; Górnjak, 2008). Either natural or experimental ingestion of *S. occidentalis* have been investigated in several species and resulted in an afebrile disease, which is characterized by prostration, muscle twitches, diarrhea, myoglobinuria, motor incoordination, and death (Barbosa-Ferreira *et al.*, 2005).

Skeletal muscle degeneration has been reported as a common finding in necropsies of several animal species. Alterations in the liver, central nervous system, and

heart muscle have been documented as well (Tokarnia *et al.*, 2002). Also, skeletal muscle histopathology demonstrated myofiber atrophy and interstitial edema, while vacuolar degeneration with structural disarray has been recognized in myocardial samples (Górnjak, 2008).

To the best of the authors' knowledge, the cardiotoxicity of *S. occidentalis* has never been investigated in ovines fed a diet containing increasing levels of dianthrone. Also, the potential use of electrocardiography as a non-invasive surrogate for myocardial injury was certainly not studied in animals being fed *S. occidentalis*. In this study, we hypothesized that diets containing more seeds of this weed would result in more severe cardiac lesions. Therefore, the purpose of this investigation was threefold: 1) to investigate how the serum levels of non-specific markers of myofiber injury is affected in sheep fed *S. occidentalis*; 2) to determine whether electrocardiography could potentially identify any cardiac lesion caused by the diet; and finally, 3) to use histopathology to assess the changes in cardiac structure.

### Material and Methods

#### Animals

Fifteen mature mixed-breed ewes were recruited into a prospective experimental study. Inclusion criteria included the animals being completely healthy, as determined by a detailed clinical examination and

\*Corresponding Author: Dr. Marlos Gonçalves Sousa. Department of Veterinary Medicine, Federal University of Paraná (UFPR), Rua dos Funcionários, 1540, Cabral, Curitiba, PR, Brazil, CEP 80035-050. E-mail: [marlos98@ufpr.br](mailto:marlos98@ufpr.br)

ancillary laboratory tests (CBC and biochemistry) to rule out any conditions that could preclude their inclusion in this investigation. Exclusion criteria included anemia, leukocytosis, atypical biochemistry, as well as any part of physical examination being considered abnormal, such as altered temperature, enlarged lymph nodes, unusual cardiac and/or respiratory auscultation, and abdominal pain. Once enrolled in the study, the sheep were divided into three equal groups. Over a two-month period, each group was fed diets containing 0%, 2% or 4% of *S. occidentalis* seeds. Consumption of the diets was guaranteed by an individual monitoring of each animal throughout the experiment. The analysis of blood markers and the electrocardiograms were undertaken at baseline, and at 14, 35, and 63 days after the animals were first fed the diets. Histopathology of hearts was performed at the very end of the study, which was entirely conducted in accordance with guidelines outlined in the National Institutes of Health *Guide for the Care and Use of Laboratory Animals*.

#### **Plant**

*S. occidentalis* was obtained from rural properties and roadsides of the region (7°11'34.1"S 48°14'05.3"W) in which the study was undertaken. The plant was authenticated and deposited under register #HTO-10035 at the Federal University of Tocantins' herbarium located within Porto Nacional campus. The seeds used to prepare the feed were maintained in tightly sealed containers until the diets were produced at the university premises. The basic feed included 80% cornmeal and 20% soybean meal. Once it was produced, either 0%, 2% or 4% of *S. occidentalis* seeds were manually added in order to reduce the degradation of its active constituent.

#### **Biomarkers of myofiber injury**

Blood samples were drawn in sterile tubes. After centrifugation, serum samples were aliquoted and stored at -20°C until the batch analysis was carried out. Using commercially-available kits, we measured the serum levels of aspartate aminotransferase (AST/GOT Liquiform, reference 109, Labtest, Lagoa Santa, Brazil), creatine kinase MB fraction (CK-MB Liquiform, reference 118, Labtest, Lagoa Santa, Brazil), and lactate dehydrogenase (LDH Liquiform, reference 86, Labtest, Lagoa Santa, Brazil). All manufacturer recommendations were strictly followed for laboratory procedures involved with the measurements.

#### **Electrocardiogram**

One-minute computer-based electrocardiograms were recorded with a sweep speed of 50 mm/s and an 1 cm = 1 mV sensitivity. The animals were kept standing over a rubber isolation pad, and neither sedatives nor anesthesia were used throughout the procedure. To record a base-apex lead, the negative electrode was placed cranial to the left scapula at the jugular furrow, while the positive electrode was positioned just behind

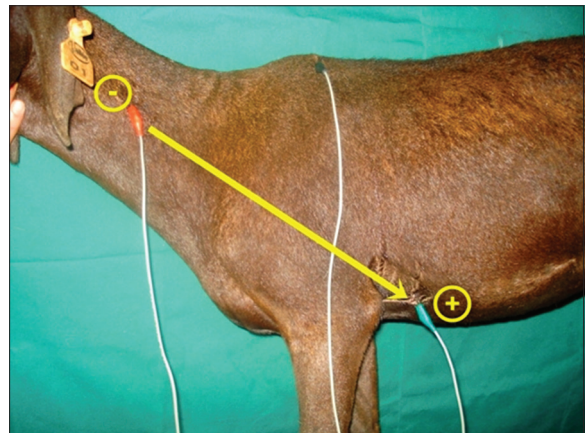
the left olecranon on the left chest wall (over the apex beat area of the heart) (Fig. 1). Several ECG parameters were measured, including P wave duration ( $P_{ms}$ ), P wave amplitude ( $P_{mv}$ ), duration of PR interval (PR), duration of QRS complex (QRS), R wave amplitude (R), S wave amplitude (S), duration of QT interval (QT), T wave amplitude ( $T_{mv}$ ), and duration of RR interval (RR). Changes in cardiac rhythm were also recorded.

#### **Histopathology of the heart**

A total of five cardiac tissue samples, which included the left ventricle free wall, right ventricle free wall, left atrium, right atrium, and the interventricular septum, were harvested from each animal. Samples were immediately fixed in 10% neutral-buffered formalin for 24 hours, and the fixed material was stored in 70% ethanol prior to processing into paraffin. Later, the samples were embedded in paraffin, sectioned at 5  $\mu$ m, and stained with hematoxylin and eosin staining. All heart samples were semi-quantitatively scored for injuries on a scale of 0 (absent), 1 (mild, small focal lesions), 2 (moderate, multifocal or focally extensive lesions), and 3 (severe, affecting most areas). A positive result was considered when at least one sample was altered in a given animal.

#### **Statistical analysis**

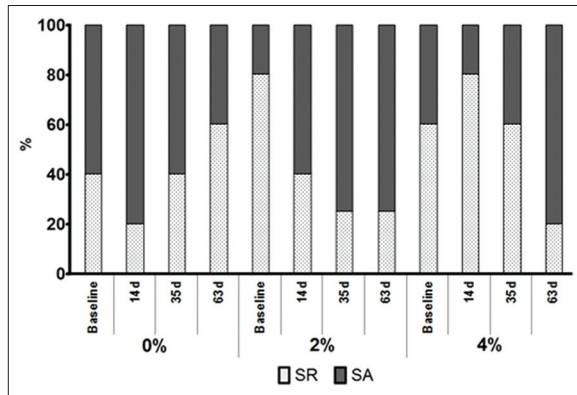
The enzyme and electrocardiographic data was tested for normality using the Shapiro-Wilk test. Either a repeated measures analysis of variance or the Friedman test was used to check for differences in these parameters over 63 days of study. Chi-square test was performed to look for an association between diet and the identification of myocardial lesions on histopathology. The software Prism for Windows v. 5.04 (Graphpad Software, San Diego CA, USA) was used for all statistical analyses, and probability < 0.05 was considered significant.



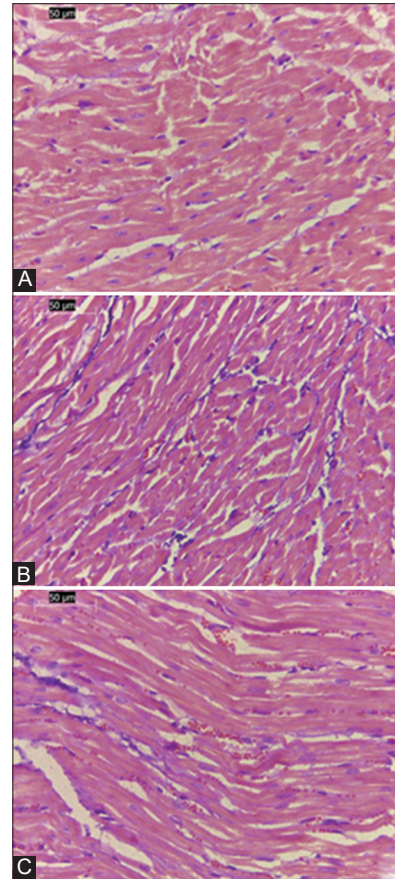
**Fig. 1.** Electrode placement to record the base-apex lead electrocardiogram. The negative electrode (red) is attached to the skin over the jugular furrow, just cranial to the left scapula, while the positive electrode (green) is placed on the apex beat area of the heart, just behind to the left olecranon. The ground electrode (black) is positioned over the thoracic spine. The electrical vector is represented with an arrow.

### Results

Table 1 shows the means and standard deviations of the plasma enzymes in all groups. AST and LDH increased significantly over time when diets containing either 2% or 4% of *S. occidentalis* seeds were fed to the animals. No significant alteration was documented for CK-MB data undergoing an analysis of variance. The electrocardiographic data is listed in Table 2, which shows an absence of consistent changes along the experimental period. Only sinus rhythm and sinus arrhythmia were identified throughout the study (Fig. 2). We observed variations in rhythms and sinus arrhythmia became more prevalent over time in ewes being given diets with either 2% or 4% *S. occidentalis* seeds. Nevertheless, an association between diets and rhythms could not be demonstrated by chi-square tests (0%  $P=0.6444$ ; 2%  $P=0.1718$ ; 4%  $P=0.2795$ ).



**Fig. 2.** Distribution of heart rhythms in sheep that were fed diets containing 0%, 2% or 4% of *Senna occidentalis* seeds. Only sinus rhythm (SR) and sinus arrhythmia (SA) were documented over time and no significant association could be demonstrated between diets and heart rhythms.



**Fig. 3.** Representative findings of the histopathological assessment of the left ventricular free wall from ewes fed a diet containing 0% (A), 2% (B) or 4% (C) of *Senna occidentalis* seeds. (A) Normal cardiac myofibers exhibiting a completely normal structural organization; (B) enlarged nuclei are seen within the myofibers; (C) enlarged nuclei and vacuolation of the cytoplasm around the nuclei are shown (H&E, 40x).

**Table 1.** Serum enzymes [mean (SD)] measured in ewes fed a diet containing 0%, 2% or 4% of *Senna occidentalis* seeds.

Diet (%)	Baseline	14 days	35 days	63 days
AST (U/L)				
0	101.2 (14.9)	105.0 (24.4)	123.0 (9.9)	127.7 (25.5)
2	92.6 (16.6)	98.9 (6.8)	113.1 (4.9)	160.7 (48.4)*
4	77.5 (18.0)	123.0 (25.0)	125.4 (24.3)	149.3 (50.7)*
CK-MB (U/L)				
0	101.7 (96.7)	110.1 (43.9)	135.0 (75.5)	145.0 (45.8)
2	200.0 (44.1)	160.0 (41.0)	258.3 (100.2)	185.8 (75.7)
4	200.0 (67.1)	143.3 (44.5)	188.3 (54.2)	128.8 (45.6)
LDH (U/L)				
0	817.2 (165.4)	666.4 (88.1)	710.4 (140.4)	1023.0 (273.8)
2	276.6 (276.6)	715.2 (220.0)	823.2 (41.5)	1088.7 (506.5)*
4	113.4 (113.4)	815.6 (152.3)*	927.2 (145.6)*	886.6 (240.3)*

\*Significantly different ( $P<0.05$ ) from the baseline measurement at the *post hoc* test. AST: Aspartate aminotransferase, CK-MB: Creatine kinase MB fraction, LDH: Lactate dehydrogenase

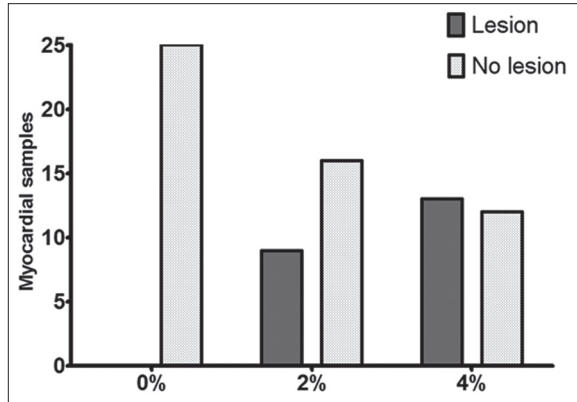
**Table 2.** Results [mean (SD)] of the base-apex electrocardiograms recorded in ewes fed a diet containing 0%, 2% or 4% of *Senna occidentalis* seeds.

Diet (%)	Baseline	14 days	35 days	63 days
<b>P<sub>ms</sub></b>				
0	52.60 (4.32)	50.60 (5.75)	60.80 (10.91)	51.40 (3.38)
2	58.80 (8.35)	63.20 (6.43)	62.50 (4.82)	63.20 (8.73)
4	52.80 (3.43)	57.80 (6.68)	59.40 (6.71)	57.20 (6.27)
<b>P<sub>mv</sub></b>				
0	0.19 (0.03)	0.12 (0.03)*	0.14 (0.02)	0.16 (0.03)
2	0.15 (0.05)	0.11 (0.03)	0.14 (0.03)	0.17 (0.01)
4	0.15 (0.04)	0.13 (0.02)	0.13 (0.03)	0.17 (0.05)
<b>PR</b>				
0	97.00 (8.00)	95.20 (10.21)	99.40 (16.28)	92.80 (11.30)
2	112.00 (12.93)	118.60 (8.43)	105.25 (11.14)	112.25 (7.19)
4	98.20 (10.54)	107.80 (10.01)	105.80 (21.90)	101.20 (13.48)
<b>QRS</b>				
0	70.60 (9.85)	53.20 (6.71)*	65.20 (9.20)	63.20 (7.81)
2	56.00 (2.68)	56.00 (5.25)	66.75 (15.22)	57.50 (7.63)
4	63.00 (11.02)	57.20 (5.81)	57.20 (8.21)	60.80 (7.14)
<b>R</b>				
0	0.03 (0.01)	0.02 (0.004)	0.03 (0.01)	0.03 (0.01)
2	0.07 (0.06)	0.06 (0.08)	0.05 (0.04)	0.06 (0.04)
4	0.03 (0.01)	0.03 (0.01)	0.02 (0.005)	0.03 (0.01)
<b>S</b>				
0	0.67 (0.26)	0.34 (0.12)	0.44 (0.19)	0.48 (0.06)
2	0.47 (0.17)	0.31 (0.13)	0.40 (0.12)	0.49 (0.16)
4	0.54 (0.19)	0.37 (0.12)	0.43 (0.10)	0.60 (0.25)
<b>QT</b>				
0	279.40 (28.16)	288.80 (20.25)	269.40 (28.09)	280.80 (25.51)
2	279.20 (18.51)	304.60 (38.53)	265.75 (24.77)	256.75 (46.49)
4	294.60 (14.29)	311.80 (36.19)	263.80 (20.57)	284.60 (34.00)
<b>T<sub>mv</sub></b>				
0	0.38 (0.15)	0.18 (0.09)	0.25 (0.11)	0.38 (0.21)
2	0.13 (0.10)	0.17 (0.15)	0.19 (0.13)	0.29 (0.05)
4	0.18 (0.06)	0.12 (0.03)	0.18 (0.09)	0.33 (0.14)
<b>RR</b>				
0	527.20 (128.11)	625.60 (86.90)	512.60 (112.14)	524.20 (116.21)
2	646.80 (59.64)	692.80 (140.80)	464.75 (49.06)*	525.75 (85.73)
4	655.60 (99.16)	713.00 (198.93)	502.40 (127.27)	553.40 (59.56)

\*Significantly different ( $P < 0.05$ ) from the baseline measurement at the *post hoc* test. P<sub>ms</sub>: P wave duration, P<sub>mv</sub>: P wave amplitude, PR: Duration of PR interval, QRS: Duration of QRS complex, R: Amplitude of R wave, S: Amplitude of S wave, QT: Duration of QT interval, T<sub>mv</sub>: Amplitude of T wave, RR: Duration of RR interval

On histopathological examination the microscopic structure of the heart of animals that were fed diets with no *S. occidentalis* appeared normal (Fig. 3A). On the contrary, all animals that were fed diets containing

*S. occidentalis* seeds had lesions detected in at least one cardiac sample. When a diet containing 2% of seeds was fed to the ewes, 36% (9/25) of the samples exhibited any abnormality (8/25 mild; 1/25 moderate), which included



**Fig. 4.** Identification of myocardial injuries on histopathology in sheep that were fed diets containing 0%, 2% or 4% of *Senna occidentalis* seeds. A significant association ( $P=0.0002$ ) was found to exist between the increasing amount of seeds in diets and the documentation of any cardiac lesions, which included cell vacuolation, myofiber swelling and disarray, pyknotic nuclei, acidophilic cytoplasm, and varying degrees of structural disorganization.

vacuolar degeneration, myofiber edema, and structural disorganization (Fig. 3B). For the animals receiving diets with 4% of seeds, 52% (13/25) of the samples had alterations (9/25 mild; 4/25 moderate), including a complete structural disorganization, with myofiber disarray, small, dark-staining pyknotic nuclei, and acidophilic cytoplasm, which are indicative of cellular necrosis (Fig. 3C). Although Chi-square test found a significant ( $P=0.0002$ ) association to exist between diets and the identification of myocardial lesions on histopathology (Fig. 4), severe lesions affecting most areas were not documented in any animal enrolled in this investigation.

### Discussion

In this study we sought to investigate the effects of diets containing increasing concentrations of *Senna occidentalis* seeds, which are recognized as the most poisonous part of that weed. Our main goals were to determine whether diets containing varying concentration of the plant seeds would produce changes, over a two-month period that could be documented by the electrocardiogram, by the serum concentration of some non-specific markers of cardiac injury, and by histopathology of the heart. AST and LDH serum concentrations increased significantly over time (Table 1). However, the non-specific nature of these enzymes, which may be released under a wide array of injuries, including liver damage, preclude its sole use to identify cardiac impairment specifically.

As mentioned before, the ECG disclosed no significant changes when the ewes were fed the diets. The very few changes found on the electrocardiographic data occurred in animals receiving diets with no seed at all (Table 2), except for a reduction in RR interval observed at 35 days in animals fed 2% of seeds. The

RR interval is inversely related to heart rate, therefore indicating an increased heart rate at the same moment. It is worth mentioning, however, that the instantaneous heart rate recorded by the electrocardiogram is heavily influenced by environmental conditions, including those that potentially cause stress to the animals, such as the physical restraint needed for ECG recording (Lago *et al.*, 2009). In a study in which 31 healthy ovines were enrolled, Schultz *et al.* (1972) found the heart rate to range from 60 to 197 bpm, showing its strong variation. Later, another investigation also found an increased mean heart rate of 119 bpm in normal sheep (Tório *et al.*, 1997). In this study, however, the mean heart rates remained within the normal range for ovines at all times. Sinus rhythm was the most prevalent cardiac rhythm at baseline evaluation, which is consistent with prior studies in sheep (Tório *et al.*, 1997; Mir *et al.*, 2000; Lago *et al.*, 2009). However, when diets containing seeds were given to the animals, there was a progressive non-significant change to sinus arrhythmia, which became the most prevalent rhythm at 63 days animals fed either 2% or 4% of *S. occidentalis* seeds. Curiously, sinus arrhythmia is not considered a malignant arrhythmia, since it results from variations in autonomic balance. Therefore, increases in sympathetic tone accelerate the heart rate, while the attenuated sympathetic tone reduces the heart rate. To the authors' knowledge, however, the effects of *S. occidentalis* in the autonomic balance was never investigated, and at this time we might speculate that these findings could be ascribed to the animals being more used to the exam room, therefore having an attenuated sympathetic response along the procedure. In contrast, the microscopic assessment of heart samples showed varying degrees of structural damage to the myocardial cells, which was more prevalent and severe in animals being given a 4%-seed diet. This condition is likely supportive of the toxicity of *Senna occidentalis* on the heart occurring in a dose-dependent fashion. Interestingly, no changes in QT interval could be observed, suggesting no impairment in ventricular total electrical activity in spite of the structural damage and myofiber disarray. P waves, which represent the atrial electrical activity, were consistently documented in all animals regardless of the diet being fed to them. Prior studies in ovines indicated a positive P wave in the majority of leads (Schultz *et al.*, 1972; Tório *et al.*, 1997), which is similar to our findings. In this study, 100% of the electrocardiograms exhibited positive P wave at lead II. It is likely that myocyte disorientation and myofibrillar disarray were not able to create an electrical milieu and substrate for supraventricular arrhythmias in these animals.

Alterations in cardiac muscle have been documented in several species being given *S. occidentalis*. Necrosis, vacuolar degeneration, structural disorganization, acidophilic cytoplasm, pyknosis, myofiber thinning, swelling and replacement by connective tissue are all

reported in many preceding investigations (O'Hara *et al.*, 1969; Martins *et al.*, 1986; Barros *et al.*, 1990; Tasaka *et al.*, 2000). Dianthrone, the main toxic component of *S. occidentalis*, is known to induce the uncoupling of mitochondrial oxidative phosphorylation, which is absolutely necessary to produce energy for the constant pumping action of the heart. Such energy-deprivation impairs the sodium-potassium pump activity and, as a result, water accumulates within the cell leading to myofiber degeneration (Barros *et al.*, 1990). Similarly, feeding diets containing either 2% or 4% *S. occidentalis* seeds to animals in this study for 63 days was enough to produce myocardial lesions that included vacuolation, pyknotic nuclei, acidophilic cytoplasm, and swelling of myofiber bundles, which resulted in varying degrees of structural disarray that are similar to previous reports (Suliman *et al.*, 1982; Suliman and Shommein, 1986; Barros *et al.*, 1999).

Among the several limitations of this investigation are the small number of animals recruited, the relatively short period of time during which the animals were fed the seed-containing diets, the absence of a cardiac-specific biomarkers such as troponin I, and finally, the absence of an echocardiographic assessment of the hearts to evaluate remodeling and function *in vivo*. Also, a more detailed microscopic assessment of the heart samples could reveal information on remodeling of the extracellular matrix, and whether apoptosis also played a role in the degenerative process ascribed to *S. occidentalis*.

### Conclusion

In conclusion, diets containing either 2% or 4% of *Senna occidentalis* seeds caused myocardial fiber degeneration in ewes in a dose-dependent fashion. A wide array of lesions was observed, but all animals had at least one lesion documented on cardiac histopathology. Although only mild lesions could be documented, this study found that a few animals that were given diets containing the plant seeds developed lesion within the myocardial tissue. Serum AST and LDH increased over time and might potentially aid in detecting myofiber injury. On the contrary, the electrocardiogram was not able to document any changes that could be related to myocardial damage.

### References

- Barbosa-Ferreira, M., Dagli, M.L., Maiorka, P.C. and Gorniak, S.L. 2005. Sub-acute intoxications by *Senna occidentalis* seeds in rats. Food Chem. Toxicol. 43, 497-503.
- Barros, C.S.L., Ilha, M.R.S., Bezerra Junior, P.S., Langohr, I.M. and Kommers, G.D. 1999. Intoxicação por *Senna occidentalis* (Leg. Caesalpinoidea) em bovinos em pastoreiro. Pesq. Vet. Bras. 19, 68-70.
- Barros, C.S.L., Pilati, C., Andujar, M.B., Graça, D.L., Irigoyen, L.F., Lopes, S.T. and Santos, C.F. 1990. Intoxicação por *Cassia occidentalis* (Leg. Caes.) em Bovinos. Pesq. Vet. Bras. 10, 47-58.
- Górniak, S.L. 2008. Plantas tóxicas de interesse agropecuário. In: Toxicologia aplicada à Medicina veterinária. Eds., Spinosa, H.S., Górniak, S.L. and Paterno-Neto J. Barueri:Manole, pp: 415-458.
- Haraguchi, M., Calore, E.E., Dagli, M.L., Cavaliere, M.J., Calore, N.M.P., Weg, R., Raspantini, P.C. and Górniak, S.L. 1998. Muscle atrophy induced in broiler chicks by parts of *Senna occidentalis* seeds. Vet. Res. Commun. 22, 265-271.
- Haraguchi, M., Dagli, M.L.Z., Raspantini, P.C.F. and Górniak, S.L. 2003. The effects of low doses of *Senna occidentalis* seeds on broiler chickens. Vet. Res. Commun. 27, 321-328.
- Lago, E.P., Melo, M.M., Araujo, R.B., Nascimento, E.F., Silva, E.F. and Melo, M.B. 2009. Perfis eletrocardiográfico e ecodopplercardiográfico de ovinos após ingestão da suspensão aquosa de *Mascagnia rigida* Griseb. (Malpighiaceae). Arq. Bras. Med. Vet. Zootec. 61, 853-862.
- Martins, E., Martins, V.M.V., Riet-Correa, F., Soncini, R.A. and Paraboni, S.V. 1986. Intoxicação por *Cassia occidentalis* (leguminoseae) em suínos. Pesq. Vet. Bras. 6, 35-38.
- Mir, S.A., Naski, A.R. and Raina, R. 2000. Comparative electrocardiographic studies and differing effects of pentazocine on ECG, heart and respiratory rates in young sheep and goats. Small Rumin. Res. 37, 13-17.
- O'hara, P.J., Pierce, K.R. and Kay Read, W. 1969. Degenerative Myopathy Associated with Ingestion of *Cassia occidentalis* L.: Clinical and Pathologic Features of the Experimentally Induced Disease. Am. J. Vet. Res. 30, 2173-2180.
- Riet-Correa, F., Soares, M.P. and Mendez Mdel, C. 1998. Poisonings in horses in Brazil. Ciência Rural 28(4), 715-722.
- Schultz, R.A., Pretorius, P.J. and Terblanche, M. 1972. An electrocardiographic study of normal sheep using a modified technique. Onderstepoort J. Vet. Res. 39, 97-106.
- Suliman, H.B., Wasfi, I.A. and Adam, S.E.I. 1982. The toxicology of *Cassia occidentalis* to goats. Vet. Hum. Toxicol. 24, 326-330.
- Suliman, H.B. and Shommein, A.M. 1986. Toxic effect of the roasted and unroasted beans of *Cassia occidentalis* to goats. Vet. Hum. Toxicol. 28, 6-11.
- Tasaka, A.C., Weg, R., Calore, E.E., Sinhorini, I.L., Dagli, M.L.Z., Haraguchi, M. and Górniak, S.L. 2000. Toxicity testing of *Senna occidentalis* seed in rabbits. Vet. Res. Commun. 24, 573-582.
- Tokarnia, C.H., Dobereiner, J.D. and Peixoto, P.V. 2002. Poisonous plants affecting livestock in Brazil. Toxicon 40, 1635-1660.
- Tório, R., Cano, M., Montes, A., Prieto, F. and Benedito, J.L. 1997. Comparison of two methods for electrocardiographic analysis in Gallega sheep. Small Rumin. Res. 24, 239-246.