

Pregnancy diagnosis by laparoscopy in free range rhesus macaques (*Macaca mulatta*)

V. Kumar^{1*}, A. Raj², P. Kumar³

¹Wild Life, Monkey Sterilization Centre, Distt - Kangra, Himachal Pradesh-176059, India

²Veterinary Hospital – Deol, Distt - Kangra, Himachal Pradesh-176125, India

³Department of Veterinary Obstetrics and Gynaecology CSKHPKV, Palampur Himachal Pradesh -176062, India

Abstract

The present study involved 50 adult female rhesus macaques (*Macaca mulatta*) of age ranging between 4 to 15 years. Pregnancy diagnosis was done by using laparoscopic method. Anesthesia was achieved by using xylazine (2mg/kg) and ketamine (10mg/kg) intramuscularly. The gravid uterus was located close to the urinary bladder in early pregnancy and in abdominal cavity in the mid and late stage of pregnancy. The procedure was completed within 10 - 12 minutes. There were no complications after the surgery and recovery of animal was smooth and uneventful. The results of this study showed that laparoscopic method is also one of the methods of pregnancy diagnosis in rhesus macaques and it can be a precise and a reliable method of pregnancy diagnosis in rhesus macaques.

Keywords: Free range, Laparoscopy, Pregnancy diagnosis, Rhesus macaque (*Macaca mulatta*).

Introduction

Rhesus macaques are sexually dimorphic like other species and females have an average height of 1.54 ft and an average weight of 5.34 kg (Fooden, 2000; Singh and Sinha, 2004). Rhesus macaques females reach puberty at around 3 years of age, while males mature sexually by 4 years of age. Females reproduce up to 20 years of age (Rawlins and Kessler, 1986). The majority of mating occurs in October through December and births coinciding with the end of the rainy season, or during the period of highest food abundance (Lindburg, 1971). Generally, one to two matings occur per year. The gestation period of rhesus monkeys ranges between 158 and 173 days (Krohn, 2009) with the average of 166.5 days (Silk *et al.*, 1993).

Various methods for such as caudal artery monitoring, palpation of the fetus, rectal palpation, non-return to oestrus (Wani and Sahni, 1980) are available for pregnancy diagnosis in animals depending upon the stage of gestation. Laparoscopy can be used as a method of pregnancy diagnosis by directly visualizing the genitalia in pregnant animals (Snyder and Dukelow, 1974; Goel, 1992). It has been found to be a unique tool as it allows the observation of the reproductive tract with little or no adverse effects on either the cycle or pregnant animal and provides a practical method of diagnosing pregnancy, determining ovulation numbers and studying uterine morphology and activity (Wildt *et al.*, 1975). Some methods give a higher degree of accuracy at the early

stage of gestation, others at the late stage of gestation (Goel, 1992). The objective of the present study was to diagnose pregnancy in rhesus macaques by a laparoscopic method.

Materials and Methods

Free-ranging rhesus macaques (*Macaca mulatta*) were captured during the breeding season (October-January) from different locations of Shivalik Hills in Himachal Pradesh, India. Capturing of rhesus macaques was done by trapping cage made of iron rods of size 2x2x2 meters. After capturing, the rhesus macaques were transported to Monkeys Sterilization Centre with adequate water and feeding arrangements. Animals were given rest for one to two days before laparoscopic procedure. General anesthesia was administered by intramuscular injection of ketamine 10 mg/kg body weight and xylazine 2mg/kg body weight (Troy Laboratories PTY Ltd., Australia). In advanced stage of pregnancy Ketamin at 15 mg/kg body weight was administered alone.

Clipping, shaving and scrubbing of the anaesthetized animal was done. Animal was placed in Trendelenburg's (head lower than body) position in dorsal recumbency. Pre umbilical incision of 6 mm was given on skin with scalpel on ventral mid line and 1st port was created and a veress needle was inserted through this incision to achieve pneumoperitonium with carbon dioxide at 8 mmHg pressure in order to get more space and visibility of organs and to avoid puncture of internal organs. The veress needle was then pulled out and a 6 mm trocar with canula was

*Corresponding Author: Monkey Sterilization Centre, Gopalpur, Distt Kangra, Himachal Pradesh -176059, India.
Email: drvijay0220@gmail.com

inserted in this port. One port of the same size was created laterally on left side 6 mm away from ventral midline of the body of animal. The trocar was removed from midline canula and telescope (5mm-diameter, Frontline Limited, Germany) connected to a light source inserted through this canula. A grasping forceps was inserted from lateral port to clear the visibility of gravid uterus. A light reddish-colored gravid uterus was clearly observed near the urinary bladder.

Results and Discussion

The induction of anesthesia was generally calm and smooth throughout the surgical procedure. The induction time was observed to be 4.06 ± 0.22 min. The duration of anesthesia was found to be 72 ± 0.28 min, recovery time was 48 ± 0.18 min., while time for laparoscopy was 10 ± 0.34 min. Surgical suture (Vicryl® 3-0, Ethicon) was used to avoid removal of the stitches after the healing of the surgical wounds and to avoid keeping the free range animals for a long period in captivity. In the present procedure, a moderate inflation of abdominal cavity was achieved by carbon dioxide gas at 8 mm of Hg pressure gradients. The 8 mmHg pressure gradient was sufficient to perform the laparoscopy in the pregnant macaques. The carbon dioxide flow rate of 1 L/min was also sufficient to maintain intra abdominal pressure. The pregnant uterus was easily recognized. The laparoscopic method of pregnancy diagnosis was found to be effective and precise in all stages of gestation in rhesus macaques. In the early stage of pregnancy (Figure 1), increased uterine size and change of shape from flat to round were observed.

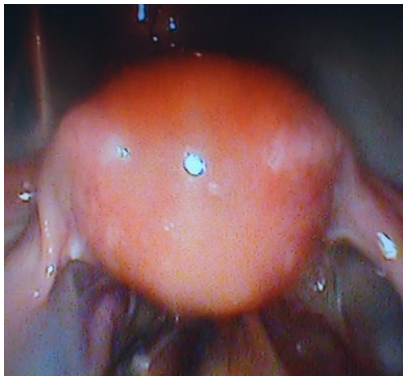


Fig. 1 Uterus at early stage of pregnancy

In mid stage of pregnancy the uterus was relatively larger in size and appeared as a ball (Figure 2). In the late stage of pregnancy, the uterus was visualized like 'shot put' ball (Figure 3).

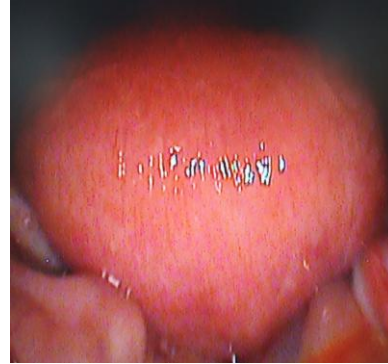

Fig. 2 Uterus at mid stage of pregnancy

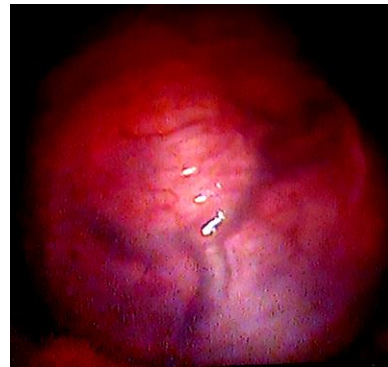

Fig.3 Uterus at late stage of pregnancy

The gravid uterus was located close to the urinary bladder in early pregnancy and in abdominal cavity in the mid and late stages of pregnancy. Laparoscopic procedure for various surgical interventions during pregnancy has been considered effective and safer in human females (Hunter *et al.*, 1995; Reedy *et al.*, 1998). In the present report, all the animals recovered smoothly and started eating and drinking.

Acknowledgements

We are grateful to Sh. Sameer Rastogi, Conservator of Forest, North Zone for providing valuable suggestions and help during the population control programme of rhesus macaques. We also thank the team of the Macaques Sterilization Centre wild life North Zone for their assistance throughout the work.

References

- Fooden, J. 2000. Systematic review of the rhesus macaque, *Macaca mulatta* (Zimmermann, 1780). Field Zool. 96, 1-180.
- Goel, A.K. 1992. A review of pregnancy diagnosis techniques in sheep and goats. Small Ruminant Res. 9, 255-264.
- Hunter, J.G., Swanstrom, L. and Thornberg, K. 1995. Carbon dioxide pneumoperitoneum induces fetal acidosis in a pregnant ewe model. Surg. Endosc. 9, 272-279.

- Krohn, P.L. 2009. The duration of pregnancy in rhesus macaques (*Macaca mulatta*). *J. Zool.* 134 (4), 595-599.
- Lindburg, D.G. 1971. The rhesus monkey in north India: an ecological and behavioral study. In: Rosenblum LA, editor. *Primate behavior: developments in field and laboratory research 2*, 1-106.
- Rawlins, R.G. and Kessler, M.J. 1986. Demography of the free-ranging Cayo Santiago macaques (1976-1983). In: *The Cayo Santiago macaques: history, behavior, and biology*. Albany (NY): State Univ New York Pr. p 13-45.
- Reedy, M., Kim, U., Thompson, E. and Rayburn, W.L. 1998. Laparoscopy during pregnancy. A safe alternative to laparotomy? *Contemp. Ob. Gyn.* 75-91.
- Silk, J., Short, J., Roberts, J. and Kusnitz, J. 1993. Gestation length in rhesus macaques (*Macaca mulatta*). *Int. J. Primat.* 14, 95-104.
- Singh, M. and Sinha, A. 2004. Life history traits: ecological adaptations or phylogenetic relics? In: Thierry B., Singh M., Kaumanns W., editors. *Macaque societies: a model for the study of social organization*. Cambridge (UK): Cambridge Univ Pr. 80-83.
- Snyder, D.A. and Dukelow, W.R. 1974. Laproscopic studies of ovulation, pregnancy diagnosis & follicular aspiration in sheep. *Theriogenology* 2(6), 143-148.
- Wani, G.M. and Sahni, K.L. 1980. An Ultrasonic technique for detection of pregnancy in Sheep and Goats. *Vet. Res. J.* 2(1), 35-73.
- Wildt, D.E., Morcom, C.B. and Dukelow, W.R. 1975. Laparoscopic pregnancy diagnosis and uterine fluid recovery in swine. *J. Reprod. Fert.* 44, 301-304.