

Submitted: 20/07/2018

Accepted: 03/04/2019

Published: 28/04/2019

## Mortality of four captive-born crested screamer chicks (*Chauna torquata*)

Lana Fox<sup>1,\*</sup>, Alexis Moreno<sup>2</sup> and Gregory Bradley<sup>3,4</sup>

<sup>1</sup>Department of Zoological Medicine, Texas A&M Veterinary Medical Teaching Hospital, 409 Raymond Stotzer Pkwy, College Station, TX 77845, USA

<sup>2</sup>Department of Veterinary Services, Reid Park Zoo, 1100 S Randolph Way, Tucson, AZ 85716, USA

<sup>3</sup>Arizona Veterinary Diagnostic Laboratory, 2831 N. Freeway, Tucson, AZ 85705, USA

<sup>4</sup>Department of Animal and Comparative Biomedical Sciences, The University of Arizona, 1117 E. Lowell St., Tucson, AZ 85721, USA

### Abstract

Crested screamers, a unique, mainly terrestrial avian species native to South America, are known to have a markedly high chick mortality rate in captivity, ranging from 61% to 94%; however, there is very limited information on this species' natural history within the literature, and even less about common diseases that affect them. Four captive-born crested screamer chicks (*Chauna torquata*) at a U.S. zoological institution died acutely from different causes over the course of 2.5 months. Although a hands-off approach was initially taken, each chick became acutely weak on exhibit and medical intervention was deemed necessary, but proved unsuccessful in all cases. Necropsy results of the chicks revealed various causes of death, including acute *Escherichia coli* colitis, aspiration pneumonia complicated by concurrent gastrointestinal Candidiasis, severe dehydration and emaciation, and acute amoebic gastroenteritis. No direct associations were found between these deaths and diet or husbandry; however, the limited literature on this topic suspects inadequate husbandry and immunosuppression to be the greatest cause of chick mortality in this species. The cases presented here are consistent with this hypothesis, but further exemplify the limited knowledge of this species and the need to optimize their survivability and proliferation in captivity.

**Keywords:** Amoebic gastroenteritis, Candidiasis, *Chauna torquata*, Chick mortality, Crested screamer.

### Introduction

Crested screamers (*Chauna torquata*) are an avian species native to South America, occupying a region spanning from southern Brazil to northern Argentina (Barrows *et al.*, 2005; Sacramento Zoological Society, 2016). They are in the order Anseriformes, and are part of the Anhimidae family, which also includes the horned and black-necked screamers (Silveira and Fowler, 2001; Barrows *et al.*, 2005). They live in tropical and subtropical wetlands, around lakes, rivers, and swamps (Barrows *et al.*, 2005). This bird species is large, approximately 0.75 m tall, and weighs between 3 and 5 kg. Although they are excellent fliers and swimmers, they are mainly terrestrial. Their unique anatomy includes a lack of uncinate processes and a skeleton thought to be the most pneumatic of all bird species (Barrows *et al.*, 2005; Encyclopaedia Britannica Inc., 2010; Klass, 2017a). Additionally, they have a well-developed system of air sacs, which is palpable as subcutaneous emphysema; their toes have vestigial webbing, and the carpi of both sexes have sharp spurs, which are used as a defense mechanism (Barrows *et al.*, 2005). Their proventriculus is large and sacculiform, designed to accommodate a mainly herbivorous diet (Barrows *et al.*, 2005; Dislich and Barros, 2014).

Crested screamers form monogamous breeding pairs and are known to have loud courtship and alarm calls (Sacramento Zoological Society, 2016). Large nests are built of sticks and reeds alongside shallow water. Both the male and female take turns incubating clutches of two to seven eggs for approximately 43–45 d (Silveira and Fowler, 2001; Sacramento Zoological Society, 2016). Chicks are born precocial, fledge between 8- and 10-wk old, and become fully independent between 12- and 14-wk old (Klass, 2017b). Adults can be very territorial during breeding season, but are gregarious during other times of the year, and have been seen in groups up to 1,400 in the wild (Dislich and Barros, 2014).

Their lifespan in the wild is estimated to be 15 yr, but in captivity, they have been known to live more than 35 yr (Klass, 2017b). Crested screamers are currently an International Union for Conservation of Nature species of least concern; however, in the wild, they are threatened by deforestation and destruction of wetlands (Klass and Lynch, 2017).

In captivity, just over 100 crested screamers are spread between 48 institutions (Klass and Lynch, 2017). Gene diversity is currently at 95%, with the current managed population descending from 26 original founders. The recommended diet of crested screamers consists of mainly gamebird or waterfowl pellets, and a mixture

\*Corresponding Author: Lana Fox. Department of Zoological Medicine, Texas A&M Veterinary Medical Teaching Hospital, 409 Raymond Stotzer Pkwy, College Station, TX 77845, USA. Email: [Lanafox3@gmail.com](mailto:Lanafox3@gmail.com)

of chopped greens and fruits. Their exhibits should also contain a natural pond so they can feed on aquatic plants; sharing an exhibit with a select variety of other herbivorous species has been successful.

Crested screamers are known to have an extremely high chick mortality rate in captivity. The current Association of Zoos and Aquariums (AZA) Species Survival Plan (SSP) population analysis reports a 61% chick mortality rate (Klass and Lynch, 2017); however, an institution in Brazil reports up to 94% mortality of 111 chicks hatched over 13 yr, with 90% of those deaths occurring within the first 2 mo of life (Dislich and Barros, 2014). Despite this markedly high mortality rate, very little research has been conducted to determine possible causes. The following information is a review of the literature available on causes of mortality in crested screamer chicks.

Various preliminary studies have been performed at Parque das Aves in Brazil, and the general consensus is that ensuring adequate husbandry and nutrition improved chick survival. Their research emphasizes water quality, as screamer chicks are very susceptible to a variety of bacterial diseases, such as *Pseudomonas* and *Aeromonas* spp. Other diseases this institution has encountered are suspected to be caused by immunosuppression due to an immature immune system, poor nutrition, environmental conditions, and stress. Some of these opportunistic infections include aspergillosis, intestinal candidiasis, and colisepticemia. An immature gastrointestinal flora is suspected to be a contributing factor to disease in crested screamer chicks as well (Dislich and Barros, 2014). Another study found that many diseases are related to improper diet and housing (Barrows et al., 2005). The study reports that the gastrointestinal impaction, specifically of the proventriculus, is the most common and significant disease of captive screamers, as well as a major cause of chick mortality. Impactions typically consist of inappropriate fiber sources, including alfalfa hay, or substrates, such as sand or grit. Often found concurrently is infection with *Macrorhabdus ornithogaster*, or avian gastric yeast.

Neurologic disease has been occasionally seen in chicks, which seems to be alleviated by adding multivitamin supplements to the diet (Dislich and Barros, 2014). Additionally, there is a report of two young chicks from Manitoba Zoo that presented with ataxia (Thompson et al., 2008). Histopathology of the affected chicks' brain parenchyma showed nematode larvae (*Baylisascaris procyonis*), as well as renal gout. Other reported diseases of captive screamers, not specific to chicks, include botulism, pododermatitis, trauma, poxvirus, and intestinal parasites (Barrows et al., 2005).

#### Case Details

Four crested screamer chicks (*Chauna torquata*) (3.1) successfully hatched from a clutch of four at a U.S. zoological institution in October 2017. However, over the course of approximately 2.5 months' time, all chicks

died and necropsies were performed (Latimer and Rakich, 1994). Both parents were deemed to be in good overall health based on physical exams and bloodwork performed approximately 7 mo prior to the chicks hatching. The male was approximately 7.5-yr old and the female was approximately 5.5-yr old at the time the chicks hatched. These are the only crested screamers in this collection. Although they were first-time parents, both the male and female were very attentive to the chicks and appropriately shared parental duties. All chicks were observed acting normally and eating within a 24-h period before their deaths. The exhibit the parents and chicks were housed in was outside and approximately 4,000 ft<sup>2</sup>. It was shared with two adult capybara (*Hydrochoerus hydrochaeris*) and numerous wild waterfowl species. The exhibit contained natural dirt and grass substrate, as well as a pond surrounded by plant vegetation. The water quality in the pool was maintained using a sand filter, which was dumped, cleaned, and refilled two to three times per week.

The adult screamers were offered Mazuri Waterfowl Maintenance Diet (Land O' Lakes, Inc., Arden Hills, MN 55126) as well as a variety of fruits and vegetables. In addition to consuming some of the adult diet, the screamer chicks were offered the following foods three to four times per day: Mazuri Waterfowl Starter Diet (Land O' Lakes, Inc., Arden Hills, MN 55126), Purina Layena Crumbles Premium Poultry Feed (Land O' Lakes, Inc., Arden Hills, MN 55126), hardboiled egg, and diced apple and greens. In addition, they were also frequently offered mealworms and waxworms. After the death of the second chick, the adult screamers and the remaining two chicks were moved to a nearby exhibit with the same features, but without the capybaras and with higher walls in order to provide a better barrier from cold and wind. The only other animals with access to this exhibit were wild waterfowl. Brooding heat lamps with nesting materials were also provided at two locations within the approximately 1,500 ft<sup>2</sup> exhibit.

#### Case 1

The first crested screamer chick was acutely found dead on exhibit at the age of 17 d. The chick was observed to be eating and active earlier that morning, although secluded from the other three chicks. There were no external findings that indicated the cause of death. On gross necropsy, the chick was determined to be a male and had no body fat stores. On histopathology, the lamina propria of the large intestines had diffuse infiltration of heterophils, with multifocal detachment of the epithelium from the mucosal surface and large numbers of bacteria present within the lumen. The cause of death was determined to be acute colitis. Culture of small intestinal organisms yielded a beta-hemolytic *Escherichia coli*, suspected to be clinically significant. West Nile Virus PCR was negative.

#### Case 2

The second screamer chick was 19-d old when keepers reported it appeared weak in the yard; it was removed

from the exhibit and brought to the veterinary hospital for supportive care. No physical exam was performed due to the concern for the patient's critical condition at the time. Instead, it was provided with heat and oxygen support, administered Clavamox orally twice daily (125 mg/kg; Zoetis Inc., Kalamazoo, MI 49007), and was tube fed approximately 3% of the chick's body weight with a mix of Harrison's Juvenile Formula (HBD International, Inc., Brentwood, TN 37027) and Dextrose 50% (Nova-Tech, Inc. Grand Island, NE 68801) every 4 h, as well as Bene-bac Plus Bird and Reptile Gel (2 g/bird; PetAg, Inc., Hampshire, IL 60140) into the crop once daily. Clavamox was chosen because it is a good first-line choice for a suspected infection of unknown origin due to its broad-spectrum of activity. The extensive air sac system of this species, including diffuse subcutaneous emphysema, precluded safe parenteral fluid treatment. Approximately 8 h later, the chick appeared brighter and was vocalizing, preening, and ambulating well. The following morning, the chick appeared dull. Immediately after the second feeding of the day, it regurgitated. Approximately 4 h later, the chick was observed flailing and open-mouth breathing. Despite increasing the oxygen concentration, it had decreased responsiveness, began to exhibit agonal breaths, and died roughly 30 min later.

On gross necropsy examination, the chick was found to be mildly underconditioned. The oral and esophageal mucosa was covered by a white, rough pseudomembrane. The lungs floated in formalin, but the periphery was plum-colored. Cytology of the oral mucosa revealed large numbers of *Candida* yeast and pseudohyphae. Histopathology showed parabronchi that contained fragments of aspirated food material surrounded by heterophils and extensive areas of pulmonary atelectasis. The tongue and esophagus were hyperkeratotic with heavy colonization by yeast and pseudohyphae. The proventriculus and ventriculus also contained large amounts of *Candida*. Aerobic culture of lung and intestine showed mild growth of *Candida*. The cause of death of this 19-d-old male chick was determined to be aspiration pneumonia complicated by concurrent gastrointestinal candidiasis.

#### Case 3

The third screamer chick was a female that died at 38 d of age. Approximately 2 wk prior to death, the chick was hand-grabbed for transport to a new exhibit with its conspecific and parents. An opportunistic physical examination was performed and was unremarkable at this time. Both chicks were treated once with prophylactic oral Nystatin (300,000 U/kg; VistaPharm, Inc., Largo, FL 33771) due to the second chick's necropsy results. Twelve days after moving to the new exhibit, the chick was observed not eating the morning meal and appeared to have a decreased activity level. The chick was then brought to the veterinary hospital for further care. On presentation, it was weak and felt cold to the touch. It was unable to stand on its own, but was still vocal.

The chick was provided with heat and oxygen support, and treatment with Clavamox (125 mg/kg) orally twice daily and Nystatin (300,000 U/kg) orally once daily was initiated. Supplemental feedings with Harrison's Juvenile Formula mixed with Normosol-R (Hospira, Inc., Lake Forest, IL 60045) and Dextrose 50% were given via a gavage tube into the crop. The chick became progressively weak, and mild regurgitation was noted after the second feeding of the day. The chick was found dead approximately 5 h later.

On gross necropsy, the chick was in very thin body condition, with no visceral or subcutaneous fat stores. The large intestine was full of a semiliquid green material and a mild amount of sand. On histopathology, there was no evidence of aspiration; the kidneys had mineralized tubules, which were associated with degeneration, necrosis, and sloughing of the tubular epithelium. Aerobic culture of the large intestines showed 4+ growth of *E. coli* and Gram-positive rods, which were considered normal colonic flora. The cause of death was attributed to severe dehydration and emaciation.

#### Case 4

The fourth chick of the clutch was a 72-d-old male who had been fluctuating in weight (230–280 g) for approximately 3 wk despite being bright and having a normal appetite. The weight fluctuations did not begin until approximately 1 mo after moving to the new exhibit. Because of this, the chick was being hand-grabbed for a body weight and gavage feeding of Harrison's Juvenile Diet and Bene-bac Plus Bird and Reptile Gel (2 g/bird) once daily into the crop. Nystatin (300,000 U/kg) was also given prophylactically once daily by mouth for 3 d due to the necropsy results of the second chick. During this time of close monitoring, the chick remained bright and was observed eating at each meal. Additionally, seven physical examinations were performed between the time the chick was moved to the new enclosure and when it started to show illness. These exams were performed when the chick was being hand-grabbed for the supplemental feedings; the only abnormalities noted were a small scab on the chest and mild erythema of the right commissure of the mouth, both of which resolved. Three days after its last physical exam, the chick was noted to be disoriented and struggling to rise on exhibit, so it was brought to the hospital for heat support, supplemental feedings, and observation. After being placed in the incubator, it was observed to be bright, vocalizing, and ambulating normally. The chick was given Clavamox (125 mg/kg) by mouth twice daily, Nystatin (300,000 U/kg) by mouth once daily, and was gavage fed Harrison's Juvenile diet with Dextrose 50% into the crop. The next morning, the chick was found on its side and very weak, with an increased respiratory effort. Oxygen therapy was initiated, but the chick continued to show progressive weakness and a depressed mentation. Dexamethasone-SP (0.12 mg/kg; Bimeda-MTC Animal Health Inc., Cambridge, ON N3C 2W4, Canada) was administered once intramuscularly

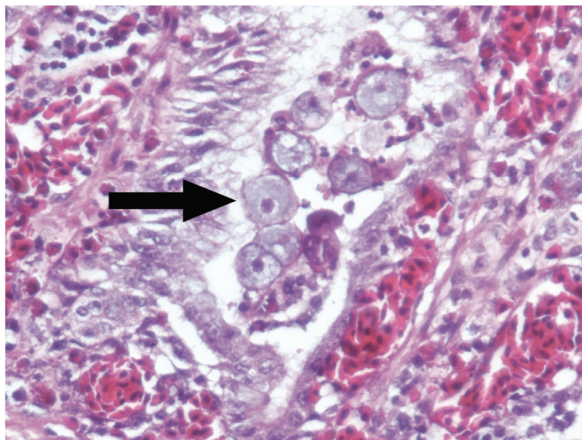
for its potent anti-inflammatory effects and to improve hemodynamics in the face of suspected shock. Less than an hour later, the chick was found dead.

On gross necropsy, the chick was in good body condition. The apical portions of the lungs were red and wet. Histopathology showed multifocal lung congestion. The proventriculus was filled with gruel and feathers, suggesting stasis. The proventriculus had an erythematous mucosa covered by a white pseudomembrane. A section of the ventriculus showed heavy colonization of the koilin layer and glands by large numbers of amoeba trophozoites, which occasionally infiltrated into the lamina propria. The observed organisms had histologic features typical of amoeba, including size (20–40 µm in diameter), a nucleus with a prominent nucleolus, and vacuolated, pale basophilic cytoplasm (Eberhard, 2009). The lamina propria diffusely contained heavy infiltrates of heterophils. One section of small intestine showed diffuse mucosal congestion and heavy colonization of the mucosal surface by amoeba, also occasionally invading the lamina propria, with crypts full of amoeba and heterophils (Fig. 1).

Aerobic culture of the lung grew 3+ alpha-hemolytic *Streptococcus* species. Aerobic culture of the small intestine grew 4+ *Streptococcus* species, and aerobic culture of the proventriculus grew 4+ *E. coli* and 4+ *Staphylococcus* species, all considered normal intestinal flora. A fungal culture and wet mount of the proventriculus were both negative for pathogens. The cause of death of this chick was suspected to be acute, diffuse, severe amoebic gastroenteritis. The specific type of amoeba was unable to be identified.

### Discussion

Due to the strikingly high mortality rate observed in captive crested screamer chicks, it is imperative



**Fig. 1.** Multiple amoebae found within an intestinal crypt surrounded by heterophils. A single amoeba is identified by the arrow (Magnification 40×).

to investigate any and all factors of husbandry and/or veterinary intervention that could be contributing to the poor proliferation of this species in captivity. Although these specific chicks were not examined prior to the first chick death, the benefits and detriments of performing a routine exam at an earlier age, or even hand-rearing should be considered. These four cases demonstrate very different causes of death despite the same diet, environment, and medical treatment. Whether or not any of these deaths could have been preventable is unclear; however, it is possible that they were all immunocompromised and each chick showed a different manifestation of it depending on the environmental conditions, food and water availability, parent attentiveness, chick hierarchy, and stress at that time.

Although screamers reportedly do well in mixed species exhibits, there is the possibility that the competition for food and/or the different gastrointestinal flora in other species had an effect on the chicks. Intestinal dysbiosis could certainly be a reason for invasion of *Candida*, *E. coli*, or amoebae. One study determined that it is crucial that screamer chicks are kept with their parents for the first few weeks of life in order for them to develop normal gastrointestinal flora (Dislich and Barros, 2014). Although these particular chicks remained with their parents, their immune system and gastrointestinal microbiome were still developing.

It is also possible that the other species, especially wild waterfowl, harbor and shed diseases that can be detrimental for chicks that have not yet developed immunocompetence. This is the most likely what occurred in the first chick. *Escherichia coli* can be a normal, nonpathogenic inhabitant of the lower avian digestive tract; however, strains can acquire virulence factors, or pathogenic strains can be transferred to chicks through the fecal-oral route, or even through fecal contamination of an egg containing a developing embryo (Schuster and Visvesvara, 2004). In the latter scenario, this results in death of the embryo or death of the chick within the first few weeks of life, which is consistent with Case 1. A study investigated whether free-living waterfowl, mainly mallard ducks (*Anas platyrhynchos*) and Canadian geese (*Branta canadensis*), living in zoological parks could serve as reservoirs of *E. coli* and other diseases (Fallacara et al., 2004). The overall prevalence of *E. coli* from waterfowl samples taken at a zoological park was 67%, showing that they are a large potential source of infection for other zoological species and even humans. There were not any documented illnesses or unexplained deaths in any of the wild birds that shared the exhibits with the crested screamers.

The cause of death of Case 4 was suspected to be amoebic gastroenteritis; however, amoebic infections of avian species have been rarely reported in the literature. Amoebae are free-living organisms found

within soil and fresh water ecosystems; they are known to cause opportunistic disease in humans and animals (Visvesvara *et al.*, 2010). One report isolated *Acanthamoeba* spp. from the liver of a Temminck's tragopan, which caused disseminated disease and death (Visvesvara *et al.*, 2010). Another report isolated *Acanthamoeba* spp. from a toucan that died acutely from associated severe granulomatous hepatitis and splenitis (Visvesvara *et al.*, 2007). Since screamers are Anseriformes, there are many opportunities for contact with amoeba given their environment. The portal of entry can be through breakage of the skin, ingestion, or inhalation. Free-living amoebae are not well adapted for parasitism and therefore, are very pathogenic to the host (Schuster and Visvesvara, 2004).

Despite four very different causes of chick mortality identified, all appear to be related to underlying immunosuppression, as all chicks died at a young age prior to having a fully developed immune system. The avian immune system is unique, in that the B- and T-cell lineages are in anatomically distinct organs (Fellah *et al.*, 2014). Maternal antibodies are transferred via the yolk to developing avian embryos, but only provide transient protection for up to 1 mo; furthermore, the bursa of fabricus does not reach its maximum size until 2–3 mo after hatching (Fellah *et al.*, 2014). Additionally, stress-induced immunosuppression is well known in avian species (Schat and Skinner, 2014). Potential environmental stressors are numerous and include temperature, light, air quality, nutrients, housing density, environmental contaminants (i.e., mycotoxins, pesticides), and overall sanitation (Koutsos and Klasing, 2014). Lack of certain immunomodulatory nutrients, such as vitamins A and E, can also contribute to physiologic stress and impaired functioning of the immune system.

Interestingly, two chicks were found to have no fat stores on necropsy. Case 1 died from colitis, which likely caused weight loss. Additionally, this chick was the runt of the group, and likely was not getting enough food due to competition with the other chicks. Alternatively, Case 3 died specifically from dehydration and emaciation. Since this chick was moved to a new exhibit 12 d prior to death, it is very likely that the stress from transport and being in a new environment caused hyporexia, especially because the physical exam performed at transport indicated adequate body condition.

Overall, finding a way to eliminate the presence of wild waterfowl, isolating the chicks to a more controlled environment, and providing a cleaner water source not contaminated by other species are all possible changes that should be considered to prevent future chick mortality at this institution. Additionally, considering early and frequent non-invasive diagnostics of chicks may be useful for disease prevention. This may include weekly fecal examinations, including a fecal

direct, float, and gram stain. Furthermore, the pros of performing a full physical exam once weekly should be weighed against the potential con of causing undue stress to the chicks and parents.

In summary, there is little known about why crested screamers have such high chick mortality rates in captivity. Additionally, it is controversial whether or not there should be hand-rearing efforts and/or earlier veterinary intervention. This is because there is a delicate balance in zoo species regarding when a veterinary exam and hospitalization is warranted versus continued close observation in order to give the chicks a chance to be raised naturally by their parents. Although no specific husbandry factor contributed to the death of these four chicks, the roles that husbandry and stress-induced immunosuppression play in this species' poor captive survival rate warrant further investigation.

#### Acknowledgments

The authors wish to thank the animal care staff of Reid Park Zoo for their care and dedication to these animals, as well as the University of Arizona Veterinary Diagnostic Laboratory for performing the necropsies.

#### Conflict of interest

The authors declare that there is no conflict of interest.

#### References

- Barrows, M., Hartley, M. and Pittman, J.M. 2005. Diseases and management of captive crested screamers (*Chauna torquata*). In the Proceedings of the 2005 European Association of Avian Veterinarians Conference, pp: 41–46.
- Dislich, M. and Barros, Y.M. 2014. Husbandry and breeding of Southern Screamers (*Chauna torquata*) at the Parque das Aves: experiences and challenges. *Int. Zoo News* 61(2), 109–116.
- Eberhard, M.L. 2009. Histopathologic Diagnosis. In *Georgis' Parasitology for Veterinarians*. Ed., Bowman, D.D. 9th Edn., Elsevier, St. Louis, MO, pp: 376–377.
- Encyclopaedia Britannica Inc. 2010. Screamer. Available from <https://www.britannica.com/animal/screamer#ref253166/> (Accessed 3 December 2017).
- Fallacara, D.M., Monahan, C.M., Morishita, T.Y., Bremer, C.A. and Wack, R.F. 2004. Survey of Parasites and Bacterial Pathogens from Free-Living Waterfowl in Zoological Settings. *Avian Dis.* 48(4), 759–767.
- Fellah, J.S., Jaffredo, T. and Dunon, D. 2014. Development of the avian immune system. In *Avian immunology*. Eds., Schat, K.A., Kaspars, B. and Kaiser, P. 2nd Edn., Elsevier, St. Louis, MO, pp: 51–66.
- Klass, J. 2017a. Crested screamer (*Chauna torquata*). AZA Regional Studbook, USA, pp: 1–145.
- Klass, J. 2017b. Crested (Southern) Screamer. ASAG Species Fact sheet, USA, pp: 1–4.

- Klass, J. and Lynch, C. 2017. Population analysis and breeding and transfer plan: crested screamer (*Chauna torquata*) AZA SSP Yellow Program. AZA Population Management Center, USA, pp: 1–36.
- Koutsos, E.A. and Klasing, K.C. 2014. Factors modulating the avian immune system. In Avian immunology. Eds., Schat, K.A., Kaspars, B. and Kaiser, P. 2nd Edn., Elsevier, St. Louis, MO, pp: 323–338.
- Latimer, K.S. and Rakich, P.M. 1994. Necropsy examination. In Avian medicine: principles and application. Eds., Ritchie, B.W., Harrison, G.J. and Harrison, L.R. Wingers Publishing, Inc., Lake Worth, FL, pp: 358–379.
- Sacramento Zoological Society. 2016. Crested Screamer. Available from [https://www.saczoo.org/wp-content/uploads/2016/12/Southern-Crested\\_Screamer.pdf/](https://www.saczoo.org/wp-content/uploads/2016/12/Southern-Crested_Screamer.pdf/) (Accessed 3 December 2017).
- Schat, K.A. and Skinner, M.A. 2014. Avian immunosuppressive disease and immune evasion. In Avian immunology. Eds., Schat, K.A., Kaspars, B. and Kaiser, P. 2nd Edn., Elsevier, St. Louis, MO, pp: 299–322.
- Schuster, F.L. and Visvesvara, G.S. 2004. Free-living amoebae as opportunistic and non-opportunistic pathogens of humans and animals. *Int. J. Parasitol.* 34, 1001–1027.
- Silveira, L.F. and Fowler, M.E. 2001. Order anseriformes (Ducks, Geese, Swans). In Biology, medicine, and surgery of South American wild animals. Eds., Silveira, L.F. and Fowler, M.E. Iowa State University Press, Ames, IA, pp: 103–114.
- Thompson, A.B., Glover, G.J., Postey, R.C., Sexsmith, J.L., Hutchinson, T.W.S. and Kazacos, K.R. 2008. *Baylisascaris procyonis* encephalitis in Patagonian conures (*Cyanoliseus patagonus*), crested screamers (*Chauna torquata*), and a western Canadian porcupine (*Erethizon dorsatum epixanthus*) in a Manitoba zoo. *Can. Vet. J.* 49, 885–888.
- Visvesvara, G.S., Booton, G.C., Kelley, D.J., Fuerst, P., Sriram, R., Finkelstein, A. and Garner, M.M. 2007. In vitro culture, serologic and molecular analysis of *Acanthamoeba* isolated from the liver of a keel-billed toucan (*Ramphastos sulfuratus*). *Vet. Parasitol.* 143, 74–78.
- Visvesvara, G.S., Schoff, M.E., Sriram, R., Booton, G.C., Crary, M., Fuerst, P.A., Hanley, C.S. and Garner, M.M. 2010. Isolation, morphologic, and molecular identification of *Acanthamoeba* T4 genotype from the liver of a Temminck's tragopan (*Tragopan temminckii*). *Vet. Parasitol.* 170, 197–200.