

Submitted: 03/03/2015

Accepted: 02/08/2015

Published: 07/08/2015

## Double filtration plasmapheresis in a dog with multiple myeloma and hyperviscosity syndrome

I. Lippi<sup>1,\*</sup>, F. Perondi<sup>2</sup>, S.J. Ross<sup>1</sup>, V. Marchetti<sup>2</sup>, G. Lubas<sup>2</sup> and G. Guidi<sup>2</sup>

<sup>1</sup>UC Veterinary Medical Center San Diego 10435 Sorrento Valley Rd, Suite 101, San Diego, CA 92121, USA

<sup>2</sup>Dipartimento di Scienze Veterinarie, Università di Pisa, Via Livornese lato monte, 56122 San Piero a Grado (PI), Italy

### Abstract

A 12 year old, 38 kg, mix-breed, intact male dog presented with a 20 day history of clinical signs consistent with hyperviscosity syndrome secondary to multiple myeloma. The dog received three double filtration plasmapheresis treatments on day 0, 7 and 22 after presentation. A significant ( $p < 0.05$ ) reduction in serum total protein, alpha-2 and gamma globulins was found following each treatment. These reductions were accompanied by a complete resolution, although temporary, of the clinical signs of hyperviscosity syndrome. The present study reported for the first time the use of double filtration plasmapheresis to reduce clinical signs of hyperviscosity syndrome in a dog with multiple myeloma.

**Keywords:** Apheresis, Dog, Double filtration, Hyperviscosity syndrome, Multiple myeloma.

### Introduction

Double filtration plasmapheresis (DFPP) is a recently developed apheretic technique used in human medicine for several pathological conditions such as metabolic (hypercholesterolemia, hyperlipoproteinemia), neurologic (myasthenia gravis, polyneuropathy, Guillain-barré syndrome), hematologic (thrombotic thrombocytopenic purpura), dermatologic (pemphigus), rheumatologic (systemic lupus erythematosus) and renal (acute glomerulonephritis) (Lyu *et al.*, 2002; Yeh *et al.*, 2006; Fernández-Fuertes *et al.*, 2010; Karakus *et al.*, 2013; Kasuya *et al.*, 2013; Lumlertgul *et al.*, 2013; Li *et al.*, 2015). Compared to plasma exchange (PE), DFPP technique selectively removes high-molecular weight substances, including immunoglobulins (Ig) and immune complexes, without the need to infuse substitution fluids to the patient (Yeh *et al.*, 2006). In human medicine, PE technique has been historically used to treat hyperviscosity syndrome (HVS) secondary to multiple myeloma (Zarcovic and Kwaan, 2003; Ballestri *et al.*, 2007). However, recent acquisitions showed that DFPP can be an effective alternative to PE in the treatment of HVS (Jiang *et al.*, 2014). HVS is a life-threatening complication and can occur when the normal plasma viscosity increases as a consequence of excessive increase in blood cells or abnormal plasma components, such as antibodies, immune complexes, para-proteins and cryoglobulins (Zarcovic and Kwaan, 2003; Ballestri *et al.*, 2007; Dumas *et al.*, 2015). HVS is a common finding in Waldenström's syndrome, macroglobulinemia and multiple myeloma (Mehta and Singhal, 2003; Ballestri *et al.*, 2007; Dumas *et al.*, 2015). In veterinary medicine, HVS is frequent feature

in patients with monoclonal gammopathies (Giraudel *et al.*, 2002). PE has been used in veterinary medicine to treat HVS (Matus *et al.*, 1983; Wahlin *et al.*, 1984; Giraudel *et al.*, 2002; Vail, 2007; Borgatti, 2010), but no data are available regarding the use of DFPP.

The present study reported for the first time the use of DFPP to reduce clinical signs of HVS in a dog with multiple myeloma.

### Case Details

A 12 year old, 38 kg (83.12 lb), mix-breed, intact male dog presented with a 20-day history of clinical signs consistent with HVS. The dog had been diagnosed with multiple myeloma 17 months before, based on bone marrow plasmacytosis and serum monoclonal gammopathy. Initial therapy had included melphalan (Alkeran<sup>®</sup>, GlaxoSmithKline) at 0.05 mg/kg/day (0.02 mg/lb/day) and prednisolone (Deltacortene<sup>®</sup>, Bruno Farmaceutici) at 1 mg/kg/day (0.45 mg/lb/day). The patient had shown significant clinical improvement for 15 months on this treatment protocol. At time of presentation the patient was no longer responsive towards medical therapy and showed signs of HVS. At clinical examination the dog showed weight loss (1.5 kg (3.5 lb) within one month), severe panting and weakness and unilateral blindness as a consequence of a retinal hemorrhage. The haematological and biochemistry analysis showed a moderate non-regenerative anemia, with lymphopenia, monocytopenia, eosinopenia and thrombocytopenia, as well as a marked increase in serum total protein. Serum electrophoresis revealed an increase in gamma globulins, and a reduction in albumin, alpha-1 globulins, and beta globulins (Table 1). HVS was diagnosed on the basis of the clinical and laboratory signs.

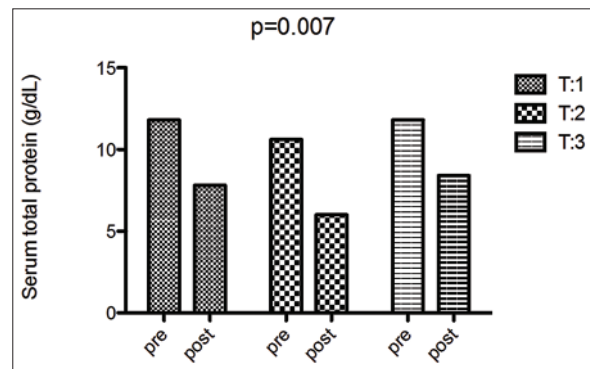
\*Corresponding Author: Dr. Ilaria Lippi. UC Veterinary Medical Center San Diego 10435 Sorrento Valley Rd, Suite 101, San Diego, CA 92121, USA. E-mail: [ilippi@ucdavis.edu](mailto:ilippi@ucdavis.edu)

Chest radiographs and abdominal ultrasound at presentation were unremarkable. With the owner's informed consent, the dog was anesthetized and a 12 Fr, 15 cm dual lumen central venous catheter (Haemocath® Signo V 1215, BBraun) was placed in the right jugular and advanced into the cranial vena cava via the Seldinger technique. A CRRT machine (Diapact® CRRT System BBraun, Melsungen) was used in DFPP modality. The extracorporeal blood circuit volume was 150 ml. A 0.2 m<sup>2</sup> polyethylene plasma separator (Plasmaflo™ OP-02, ©Asahi Kasei Kuraray Medical Co., Ltd), with a 25 ml of priming volume and a maximum pore size of 0.3 µm, was used for separating plasma. A 2 m<sup>2</sup> ethylene vinyl alcohol copolymer plasma filter (Cascadeflo™ EC-50, ©Asahi Kasei Kuraray Medical Co., Ltd), with 110 ml of priming volume, was used for membrane filtration. The total plasma volume of the patient was estimated to be approximately 1900 ml (Wellman *et al.*, 2012). Using guidelines established in human medicine, blood flow and plasma flow were set at 70 ml/min and 20 ml/min respectively and the treatment time was set at 2 hours, to obtain an estimated macromolecule reduction ratio (MRR) of 70%. Heparin was administered as an intravenous bolus at 100 UI/kg (45.3 UI/lb) five minutes before starting the procedure, then as a continuous rate intravenous infusion at 50 UI/kg/h (22.6 UI/lb). Anticoagulation was monitored and adjusted based on activated clotting time (ACT) obtained every 30 minutes (Ismail *et al.*, 2007). The dog received treatments on day 0, 7 and 21 following presentation. No complications were encountered during the treatments, with the exception of poor catheter performance during the third treatment, that

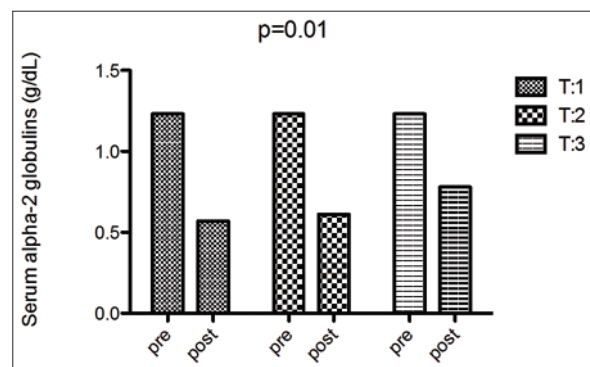
necessitated reversal of the arterial and venous lines. Pre-treatment blood samples were collected 10 minutes before the start of the procedure. Post-treatment blood samples were collected 15 seconds after the end of the procedure at a standard blood flow of 50 ml/min. The pre-treatment and post-treatment values of each plasmapheresis session (Table 2) were compared using a two-way ANOVA ( $p < 0.05$ ) and using standard statistics software (Fig. 1, Fig. 2, Fig. 3 and Fig. 4). During the first treatment (Day 0) a macromolecular reduction ratio (MRR) of 33.9% was obtained, while in the second (Day 7) and in the third (Day 21) treatment a MRR of 43.4% and 28.8% were obtained respectively. Associated with the significant reduction of the plasma protein (Table 2) was an almost complete resolution of the clinical signs. The dog developed catheter complications two days after the last treatment and the owners decided not to replace it. The patient died within 25 days of the last plasmapheresis.

**Table 1.** Haematological and biochemical abnormalities.

Parameters	Value	Reference range
RBC	3.36	5.65-8.87 (M/ $\mu$ L)
Hct	20.9	37.3-61.7 (%)
Hgb	7.4	13.1-20.5 (g/dL)
Reticulocytes	7.5	10.0-110.0 (K/ $\mu$ L)
WBC	4.39	5.05-16.76 (K/ $\mu$ L)
Lymphocytes	0.45	1.05-5.10 (K/ $\mu$ L)
Monocytes	0.15	0.16-1.12 (K/ $\mu$ L)
Eosinophils	0.05	0.06-1.23 (K/ $\mu$ L)
PLT	24	148-484 (K/ $\mu$ L)
Total protein	11.8	5.5-7.7 (g/dL)
Albumin	2.63	2.7-4.0 (g/dL)
Alpha-1 globulins (g/dL)	0.25	0.3-0.4 (g/dL)
Alpha-2 globulins (g/dL)	1.23	0.6-1.4 (g/dL)
Beta-globulins (g/dL)	0.55	0.7-2.4 (g/dL)
Gamma globulins (g/dL)	7.14	0.4-0.9 (g/dL)



**Fig. 1.** Serum concentration of total protein before and after each plasmapheresis treatment. First treatment (T:1), second treatment (T:2), third treatment (T:3). Two-way ANOVA showed a significant reduction of total protein in in the post-treatment sample ( $p=0.007$ ).

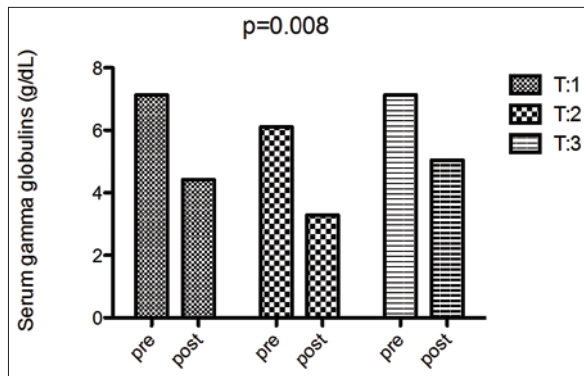


**Fig. 2.** Serum concentration of alpha-2 globulins before and after each plasmapheresis treatment. First treatment (T:1), second treatment (T:2), third treatment (T:3). Two-way ANOVA showed a significant reduction of alpha-2 globulins in the post-treatment sample ( $p=0.01$ ).

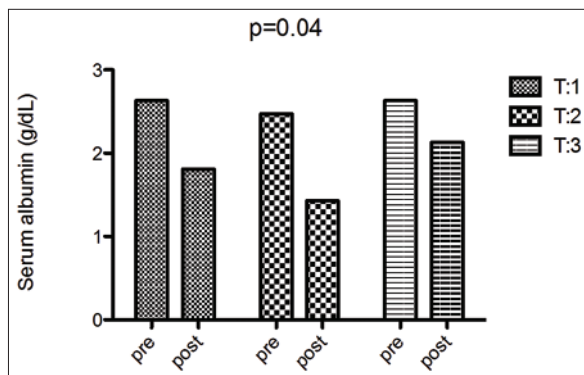
**Table 2.** Pre-treatment and post-treatment values and statistic value (p-value) of total protein, albumin, alpha 1 globulins, alpha 2 globulins, beta globulins and gamma globulins for each plasmapheresis session.

Parameters	Day 0			Day 7			Day 21		
	Pre	Post	p value	Pre	Post	p value	Pre	Post	p value
Total protein (g/dL)	11.8	7.8*	(p=0.007)	10.6	6.0*	(p=0.007)	11.8	8.4*	(p=0.007)
Albumin (g/dL)	2.63	1.81*	(p=0.04)	2.47	1.43*	(p=0.04)	2.63	2.13*	(p=0.04)
Alpha-1 globulins (g/dL)	0.25	0.26		0.23	0.19		0.25	0.17	
Alpha-2 globulins (g/dL)	1.23	0.57*	(p=0.01)	1.23	0.61*	(p=0.04)	1.23	0.78*	(p=0.04)
Beta globulins (g/dL)	0.55	0.71		0.46	0.47		0.55	0.28	
Gamma globulins (g/dL)	7.14	4.42*	(p=0.008)	6.11	3.29*	(p=0.008)	7.14	5.05*	(p=0.008)

\*Significant difference between the pre- and the post-treatment concentration.



**Fig. 3.** Serum concentration of gamma globulins before and after each plasmapheresis treatment. First treatment (T:1), second treatment (T:2), third treatment (T:3). Two-way ANOVA showed a significant reduction of gamma globulins in the post-treatment sample (p=0.008).



**Fig. 4.** Serum concentration of albumin before and after each plasmapheresis treatment. First treatment (T:1), second treatment (T:2), third treatment (T:3). Two-way ANOVA showed a significant reduction of the albumin concentration in the post-treatment sample (p=0.04).

### Discussion

HVS is a complication of multiple myeloma, occurring in approximately 20% of dogs affected by the disease (Borgatti, 2010). In one study (Giraudel *et al.*, 2002), signs of HVS were observed in 23% of the dogs with

a monoclonal gammopathies in general. The clinical presentation of HVS is variable, but typically includes one or more of the following: bleeding diathesis, neurologic signs (such as seizures, depression, coma), congestive heart failure, renal failure, and ophthalmic abnormalities, including tortuous and dilated retinal vessels, retinal hemorrhages, and retinal detachment, sludging of blood within small vessels, and impaired delivery of nutrients and oxygen to tissues (Vail, 2007; Borgatti, 2010).

HVS is a primary indication for the use of therapeutic plasmapheresis in humans (Wahlin *et al.*, 1984; Mehta and Singhal, 2003; Zarcovic and Kwaan, 2003) but also in companion animals (Vail, 2007; Boyle *et al.*, 2011). Therapeutic apheresis is an extracorporeal blood purification technique, designed for the removal of either plasma (plasmapheresis) or cellular blood components (cytopheresis) (Zarcovic and Kwaan, 2003). Plasmapheresis can be performed using either a centrifugal or a membrane filtration technique. In humans, centrifugal plasmapheresis is the primary modality in North America to separate the plasma from the other blood components (Drew, 2002; Zarcovic and Kwaan, 2003), while membrane plasma separation is more common in Europe and Japan.

The membrane filtration technique consists of separation of plasma from whole blood through a plasma separator and then removal of components of plasma through a plasma filter or plasma adsorber (Siemi and Siemi, 1999; Lyu *et al.*, 2002). The treated plasma is then mixed with cellular blood components and infused back into the patient's circulation, without the need for replacement fluid (Lyu *et al.*, 2002).

In the present study, post-treatment samples (Table 2) showed a significant reduction of the serum concentrations of both alpha-2 (Fig. 2) and gamma globulins (Fig. 3) (p=0.01 and p=0.008), indicating a significant efficacy of DFPP in reducing both acute and chronic inflammatory compounds. In the immediate post apheresis period for each treatment, the patient experienced a complete remission of clinical signs of HVS. This finding was in

agreement with a significant reduction of post-treatment serum total protein ( $p=0.007$ ) compared to pre-treatment values (Fig. 1). The clinical significance of the present finding is even more important if the actual MRR is considered. Although the average MRR of the three treatments (35.4%) was lower than expected (70%), a complete resolution of clinical signs of HVS was achieved. The largest MRR occurs with removal of the first volume of plasma. MRR becomes progressively less effective as subsequent plasma volumes are processed. For this reason one and at most two plasma volume equivalents are generally treated during a plasmapheresis session (Ismail *et al.*, 2007).

The length of time between two subsequent treatments was not the same and this element may have affected the relative MRR. The intravascular rebound of macromolecules is driven initially by diffusion of solutes from the extravascular to the intravascular space and then by endogenous synthesis. Finally, at the beginning of the third treatment a dysfunction of the arterial port of the venous catheter occurred, making the inversion of the ports necessary in order to maintain the scheduled blood flow. This fact may have contributed to reduce the efficacy of the treatment by increasing recirculation.

Cascadeflo™EC-50 is considered the plasma filter of choice for LDL-C removal (Molecular Weight approx. 2.400.000) in humans (Fernández-Fuertes *et al.*, 2010) with a very high sieving coefficient (0.8) for IgG and total protein (Fig. 2). Compared to other available plasma filters (EC-20, EC-30 and EC-40), Cascadeflo™EC-50 showed a significantly lower in vitro and in vivo removal of albumin. The use of Cascadeflo™EC-50 has been associated with a loss of only 10% of albumin. Therefore, the use of replacement solution is generally not necessary (Fernández-Fuertes *et al.*, 2010; Lumlertgul *et al.*, 2013). In the present case, the post-treatment concentrations of serum albumin were only mildly reduced (Fig. 4) and not associated with clinical signs of hypoalbuminemia. As a consequence, we opted not to give the patient replacement solution. Comparing to PE technique, double filtration shows some advantages (Lyu *et al.*, 2002; Kasuya *et al.*, 2013). The use of a plasma filter, instead to remove all patient's plasma, allows for a more selective removal of the targeted compounds, with minimal loss of non-pathogenic substances and albumin. The main advantage of DFPP is to infuse the patient back with its own purified plasma, with minimal or no need of reinfusion solutions (Lyu *et al.*, 2002; Yeh *et al.*, 2006), thus avoiding the high costs associated with plasma or albumin supplementation and limiting the depletion of the coagulation factors and other plasma compounds, that are removed when the PE is used. Additionally, the DFPP avoids potential complications such as risk of infection or protein

allergy, that may result from the exogenous plasma/albumin transfusion (Lyu *et al.*, 2002; Ismail *et al.*, 2007; Kasuya *et al.*, 2013). Moreover, the treatment requires a very short time (about two hours) and can be performed by using heparin as an anticoagulant, instead of citrate (Ismail *et al.*, 2007). On the basis of our first clinical experience, DFPP seemed to have a good efficacy to remove the excess of globulins and total protein, as previously reported in human medicine. In veterinary medicine, the use of PE technique has been reported in association with chemotherapy to treat HVS due to multiple myeloma (Matus *et al.*, 1983; Wahlin *et al.*, 1984; Giraudel *et al.*, 2002; Borgatti, 2010) but no data regarding the use of DFPP were available. The main limitation to the use of DFPP may be represented by the large volume of the extracorporeal circuit (285 ml), that may significantly limit the use of DFPP in small size patients. At present there are no available data about the potentially application of this technique in dogs with low weight, but the use of DFPP with extracorporeal high volume (410 ml) is reported in children (Fernández-Fuertes *et al.*, 2010). The present patient did not show any remarkable complications (hypotension, bleeding, infection, allergy reaction) and all clinical signs of HVS resolved completely in the inter-treatment interval of time. On the basis of these first clinical acquisitions, DFPP seems to be an interesting and promising technique, that deserves further investigations in the veterinary patient.

#### **Conflict of interest**

The Authors declare no conflict of interest. For the present work the authors received no financial support, in terms of grants, equipment or drugs.

#### **References**

- Ballestri, M., Ferrari, F., Magistroni, R., Mariano, M., Ceccherelli, G.B., Milanti, G., De Palma, M. and Albertazzi, A. 2007. Plasma exchange in acute and chronic hyperviscosity syndrome: a rheological approach and guidelines study. *Ann. Ist. Super Sanita.* 43(2), 171-175.
- Borgatti, A. 2010. Plasma cell tumors. In: Douglas J. Weiss and K. Jane Wardrop editors. *Veterinary Hematology.* Blackwell Publishing Ltd; pp: 511-519.
- Boyle, T.E., Holowaychuk, M.K., Adams, A.K. and Marks, S.L. 2011. Treatment of three cats with hyper-viscosity syndrome and congestive heart failure using plasmapheresis. *J. Am. Anim. Hosp. Assoc.* 47(1), 50-55.
- Drew, M.J. 2002. Plasmapheresis in the dysproteinemias. *Ther. Apher.* 6(1), 45-52.
- Dumas, G., Merceron, S., Zafrani, L., Canet, E., Lemiale, V., Kouatchet, A. and Azoulay, E. 2015. Hyperviscosity syndrome (*in French*). *Rev. Med. Interne.* doi: 10.1016/j.revmed.2015.02.005.

- Fernández-Fuertes, L.F., Tapia Martín, M., Nieves Plá, I., Novoa Mogollón, F.J. and Díaz Cremades, J. 2010. Low-Density Lipoprotein Apheresis Using Double Filtration Plasmapheresis: 27-Month Use in a Child With Homozygous Familial Hypercholesterolemia. *Ther. Apher. Dial.* 14(5), 484-485.
- Giraudel, J.M., Pagès, J.P. and Guelfi, J.F. 2002. Monoclonal Gammopathies in the Dog: A Retrospective Study of 18 Cases (1986-1999) and Literature Review. *J. Am. Anim. Hosp. Assoc.* 38(2), 135-147.
- Ismail, N., Kiprof, D.D. and Hakim, R.M. 2007. Plasmapheresis. In: Dauguidas JT, Blake PG, Ing TS, editors. *Handbook of dialysis*. 4th edn. Philadelphia: Lippincott Williams & Wilkins; pp: 276-299.
- Jiang, X., Feng, J. and Ye, Y. 2014. Double-Filtration Plasmapheresis for Treatment of Acute Renal Failure in a Multiple Myeloma Patient. *Ther. Apher. Dial.* 18(3), 318-319.
- Karakus, V., Deveci, B. and Kurtoglu, E. 2013. Treatment of plasmapheresis refractory thrombotic thrombocytopenic purpura with double-filtration membrane plasmapheresis. *Transfus. Apher. Sci.* 48(3), 313-314.
- Kasuya, A., Moriki, M., Tatsuno, K., Hirakawa S. and Tokura, Y. 2013. Clearance Efficacy of Autoantibodies in Double Filtration Plasmapheresis for Pemphigus Foliaceus. *Acta Derm. Venereol.* 93(2), 181-182.
- Li, M., Wang, Y., Qiu, Q., Wei, R., Gao, Y., Zhang, L., Wang, Y., Zhang, X. and Chen, X. 2015. Therapeutic Effect of Double-Filtration Plasmapheresis Combined With Methylprednisolone to Treat Diffuse Proliferative Lupus Nephritis. *J. Clin. Apher.* doi: 10.1002/jca.21408.
- Lumlertgul, D., Suteeka, Y., Tumpung, S., Bunnachak, D. and Boonkaew, S. 2013. Double filtration plasmapheresis in different diseases in Thailand. *Ther. Apher. Dial.* 17(1), 99-116.
- Lyu, R.K., Chen, W.H. and Hsieh, S.T. 2002. Plasma Exchange Versus Double Filtration Plasmapheresis in the Treatment of Guillain-Barré Syndrome. *Ther. Apher.* 6(2), 163-166.
- Matus, R.E., Leifer, C.E., Gordon, B.R., MacEwen, E.G. and Hurvitz, A.I. 1983. Plasmapheresis and chemotherapy of hyperviscosity syndrome associated with monoclonal gammopathy in the dog. *J. Am. Vet. Med. Assoc.* 183(2), 215-218.
- Mehta, J. and Singhal, S. 2003. Hyper-viscosity syndrome in plasma cell dyscrasia. *Semin. Thromb. Hemost.* 29(5), 467-471.
- Siami, G.A. and Siami, F.S. 1999. Plasmapheresis and paraproteinemia: cryoprotein-induced diseases, monoclonal gammopathy, Waldenström's macroglobulinemia, hyper-viscosity syndrome, multiple myeloma, light chain disease and amyloidosis. *Ther. Apher.* 3(1), 8-19.
- Vail, D. 2007. Haematopoietic tumors. In: Withrow SJ and Vail DM editors. *Small Animal Clinical Oncology*. 4th edn. St. Louis: Sanders Elsevier; pp: 699-784.
- Wahlin, A., Holm, J. and Nystrom, L. 1984. Improved survival in multiple myeloma with combination chemotherapy and plasmapheresis. *Haematologia (Budap)*. 17(4), 465-471.
- Wellman, M.L., Di Bartola, S.P. and Kohn, C.W. 2012. Applied physiology of body fluids in dogs and cats. In: Di Bartola SP, editors. *Fluid, electrolyte and acid-base disorders in small animal practice*. 4th edn. St Louis: Elsevier Saunders; pp: 2-4.
- Yeh, J.H., Chen, W.H., Chiu, H.C. and Bai, C.H. 2006. Clearance Studies During Subsequent Sessions of Double Filtration Plasmapheresis. *Artif. Organs* 30(2), 111-114.
- Zarcovic, M. and Kwaan, H.C. 2003. Correction of hyperviscosity by apheresis. *Semin. Thromb. Hemost.* 29(5), 535-542.