

## CASE REPORT

## Management of Post-traumatic Tension Pneumocephalus: a case report

Jude-Kennedy C EMEJULU

Ofodile C EKWEOGWU

Ezekiel U NWANKWO

Odili A OKOYE

Neurosurgery Unit  
Department of Surgery  
Nnamdi Azikiwe University  
Teaching Hospital  
Nnewi, NIGERIA

**Author for Correspondence**

Ofodile C EKWEOGWU  
Department of Neurological  
Surgery  
Institute of Neurological  
Sciences  
University College Hospital  
PMB 5116 Ibadan, NIGERIA

Received: August 27<sup>th</sup>, 2012

Accepted: October 7<sup>th</sup>, 2012

## ABSTRACT

Tension pneumocephalus results when air in the intracranial cavity causes a mass effect with abnormal neurological features, and head trauma accounts for most of the cases of this uncommon neurosurgical emergency. The condition requires a high index of suspicion for urgent confirmation with radiological investigation in open head injuries in order to facilitate an emergent surgical intervention to prevent unnecessary morbidity, and achieve optimum neurological outcome.

**Keywords:** Emergency, neurological deficits, open head injury

## INTRODUCTION

Pneumocephalus is defined as air in the cranial cavity, and when this results in a mass effect and/or abnormal neurological features, it is referred to as tension pneumocephalus.<sup>1,2,3,4,5</sup> Pneumocephalus occurs when the integrity of the cranial cavity is breached.<sup>2,3,5</sup> Small amounts of air are usually reabsorbed but progressive accumulation can occur.<sup>2</sup> Aetiological factors include head injury, intracranial infections, barotrauma and cranio-facial operative procedures following neurosurgical or otorhinolaryngology interventions, and neurosurgical diagnostic procedures.<sup>1,2,4,5,6,7,8,9,10</sup>

As little as 25ml of air can result in tension pneumocephalus which occurs when air accumulates in the intracranial cavity, leading to increased intracranial pressure.<sup>3</sup> If left untreated, this could lead to progressive brain compression with deteriorating sensorium and mental status from reduced oxygen supply to the brain, herniation of the brain, and consequently, death of the patient.<sup>4</sup> Surgical expulsion of air, as an emergency procedure, is the treatment for tension pneumocephalus.

We report a case of post-traumatic tension pneumocephalus resulting from a moderate open head injury which regained

consciousness fully following emergent surgical intervention and made an optimal neurological recovery.

#### CASE REPORT

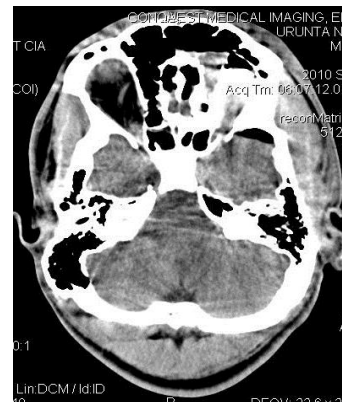
The index patient was a 20-year old right handed undergraduate, who presented at the Accident and Emergency Unit of our tertiary health centre, with loss of consciousness and multiple scalp and facial wounds of 5hours' duration prior to presentation following a passenger motorcycle road traffic accident. There was no cranio-facial efflux, post-traumatic seizure or vomiting.

On general physical examination, he was in painful distress and was tachycardic (pulse rate of 110/minute, full volume and regular), but other vital signs were normal. His Glasgow Consciousness Score (GCS) was 10, pupils were 3mm in diameter bilaterally and briskly reactive to light, he had a right supranuclear facioparesis and moved all four limbs actively and equally. He had right frontal and fronto-temporal lacerations (each 10cm long) and a partially avulsed right parieto-occipital ragged laceration (14cm long) with underlying quadrangular parietal skull fracture segment (4x7cm) that was elevated. The exposed dura was partially torn with evisceration of brain tissue. There were multiple scalp and facial abrasions, and all the wounds were grossly contaminated. Other systems were essentially normal.

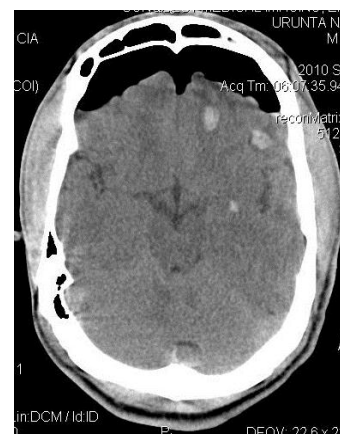A clinical diagnosis of moderate open head injury with a right parietal compound elevated skull fracture with dural tear and brain evisceration, multiple scalp abrasions and lacerations, multifocal cerebral contusions, ?intracranial space occupying lesion from a passenger motorcycle road traffic accident was made.

Cranial computed tomography (CT) with bone window showed a huge bi-frontal extradural pneumocephalus with 3cm dorsal displacement of both cerebral hemispheres, hyperdensities in the paranasal air sinuses, elevated right parietal calvarial fracture and multifocal cerebral contusions, see Figures 1, 2 and 3. His biochemical and haematological laboratory reports were normal.

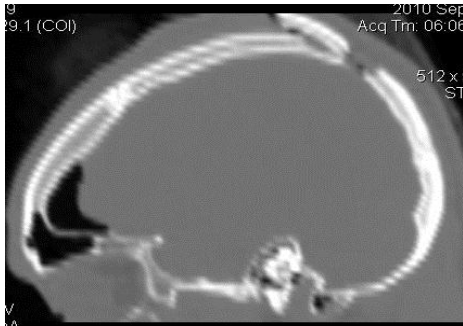
**Figure 1.** Evident anterior cranial fossa fracture – one of the likely entry sites of the intracranial air



**Figure 2.** Axial unenhanced computed tomogram revealing the huge bifronta pneumocephalus



**Figure 3.** Sagittal bone window showing the frontal pneumocephalus and elevated parietal skull fracture



By the 36<sup>th</sup> hour post-admission, he underwent bilateral frontal burr hole expulsion of the pneumocephalus aided by irrigation with sterile normal saline using a size-10 nasogastric tube, craniectomy and excision of the elevated right parietal calvarial segment, debridement of extracranial and intracranial (contused brain and dura mater) soft tissues and galeal duroplasty.

Intraoperative findings included right frontal and fronto-temporal linear lacerations, partially avulsed right parieto-occipital laceration with underlying extensive contused parietal brain with briskly bleeding cortical vessels, elevated quadrangular parietal calvarial fracture with 4 x7cm cranial defect and distally displaced bi-frontal lobe with a huge gas-filled (bubbles) extradural space.

Intravenous broad spectrum antibiotics were administered both pre- and post-operatively. He had generalized tonic-clonic seizures on the 3<sup>rd</sup> post-operative day for which he was placed on phenytoin sodium for 12 weeks with no recurrence. He was discharged home after 14 days on admission fully conscious and alert, with an optimal Glasgow Outcome Score of 5/5. An acrylic cranioplasty is intended for the cranial defect from the 9<sup>th</sup>

month post-operatively if there is no evidence of infection.

## DISCUSSION

Tension pneumocephalus following head trauma is an uncommon but potentially fatal condition that results in a mass effect and/or abnormal neurological features.<sup>1,3,4,5</sup> It occurs when there is a communication between the extracranial environment and intracranial cavity with progressive accumulation of intracranial air from open head injuries like in this index patient.<sup>2,3,5</sup>

The ball-valve mechanism and inverted soda-pop bottle phenomenon have been attributed to the development of tension pneumocephalus.<sup>2,3,4</sup> The ball-valve mechanism results when there is a uni-directional air flow into the intracranial cavity, whereas, a negative intracranial pressure from excessive cerebrospinal fluid (CSF) leakage has been postulated to be responsible for the inverted soda-pop bottle theory.

Clinical features are difficult to differentiate between intracranial haemorrhage and intracranial air, both of which lead to increased intracranial pressure, and these include headache, nausea, vomiting, seizure, dizziness and altered mental status.<sup>2,4,11,12</sup> Altered mental status and seizures were noted in our index patient.

Cranial CT scan is a sensitive diagnostic radiological investigation that can detect up to 0.5ml of pneumocephalus.<sup>4</sup> The 'Mount Fuji sign' (Figure 2) and 'air bubble sign' were evident in this patient. Skull x-rays play a vital role in diagnosis when cranial CT scan is not available or cannot be afforded by the patient.<sup>2,11,13</sup>

Treatment of tension pneumocephalus is emergent surgical evacuation of the air by open or endoscopic methods.<sup>1,2,3,4,10,14</sup> Adjuncts to surgery include supine positioning, oxygen therapy, antibiotics and analgesia.<sup>1,3,13,15</sup> Irrespective of the procedure that is adopted, timely expulsion of tension pneumocephalus holds the key to satisfactory outcome.

## CONCLUSION

Tension pneumocephalus is a rare emergency neurosurgical condition that requires a high index of suspicion for timely diagnosis, especially in open head injuries. Prompt evaluation and emergent operative intervention prevents unnecessary morbidity and mortality.

## REFERENCES

1. Chibber SS, Nizami FA, Kirmani AR, Wani MO, Bhat AR, Zarger J, *et al.* Delayed posttraumatic intraventricular tension pneumocephalus: A case report. *Neurosurgery Quarterly* 2011 May; 21(2): 128-132.
2. Komolafe EO, Faniran EA. Tension pneumocephalus - a rare but treatable cause of rapid neurological deterioration in traumatic brain injury. *African Journal of Neurological Sciences* 2010; 29 (2).
3. Webber-Jones JE. Tension pneumocephalus. *Journal of Neuroscience Nursing* 2005 Oct; 37 (5).
4. Edwin KC, Lawrence ZM. Otogenic pneumocephalus caused by therapeutic lumbar CSF drainage for post traumatic hydrocephalus: a case report. *Ear, Nose and Throat Journal* 2007 July.
5. Ross AC, Lawrence JM, Ramon ME, Gregory TW, Donald AR. Incidence and management of tension pneumocephalus after anterior craniofacial resection: case reports and review of the literature. *Otolaryngol Head Neck Surg* 1999 April; 120(4): 579-580.
6. Lunsford LD, Maroon JC, Sheptak PE, Albin MS. Subdural tension pneumocephalus. Report of two cases. *J Neurosurg* 1979 April; 50(4): 525-527.
7. Ishiwata Y, Fujitsu K, Sekino T, Fujino H, Kubokura T, Tsubone K, *et al.* Subdural tension pneumocephalus following surgery for chronic subdural haematoma. *J Neurosurg* 1988 Jan; 68(1):58-61.
8. Little JR, MacCarty CS. Tension pneumocephalus after insertion of ventriculoperitoneal shunt for aqueductal stenosis. *J Neurosurg* 1976 March; 44(3):383-385.
9. Toung T, Donham RT, Lehner A, Alano J, Campbell J. Tension pneumocephalus after posterior fossa craniotomy: report of four additional cases and review of postoperative pneumocephalus. *Neurosurgery* 1983 Feb; 12(2):164-168.
10. Stuedel WI, Hacker H. Prognosis, incidence and management of acute traumatic intracranial pneumocephalus. A retrospective analysis of 49 cases. *Acta Neurochir* 1986; 80(3-4):93-99.
11. Odebode OT, Dunmade AO, Afolabi OA, Suleiman OA. Lateral skull radiograph in a patient with post-traumatic tension pneumocephalus complicated by late epilepsy. *Emergency Medicine Journal* 2008; 25:32.
12. Zasler N. Posttraumatic tension pneumocephalus. *Journal of Head Trauma Rehabilitation* 1999 Feb; 14 (1): 81-84.
13. Antonio LA, Norbeto M, Elena R. Post-traumatic pneumocephalus. *Int J Emerg Med* 2009 June; 2(2):129-130.
14. John EM, Octavio C, Ashmit G, Ayal W. Treatment of post-craniotomy tension pneumocephalus via endoscopic closure of the nasofrontal recess. *Skull Base Surgery* 1998; 8(4):221-224.
15. Behzad E, Mohammad G, Azar H, Mousa T, Samira ZS, Vafa R, *et al.* prophylactic antibiotic for prevention of post-traumatic meningitis after traumatic pneumocephalus: design and rationale of a placebo controlled randomized multicentre trial [ISRCTN71132784]. *Trials*. 2006 January 18 (Cited 2012 May 29); 7:2. Available from <http://www.trialsjournal.com/content/7/1/2>.