

## Clinical Response To Pericardiectomy At UNTH, Enugu Nigeria

By

EZE J C<sup>1</sup> and UGWUANYI UPC<sup>2</sup>

<sup>1</sup>*Cardiothoracic Unit, Department Of Surgery, University Of Nigeria Teaching Hospital, Enugu.*

<sup>2</sup>*Dept Of Surgery, National Hospital, Abuja*

### SUMMARY

**Objective:** Pericardiectomy as a means of surgical treatment is a standard procedure to improve the quality of life for patients with features of cardiac restriction. The aim of the study was to review the clinical response to pericardiectomy.

**Methods:** A retrospective study of patients who had pericardiectomy between May 1995 and April 2000 was done. Records of relevant clinical features of the disorder necessitating pericardiectomy; diagnostic and prognostic investigations conducted were extracted from the case records.

**Results:** A total of 36 patients were identified in the register as having had pericardiectomy in the period of review but only 21 (58.3%) case records were found. The clinical features noted were mainly of shortness of breath, abdominal, facial and feet swelling, ascites, low pulse pressure and tender hepatomegaly. There were pericardial effusion in 12(57%) and constrictive pericarditis 9 (42.9%) of the patients respectively. Sixteen patients (76.2%) had left anterolateral thoracotomy approach while 5 patients (23.8%) had sternotomy approach. Operative findings included thickened pericardium with or without effusion, pyopericardium, haemopericardium and calcified pericardium. Four months post surgery 14 patients (66.7%) had good clinical response while 4 patients (19%) had not responded favorably. Five patients (23.8%) were lost to follow-up after discharge.

**Conclusion:** Pericardiectomy is beneficial to patients who have constrictive pericarditis. Poverty is alimitation to uptake of pericardiectomy.

---

**Key Words:** *Constrictive Pericarditis; Pericardiectomy; Clinical Response*

### INTRODUCTION

That pericardiectomy is a rational procedure to relieve cardiac restriction cannot be over emphasized. Cardiac restriction may result from cardiac tamponade, subacute or chronic pericarditis. The severity of symptoms varies in relation to the aetiology of the restriction. The central venous pressure is raised and the liver becomes congested. Peripheral edema and ascites are also features<sup>1</sup>.

The clinical features often encountered include shortness of breath, abdominal pain, feet swelling, ascites, low pulse pressure and tender hepatomegaly. Cardiac restriction resulting from chronic pericarditis cause symptoms of relatively long duration. Raised JVP is augmented on inspiration (Kaussmaul sign), because of increased venous pressure<sup>1</sup>.

Establishing the diagnosis may not be easy because the chest radiography and echocardiography may show normal patterns. However cardiac catheterization demonstrates a reversed square root sign<sup>2</sup>.

Most patients, irrespective of the cause of cardiac restriction, benefit from pericardiectomy. Different surgical routes are applied for pericardiectomy. These include left anterolateral, median sternotomy and sub-xiphoid approaches<sup>3</sup>. This study aims at appraising the current clinical outcome of pericardiectomy as practiced at the University of Nigeria Teaching Hospital, Enugu.

### MATERIALS AND METHODS

A retrospective study of patients who had pericardiectomy between May 1995 to April 2000 at UNTH, Enugu was done. Their names

### Correspondence Author:

*Dr J.C. Eze, Dept. of Surgery*

*UNTH, Enugu, Nigeria.*

*E-mail: ezejc@mail.com*

*Accepted for Publication: 9<sup>th</sup> December 2002*

and hospital numbers were obtained from the surgical register. Thereafter, the case notes were traced from the Records Department.

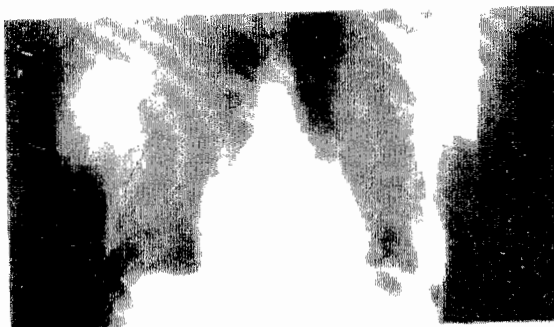
To undergo this procedure, the clinical diagnosis was usually made by a doctor whose rank was not below senior resident, and substantiated by radiological findings. Data extracted from the records included age, sex, operative procedure and findings, post operative clinical review and histology. This study was limited only to those patients who had clear clinical and radiological features of cardiac restriction and who were in New York Heart Association (NYHA) functional class III or IV before the surgery.

## RESULTS:

A total of 36 cases were identified from the surgical register, but only 21(58.7%) case notes could be traced from the records. Male: Female ratio was 13:8. Age range was from under 1 – 50 years; but the peak incidence is between 21 – 35 years followed by 36 – 50 years.

Symptoms and signs at presentation include cough 7(33.3%), dyspnoea 12(57.1%) edema of face/feet 12(57.1%), ascites 9(42.9%), raised JVP 6(28.97%), hepatomegaly 9(42.9%), fever 3 (14.3%), and low pulse pressure 14 (66.7%).

Diagnostic investigations done include chest x-ray in all 21patients (100%), two dimensional echocardiography (2-D-Echo) in 11patients (52.4%) and cardiac ultrasound in 4 patients (19%). The 2-D-Echo and ultrasonography reports indicated that pericardial effusion was commoner than constrictive pericarditis (figure 1).



*Fig 1: Plain CXR – PA view showing the constricted heart*

Indications for pericardiectomy based on diagnostic investigations were constrictive pericarditis with or without pericardial effusion. The commonest surgical route was left anterolateral thoracotomy 16 patients (72.7%), followed by median sternotomy in 5 patients (22.8%) and trans-sternotomy (bilateral thoracotomy) in 1patient (14.5%).

The type of pericardiectomy done was partial pericardiectomy in 16 (76.2%) or total pericardiectomy in 5(23.8%) patients respectively.

The operative findings included thickened pericardium in 20 patients (95.2%) and calcified pericardium in 1patient (4.8%). Figure 2 is a chest x-ray of one of the patients who had calcified pericardium. There was no associated effusion in 12 patients (57.1%), while there were haemopericardium in 4 patients (33.3%), and plain effusion in 5 patients (41.7%). Histology reports were obtained in only 5 cases (23.8%) as patients were given the specimens to send to the pathologist, and had to pay directly for histology services.



*Fig. 2: Calcified Pericardium.*

Pericardiectomy was often followed by a re-expansion of the cardiac silhouette and or disappearance of calcific shadows on repeat chest x-ray (figure 3 and 4). Not all the patients

responded well to pericardiectomy. Two out of every three (66.7%) had good response subjectively after 4 months; 5 (23.8%) had poor response while 2 (9.5%) had borderline response.

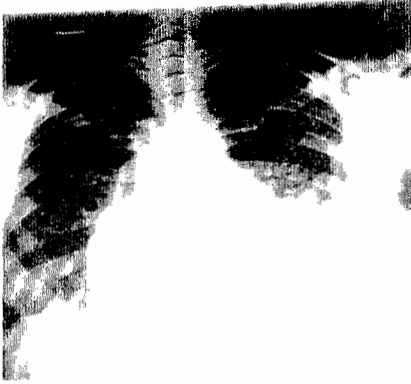

Fig. 3: Repeat CXR of patient in figure 1 post operatively showing enlarged cardiac silhouette.

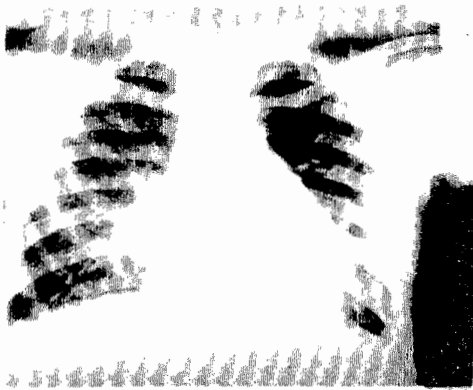


Fig. 4: Same as in fig 2 after removal of calcification

## DISCUSSION

As a known drawback of retrospective studies just a little above half of all the records of the cases treated in this period were traceable for this study. This reflects the deplorable state of our record system. Lack of computerization and adequate staff training may contribute to this. It may also be due to the depressed economy. This is in sharp contrast to what obtains elsewhere as reported by DeValeria et al<sup>3</sup>.

Males are more commonly affected than females and any age can be affected. It is commoner in the third and fourth decades. Earlier study from this center showed 50% of patients to be in the second or third decade of life<sup>4</sup>. Changing pattern of aetiology can explain the disparity.

Cough and breathlessness are usually due to attendant pulmonary congestion. Increase in both the superior vena caval and inferior vena caval pressure is responsible for raised jugular venous pressure (JVP), ascites, pedal edema and hepatomegaly. Reduced end diastolic volume and consequently low stroke volume is responsible for the low pulse pressure and compensatory increased pulse rate<sup>1,2</sup>.

All the patients had chest x-ray because it is cheap and easily accessible. A few had 2D – Echo and cardiac ultrasonography which are more expensive and not readily available. The latter, however, have higher diagnostic values although not without false negatives. In instances where false negative results are suspected from the clinical symptoms, cardiac catheterization should be sought.

In this study, although the 2-D-Echo and cardiac ultrasound indicated that effusion was commoner than constrictive pericarditis, the findings at operation revealed mostly thickened pericardium. This could be due to observer error in interpreting the echo result or transformation of the clinical situation between the time of investigation and the actual surgery. Delay in treatment is very common as many of our patients are also under the general prevailing depressed national economy. These facilities are no longer taken for granted in this center as was earlier reported<sup>4</sup>.

For limited pericardiectomy, (L) anterolateral thoracotomy approach is faster, cheaper, less traumatic with good response. Post operative recovery is smoother than in total pericardiectomy which is technically more difficult with turbulent post-operative period. It is carried out through a median sternotomy or trans-sternotomy<sup>3,4</sup>.

We still make use of scissors for the calcified pericardium despite the dangers. Calcified pericardium is particularly difficult but Oku et al<sup>5</sup> have started using a drill in removing the calcification. Total pericardiectomy via median sternotomy involves stripping from one phrenic nerve to the other, surface of diaphragm, inlet and outlet flow tracts (SVC, IVC). The depth of decortication must be adequate. Failure of surgery may be due to failure to remove a

constricting epicardial peel. Nevertheless, surgery to remove epicardial peel carries an increased risk of disrupting the coronary vessels, especially in cases where there is no definite plane between the 2 layers of pericardium<sup>6</sup>. Retention of constrictive epicardial peel makes the procedure incomplete, and is occasionally responsible for post operative low out-put state.

Response to pericardiectomy may be immediate or delayed. Wolozin et al<sup>7</sup> studied Atrial Natriuretic Factor release and immediate response that is beneficial to patient. Myocardial atrophy might also cause post operative low out-put state due to progressive deterioration of cardiac function<sup>6</sup>. It may also be from other causes such as worsening intra cardiac lesion as reported by Johnson et al<sup>8</sup>.

Initially, the hospital was processing the histology specimens ahead of bills but no more these days. Many of the patients did not see the need to spend more money. Consequently, they discarded the specimens when give to them to dispatch to pathologists privately. This attitude may also be attributed to the deleterious effect of the depressed economy. Whatever the case, it made histological diagnosis unavailable for this review.

## CONCLUSION

It is obvious that more patients could have benefited from this surgical procedure but for financial constraint. The National Health Insurance Scheme (NHIS) may help. In addition, proper funding and maintenance of high-tech diagnostic and surgical equipments would help many more patients benefit from this procedure.

## ACKNOWLEDGMENT

Our gratitude goes to Professor M.A.C. Aghaji who participated actively in the management of these patients. Also being appreciated are other teams of doctors and records department who assisted us. Finally, we are grateful to Sister Ngozi Okoro who did the secretarial work.

## REFERENCES

1. Shabetal R, Fowler N.O, Guntheroth W.G; The Hemodynamics of Cardiac Tamponade and Constrictive Pericarditis Am. J. of Cardiology 1970; 26: 480 - 489.
2. Mann CV, Russel RCG and Williams SN. The Pericardium. In Rains AJ and Ritchie HD (eds), Bailey and Love's Short Practice of Surgery. 22nd Edition London, 1999: 620 – 621.
3. DeValeria PA, et al. Current Indications, Risks, and Outcome after Pericardiectomy. Ann Thorac. Surg Aug 1991; 52(2): 219 - 224
4. Anyanwu CH and Umeh BUO. Pericarditis: a persisting surgical problem. Cardiovascular Surgery 1994; 2 (6): 711 – 714.
5. Oku T. et al. Easy Dissection of Hard and Thickened Pericardium on Constrictive Pericarditis. Ann Thorac Surg 1990; 50 (6): 998 – 999.
6. Parry AJ and Pillai R. Pericardial disease. In Morris PJ and Malt RA (eds) Oxford Textbook of Surgery Vol. 2 1st Edition. Oxford Medical Publications 1994: 1851 – 1852.
7. Wolozin et al. Release of Atrial Natriuretic Factor after Pericardiectomy for Chronic Constrictive Pericarditis. Am J. of Cardiol. 1988; 62: 1323 – 1325.
8. Johnson TL, Bauman WB and Josephson RA. Worsening Tricuspid Regurgitation Following Pericardiectomy for Constrictive Pericarditis. Chest 1993 July; 104 (1): 79 - 81.