

Surgical Management of a Case of Debilitating Multiple Joint Osteoarthritis [MJOA] Co-Existing with Degenerative Disease of the Spine in an Elderly Patient

Ifeanyi C NWAGBARA

ABSTRACT

The management of multiple joint osteoarthritis is a challenging ordeal especially in the Low- and Middle- income Countries where most victims present late as a result of poverty and ignorance. This is particularly so in the elderly patients with the added problems of osteoporosis, increased risk of deep venous thrombosis and co- morbidities. We have discussed our experience in the management of an elderly patient who presented with incapacitating osteoarthritis of both knees and right hip with associated spine disease and who was bed ridden for two years prior to presentation. Debilitating Polyarthritis, Multiple joint replacements, Surgery in the elderly, distal femoral replacement.

INTRODUCTION.

Osteoarthritis is a polymorphic disease with a variety of clinical presentations which makes a definition of the condition difficult, but it can be described as “a heterogeneous group of conditions that leads to joint symptoms and signs which are associated with defective integrity of articular cartilage, in addition to related changes in the underlying bone and at the joint margins”.¹ Osteoarthritis (OA) ranks globally among the 50 most common sequelae of diseases and injuries, affecting over 250 million people or 4% of the world's population.²

Multiple joint osteoarthritis [MJOA] as defined by various authors refers to the presence of osteoarthritis in two or more joints at once and is not joint specific.³ The affected sites include the hands, hips, knees and spine. An increased number of OA affected joint sites correlates with increased risk of disabling disease, defined as OA with pain interfering with an individual's normal work.⁴ In an observational study by Carlesso (n=2,455), odds of frailty and pre-frailty increased as number of joint sites with OA increased.⁵ Treatment of osteoarthritis is individualized. Co-morbid conditions such as cardiac disease, hypertension, peptic ulcer disease, or renal disease must be considered, and the patient's needs and expectations should also be taken into account.⁶ Total joint arthroplasty (replacement) surgery is the gold standard treatment in patients with severe end-stage symptomatic osteoarthritis who have failed to respond to non-pharmacologic and pharmacologic management, and who have significant impairment in their quality of life due

OPEN ACCESS

Affiliation

Orthopaedic Surgery Unit,
Department of Surgery, Imo State
University Teaching Hospital,
Orlu, Imo State.

*Correspondence

Ifeanyi C NWAGBARA
Orthopaedic Surgery Unit,
Department of Surgery, Imo State
University Teaching Hospital,
Orlu, Imo State.

Tel: +2348033388292

Email: icnwagbara@gmail.com

Article Metrics

Submitted: 22 April 2023

Accepted: 27 May 2023

Published: Jan-June 2024

Journal Metrics

p- ISSN: 1115-0521

e-ISSN: 3027-2890

Website: www.orientjom.org.ng

E-mail: editorojm@gmail.com

Publisher

cPrint, Nig. Ltd

E-mail:

cprintpublisher@gmail.com



Access to the article

Website: <http://www.orientjom.org.ng>

DOI: 10

How to cite this article

Nwagbara I.C. Surgical Management of a Case of Debilitating Multiple Joint Osteoarthritis [MJOA] Co-Existing with Degenerative Disease of the Spine in an Elderly Patient. *Orient J Med*, 2024;36(1-2):61-66. DOI: 10

to OA.⁷ It provides marked pain relief and functional improvement in patients with severe hip or knee OA.^{8,9,10} The management of MJOA can be quite challenging especially in the developing world where most patients present late with grossly deformed joints.

We present our experience in the management of an elderly lady with incapacitating multiple joint osteoarthritis associated with hypertension, peptic ulcer disease and osteoporosis and who had been bed ridden for 2 years before presentation.

CASE PRESENTATION

Mrs OE, a 78 years old lady was admitted on 1/09/22 on account of incapacitating bilateral knee pain and stiffness with associated right hip pain and stiffness of about 7 years duration. The pain and deformities were progressive with inability to bear weight in the preceding two years during which period she had been bed-ridden because of excruciating pain and deformities. There were associated low backache with radiation to the right lower limb, numbness, paraesthesia and weakness of the right lower limb. There was also associated neck pain with radiation to both upper limbs, and equally numbness and paraesthesia of both upper limbs. There were underlying history of hypertension and peptic ulcer disease.

On examination, she was in severe painful distress and on wheelchair. Examination of the spine revealed no deformity nor areas of localized tenderness. There were flexion deformities of the right hip and both knees with associated severe tenderness. The range of motion of the knees was 30 to 90 degrees while the right hip was in 60 degrees of flexion. There were normal tone and reflexes across the knees while there were hypotonia and hyporeflexia across the right ankle. There was also sensory deficit on the L3-S1 dermatomes on the right. There was marked reduction in the range of motion of both shoulders but no neurological deficits in the upper limbs.

Radiological examination showed features of severe osteoarthritis of both knees and the right hip with associated marked generalized osteoporosis and

multilevel cervical spine osteophyte formation. [Fig 1, 2] Lumbosacral MRI showed multilevel [L1-S1] disc bulges, marked bilateral L4-S1 exit nerve roots canal stenosis, marked bilateral L4/L5 + right L5/S1 foraminal stenosis, generalized osteoporosis with osteoporotic fracture of L1 inferior end-plate and focal hyperintense lesion at L4 superior end-plate suggestive of a metastatic lesion.

She was subsequently optimised for surgery and had 2 sessions of manipulation under anaesthesia and casting of both lower limbs at two weeks interval to correct the hip and knee flexion deformities. After which she was commenced on physiotherapy. Full correction was achieved after 5 weeks of the treatment protocol.

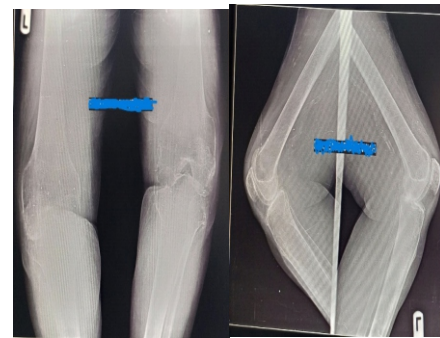


Figure 1. Pre-operative anterior-posterior and lateral x-ray films of both knees.

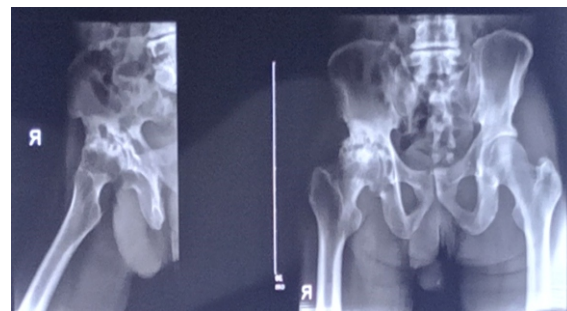


Figure 2. Pre-operative anterior-posterior x-ray film of the pelvis and lateral x-ray film of the right hip

She had combined total right hip replacement and total left knee replacement on 22/10/22 [Figures 3 & 4]. She later had total right knee replacement 8 weeks after. She reportedly had a fall in her room around 3am, 13 days after the last procedure while alone with her husband

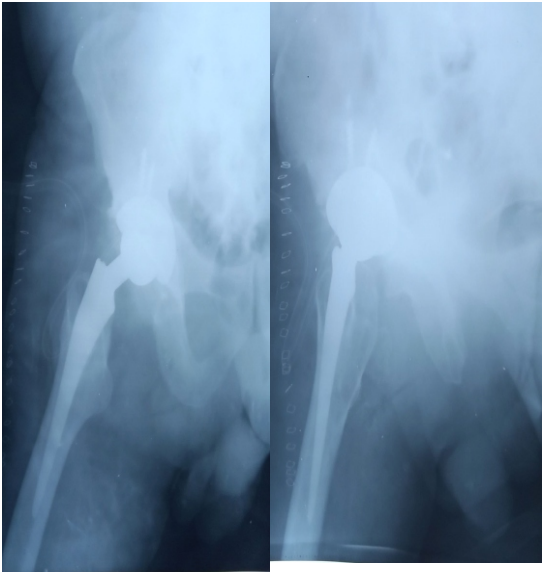


Figure 3. Post-operative Anterior-posterior and lateral x-ray films of the right hip.

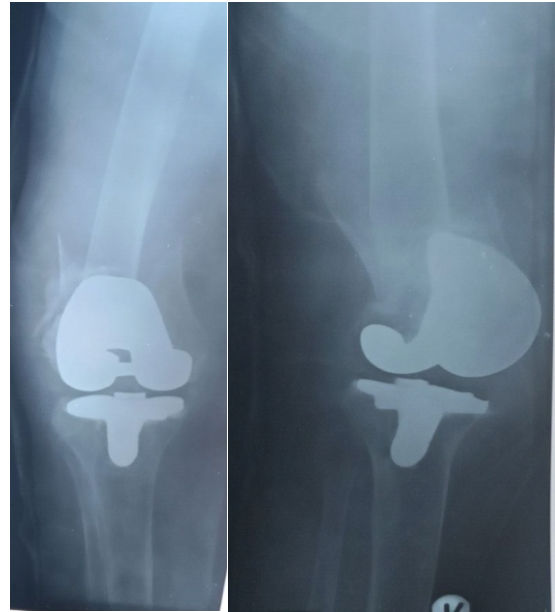

Figure 5. Anterior- posterior and Lat x-ray views of the right knee showing the peri- prosthetic fracture

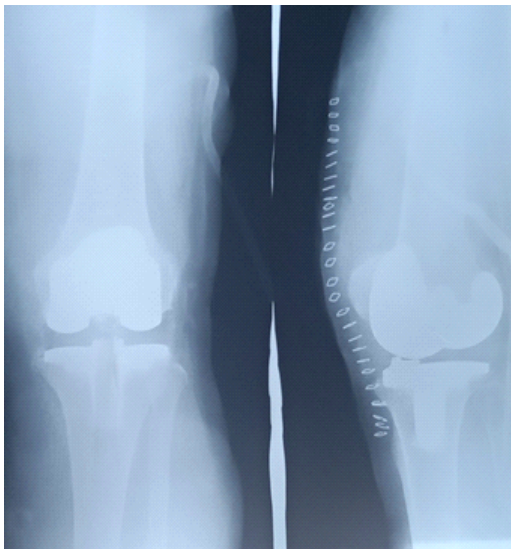

Figure 4. Post-operative Anterior-posterior and lateral x-ray films of the left knee.

after which she developed severe pain around the right knee. Subsequent x-ray revealed a peri-prosthetic, osteoporotic [pathological] fracture of the right distal femur [Figure 5]. A cast was applied to stabilize the fracture and she was worked up for a revision surgery

She subsequently had distal femoral replacement, 8 weeks after the fall. [Figure 6]

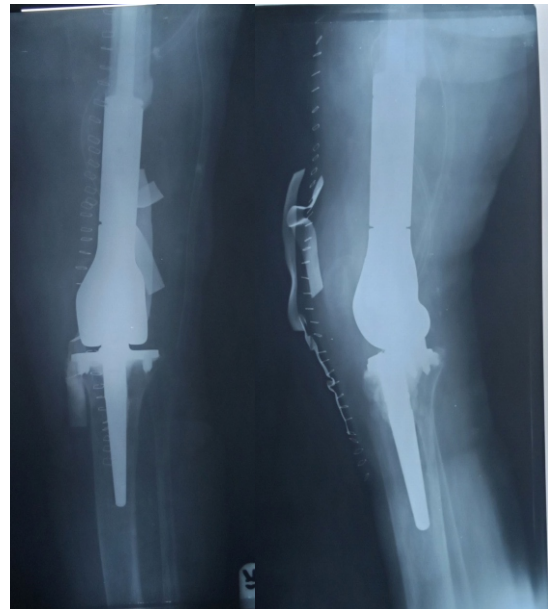

Figure 6. Anterior- posterior and lateral x-ray views of the right knee following the distal femoral replacement

The patient was on anticoagulant therapy, chest physiotherapy and muscle strengthening exercises all through the period of admission and was sleeping on an air mattress to prevent decubitus ulcers.

The pain and deformities of the right hip and both knees were corrected as at the time of discharge after 39 weeks of admission. The right lower limb weakness, however prevented weight bearing mobilization. So, she was discharged on a wheel chair and was to continue physiotherapy in the outpatient department pending when she will be re-admitted for a spinal procedure.

DISCUSSION

The management of MJOA can be quite challenging especially in the Low- and Middle- income Countries (LMIC) where most patients present late on account of poverty and ignorance. The hospital bill in the management of this condition is quite high and only very few can afford that in our environment where most patients pay out of pocket for their healthcare services. Even among the lucky few who have insurance cover as in our index case, ignorance and local practices delay treatment significantly such that most of the patients end up presenting very late. Our index patient who is a retired registered nurse was offered surgery some 5 years before presentation but she declined and instead resorted to native massage and analgesics. She accepted physiotherapy in the referral hospital when she became incapacitated, which however did not improve her lot.

The first challenge we had to deal with was taking a decision of whether to handle the spine disease first or hip and knee deformities. In patients with such symptoms from hip and spine, there has been no clear-cut consensus among spine and arthroplasty surgeons on the order of treatment but priority of treatment is generally determined by the severity and location of symptoms, activities of daily living, and the preference of the patient.^{11,12} Our decision on this was based on the severity of the hip and knee symptoms, the difficulty of positioning of patient for

spinal decompression in view of the severe hip and knee flexion deformities and patient's preference.

The next decision was on how to mobilize the joints in the presence of the severe flexion deformities. Complete correction of severe flexion deformities at the time of knee replacement remains challenging and technically demanding. Although total knee arthroplasty (TKA) can be performed in this challenging patient intraoperative correction of severe flexion deformity present a difficult situation for orthopaedic surgeons.^{13,14,15} and incomplete intraoperative correction would lead to more residual flexion contracture postoperatively.¹⁶ We, therefore had to place the index patient on serial manipulations under anaesthesia and cylinder cast application. This proved effective and required two sessions to correct the flexion deformities.

The severe osteoporosis in the patient was a major cause of concern as the risk of iatrogenic fractures during the procedures was high. Utmost care was therefore observed during the period of manipulation under anaesthesia, casting and joint mobilization during the arthroplasties. She was equally placed on muscle strengthening and chest physiotherapy throughout the period of admission. Supplemental vitamin D and bisphosphonate therapy were also commenced early following admission. Despite the fracture preventive measures adopted, she developed a severe comminuted peri-prosthetic fracture of the right distal femur following a minor fall in her room. She reportedly had a fall while getting off her bed unassisted. The fracture was so severe that it required a distal femoral replacement procedure.

We also had to deal with the risk of venous thromboembolism (VTE) in the index case. She was a high- risk case considering her age, the prolonged period of immobilization before admission and during the hospital stay and the number of procedures that were carried out. VTE can be a devastating complication in joint replacement surgery, with more than one in 1000 people suffering from this disease annually.¹⁷ Thus, she was placed on rivaroxaban, a

direct oral anticoagulant (DOAC) throughout the period of her admission. The use of anticoagulants in total hip and knee replacements is however not without some draw backs. There is proof in existing studies that when rivaroxaban is used in total knee and hip replacement surgeries, the incidence of venous thromboembolism is lower than that of other anticoagulants, but the bleeding rate is relatively high.¹⁸ This topic remains controversial as some studies have shown that rivaroxaban is effective in the prevention of deep vein thromboembolism with a very low bleeding rate.^{19,20} We stopped the medication 72 hours before each procedure and recommenced it 12 hours after. It is recommended that rivaroxaban should be commenced 8 to 10 hours after the procedure.²¹ We however encountered the complication of increased haemorrhage and haematoma formation after the first set of procedures. This required intra-operative haematoma evacuation and wash-out of the right hip and left knee after 8 days of the joint replacement procedures. The procedure was well tolerated and the wounds healed satisfactorily.

In conclusion, the management of MJOA in the elderly patients is quite difficult especially in our environment where most patients present very late. The challenges encountered include correction of accompanying severe flexion deformities, prevention of iatrogenic fractures due to the associated severe osteoporosis and prevention of venous thromboembolism in these high- risk elderly patients.

REFERENCES

- Altman R, Asch E, Bloch D, Bole G, Borenstein D, Brandt K et al. Development of criteria for the classification and reporting of osteoarthritis. Classification of osteoarthritis of the knee. Diagnostic and Therapeutic Criteria Committee of the American Rheumatism Association. *Arthritis Rheum* 1986;29:1039–1049. doi: 10.1002/art.1780290816.
- Vos T, Flaxman AD, Naghavi M, Lozano R, Michaud C, Ezzati M et al. Years lived with disability (YLDs) for 1160 sequelae of 289 diseases and injuries 1990–2010: a systematic analysis for the Global Burden of Disease Study 2010. *Lancet* 2012;380:2163–2196.
- Gullo TR, Golightly YM, Cleveland RJ, Renner JB, Callahan LF, Jordan VB et al. Defining multiple joint osteoarthritis, its frequency and impact in a community-based cohort. *Semin Arthritis Rheum* 2019 Jun;48(6):950-957. doi: 10.1016/j.semarthrit.2018.10.001. Epub 2018 Oct 9. PMID: 30390991; PMCID: PMC6456431.
- Thomas E, Peat G, Croft P: Defining and mapping the person with osteoarthritis for population studies and public health. *Rheumatology (Oxford)* 2014, 53(2):338–345.
- Carlesso LC, Hawker GA, Waugh EJ, Davis AM. Disease-specific pain and function predict future pain impact in hip and knee osteoarthritis. *Clin Rheumatol* 2016, 35(12):2999–3005.
- Manek N J, Lane NE: Osteoarthritis: Current Concepts in Diagnosis and Management. *Am Fam Physician* 2000;61(6):1795-1804
- Mandi LA. Determining who should be referred for total hip and knee replacement. *Nat Rev Rheumatol* 2013; 9:351.
- Bulkwater JA, Lohmander S. Operative treatment of osteoarthrosis. Current practice and future development. *J Bone Joint Surg Am* 1994; 76: 1405
- Hochberg MC, Altman RD, Brandt KD, Clark BM, Dieppe PA, Griffin MR, et al. Guidelines for the medical management of osteoarthritis. Part II. Osteoarthritis of the knee. American College of Rheumatology. *Arthritis Rheum* 1995;38: 1541
- Skou ST, Roos EM, Laursen MB, Rathleff MS, Arendt-Nielsen L, Simonsen O, et al. A randomised, controlled trial of total knee replacement. *N Engl J Med* 2015; 373:1597.
- Liu N, Goodman SB, Lachiewicz PF, Wood KB. Hip or spine surgery first?: a survey of treatment order for patients with concurrent degenerative hip and spinal disorders. *Bone Joint J* 2019 Jun;101-B(6_Supple_B):37-44.

12. Grammatopoulos G, Dhaliwal K, Pradhan R, Parker SJM, Lynch K, Marshall R, et al. Does lumbar arthrodesis compromise outcome of total hip arthroplasty? *Hip Int* 2019 ;29(5):496-503.
13. Tew M, Forster IW: Effect of knee replacement on flexion deformity. *J Bone Joint Surg Br* 1987;69(3): 395-399.
14. Firestone TP, Krackow KA, Davis JD, Teeny SM, Hungerford DS. The management of fixed flexion contractures during total knee arthroplasty. *Clin Orthop Relat Res* 1992; 284: 221-227.
15. McGrath MS, Mont MA, Siddiqui JA, Barker E, Bhav A. Evaluation of a custom device for the treatment of flexion contractures after total knee arthroplasty. *Clin Orthop Relat Res* 2009; 467 (6): 1485-1492.10.1007/s11999-009-0804-z.DOI.
16. Sarokhan AJ, Scott RD, Thomas WH, Sledge CB, Ewald FC, Cloos DW. Total knee arthroplasty in juvenile rheumatoid arthritis. *J Bone Joint Surg Am* 1983; 65 (8): 1071-1080
17. Lassen MR, Raskob GE, Gallus A, Pineo G, Ghen D, Hornick P, et al. Apixaban versus enoxaparin for thromboprophylaxis after knee replacement (ADVANCE-2): a randomised double-blind trial. *Lancet* (London, England) 2010 ;375(9717):807-815.
18. Cohen AT, Boyd RA, Mandema JW, Dicarolo L, Pak R; A5571010 Investigators. An adaptive-design dose-ranging study of PD 0348292, an oral factor Xa inhibitor, for thromboprophylaxis after total knee replacement surgery. *J Thromb Haemost* 2013 ;11(8):1503-10. doi: 10.1111/jth.12328. Erratum in: *J Thromb Haemost*. 2018 Dec;16(12):2541. PMID: 23782955.
19. Eriksson BI, Turpie AG, Lassen MR, Prins MH, Agnelli G, Kälebo P, et al; ONYX-2 STUDY GROUP. Prevention of venous thromboembolism with an oral factor Xa inhibitor, YM150, after total hip arthroplasty. A dose finding study (ONYX-2). *J Thromb Haemost*. 2010 Apr;8(4):714-21. doi: 10.1111/j.1538-7836.2010.03748.x. Epub 2010 Jan 17. PMID: 20088935.
20. Turpie AG, Lassen MR, Davidson BL, Bauer KA, Gent M, Kwong LM, et al; RECORD4 Investigators. Rivaroxaban versus enoxaparin for thromboprophylaxis after total knee arthroplasty (RECORD4): a randomised trial. *Lancet* 2009 ;373(9676):1673-80.
21. Loganathan V, Hua A, Patel S, Gibbons C, Vizcaychipi MP. Efficacy and safety of rivaroxaban thromboprophylaxis after arthroplasty of the hip or knee: retrospective cohort study. *Ann R Coll Surg Engl* 2016 ;98(7):507-515.