

Synopsis of Holmium: Yttrium-Aluminum-Garnet Laser used with Flexible Ureteroscopy in the Treatment Renal Stones

Idorenyin C. AKPAYAK

ABSTRACT

Laser lithotripter is by far the most commonly used intracorporeal lithotripter. Despite the recent exciting in-roads made by the thulium fibre laser (TFL), currently, the holmium: yttrium-aluminium-garnet (Ho:YAG) laser is the lithotripter of choice for the treatment of urinary stones. This article aims to provide a concise review of the Ho:YAG laser used with flexible ureteroscopy for the treatment of renal stones. The review examines the technical aspects, the laser fibre, the setting and efficiency of Ho:YAG laser. This is a narrative review of the Ho:YAG laser used with flexible ureteroscopy in the treatment of renal stones. The relevant databases and journals in urology were searched for contemporary existing literature on the subject. The literature on the physics, the anatomy of the Ho:YAG fibre, the setting and efficiency of the Ho:YAG laser were reviewed. The safety of the Ho:YAG laser in the treatment of renal stones was also reviewed. Understanding the physics of Ho:YAG laser, proper choice of laser fibres and appropriate setting of the laser machine are essential for its optimal use in flexible ureteroscopy for renal stone

Keywords: Ho:YAG laser, Flexible ureteroscopy, Renal stones.

INTRODUCTION

Urinary stones affect 8 – 15% of the world population.^{1,2} In Nigeria, earlier reports suggested that urinary stones were rare.^{3,4} Contemporary reports have however, shown that the incidence is rising.^{5,6,7} While open surgery was the main option of treatment in the past decades, recently, minimally invasive techniques have revolutionized urinary stone treatment.⁸

The staggering advances in the manufacture of flexible ureteroscopes and laser technology have had the greatest impact in the minimally invasive treatment of renal urinary stones globally.⁹ The miniaturization of the flexible scopes; improvement in the optics and the scope deflection mechanism as well as the refinement of accessory instrumentation have combined to facilitate access to the entire urinary tract.^{9,10}

Also, the miniaturization of the charge couple device (CCD) and the complementary metal oxide (CMOS) have made the birth of digital flexible ureteroscope possible. These chips are now small enough to allow the

OPEN ACCESS

Affiliation

Division of Urology, Surgery
Department, Jos University
Teaching Hospital, Jos

*Correspondence

Prof. Idorenyin C. Akpayak
Division of Urology, Surgery
Department, Jos University
Teaching Hospital, Jos,
Nigeria.

Tel: +2347032125825

Email: akpayakuro@yahoo.com

Article Metrics

Submitted: 28 December 2022

Accepted: 27 February 2023

Published: July-Dec. 2023

Journal Metrics

p- ISSN: 1115-0521

e-ISSN: 3027-2890

Website: www.orientjom.org.ng

E-mail: editorojm@gmail.com

Publisher

cPrint, Nig. Ltd

E-mail: cprintpublisher@gmail.com



Access to the article

Website: <http://www.orientjom.org.ng>

DOI: 10.5281/zenodo.7896099

How to cite this article

Akpayak C. I. Synopsis of Holmium: Yttrium-Aluminum-Garnet Laser used with Flexible Ureteroscopy in the Treatment Renal Stones. *Orient J Med*, 2023;35(3-4):1-10. DOI: 10.5281/zenodo.7896099

incorporation at the tip of the flexible scope, creating the chip on the stick scope. This effectively eliminates the need for optic fibre thereby giving rise to a more robust deflection mechanism and by extension more durable scopes^[11,12].

The images obtained with a digital scope are generally larger and clearer than those obtained with the traditional fiberoptic ureteroscopes. In addition, the honeycomb pattern (Moiré effect) seen with the fiberoptic scopes is eliminated.¹³

Different intracorporeal lithotripter devices are available for stone fragmentation including, the electrohydraulic (EHL), pneumatic and ultrasonic lithotripters as well as laser lithotripter.¹⁴ Laser lithotripter is by far the most commonly used intracorporeal lithotripter, especially in the developed countries.^{15,16} Despite the recent exciting in-roads made by the thulium fibre laser (TFL), currently, the holmium: yttrium-aluminium-garnet (Ho:YAG) laser is the lithotripter of choice for the treatment of urinary stones.^{16,17} This article aims to provide a concise review of the Ho:YAG laser used with flexible ureteroscopy for the treatment of renal stones. The review examines the technical aspects, the laser fibre, the setting and efficiency of Ho:YAG laser.

METHODS

This was a narrative review of the Ho:YAG laser used with flexible Ureteroscopy for the treatment of renal stones. The data base were searched for recent information on the relevant physics, the anatomy of Ho:YAG fibre, the setting and efficiency of the Ho:YAG laser. The data base searched were MEDLINE, Excerpta Medica Database (EMBASE), Google scholar, individual urology and endourology journals. The search terms included, "Holmium:YAG laser lithotripsy", "renal stones", "flexible ureteroscopy", "laser fibres", "laser setting", urinary stone dusting", 'urinary stone fragmentation", "intracorporeal laser lithotripsy". The search was limited to English language articles from 1995 -2020. However, few key publications considered noteworthy and historical, published

earlier than 1995 on the subject were included and referenced. A total of 1,950 articles were obtained from the search of the data bases. Only studies and articles that focused on the technical aspects, setting, efficiency and safety of the Ho:YAG laser were included. Articles not relevant with respect to itemised points were excluded from the study.

Holmium- Yttrium-Aluminium-Garnet Laser Physics

Holmium is a rare-earth metal with 67 protons in its nucleus predominantly found as trivalent ions in nature.¹⁸The yttrium-aluminum-garnet (YAG) crystal is chemically doped with the holmium ions within the optical cavity of the laser machine.¹⁹ The photons emitted by the energized Ho:YAG crystals travel freely within the optical cavity and are reflected by mirrors at each end of the cavity. A small opening in the optical cavity allows the laser energy to exit the cavity usually in pulses when needed.^{19,20} (see generated annotated **Figures 1,2 and 3**). The Ho:YAG laser delivers pulsed energy at a wavelength of 2100nm and can be used to fragment stones of various composition and pulverize renal stones down to fine dust.²¹

Figure1. Energized atoms of the Lasing medium (Ho:YAG) within the optical cavity in ground state (E^0) **absorbs** the energy and are excited (E^*) by moving their electron to the outer orbit (E^0 to E^*)

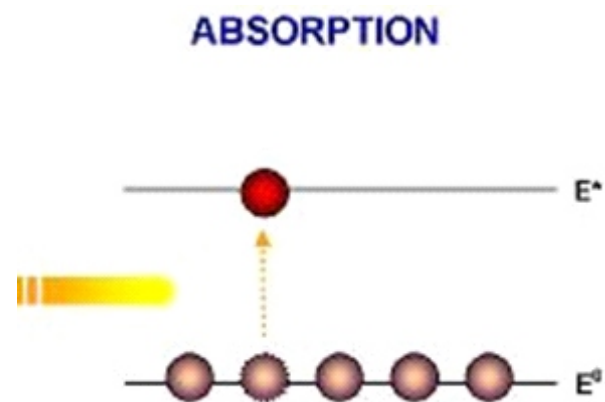


Figure 2. The excited state of atoms of the Ho:YAG (E^*) is unstable and the atoms return to ground state (E^0) emitting photons (spontaneous emission of radiation/ photons)

SPONTANEOUS EMISSION OF RADIATION

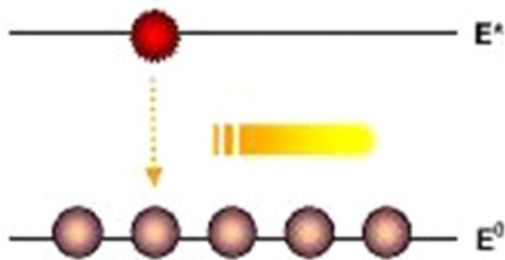
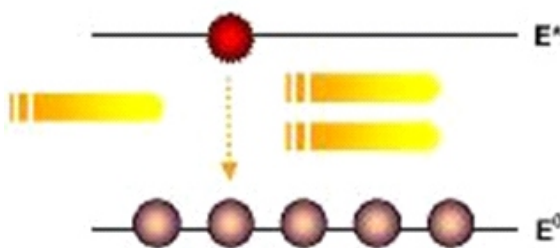


Figure 3. Emitted photon from one atom strikes another leading to generation of another electromagnetic waves (Light) of the same wavelength, phase and direction (Stimulated Emission of radiation). With opposing reflective mirrors in the optical cavity, the light emitted reflects back and forth along the same axis of the cavity, stimulating increasing numbers of photons (Light amplification). Light allowed to pass through the parallel reflective mirrors at the end is collimated and monochromatic and constitute the laser (light amplification by stimulated emission of radiation) beam.

STIMULATED EMISSION OF RADIATION



Stone disintegration with Ho:YAG laser is achieved primarily by photothermal ablation. The photothermal ablation is accomplished by conversion of light energy into heat that causes the stone to disintegrate as well as crack due to the rapidly expanding vapour within the stone.^{22,23,24}

The Ho:YAG laser is rapidly absorbed by water. Given that the human tissue is chiefly composed of water, the energy of the laser does not cause significant tissue damage as far as the laser is fired away from the urothelium.²²

Commercially available Ho:YAG laser systems can be grouped into two broad categories: the low-power (10 – 30W) and high-power (typically 60-100W) laser systems. While the lower-power generator is made out of a single laser cavity, the high-power laser incorporates multiple laser cavities.²⁵

Recently, high power 120W Ho:YAG laser with Moses-effect has been launched.^{26,27} This emits a modulated laser pulse. The first pulse divides the water between the laser fibre and the stone while, the second part hit the stone unobstructed. The Moses-effect is not only efficient but reduces stone retropulsion and in effect more ablation.^{27,28}

Holmium- Yttrium-Aluminum-Garnet laser fibre

Laser fibre plays an important role in flexible ureteroscopy lithotripsy procedure. The fibres are flexible, allowing them to pass through the working channel of the ureteroscope.²⁵

The fibre is made from silica quartz. The Ho:YAG energy is transmitted in the fibre ranging from 150 μ m to 1000 μ m in calibre. Most urologists use the fibres from 200 μ m to 365 μ m for flexible ureteroscopy. The 272 μ m fibre is however the workhorse for the flexible ureteroscopy. The larger fibres, 365 μ m and above are more durable and have higher efficiency but reduces flexible ureteroscope deflection and minimize working channel irrigation space.^{25,29}

Traditionally, the tip of the laser fibre used with flexible ureteroscope is flat. Recently, ball-shaped laser fibre tip has been introduced. The ball tip laser fibre is thought to allow passage of the fibre through the scope with less resistance and therefore avoid

damage to the delicate inner lining of the scope. A puncture to the inner lining of the scope leads to fluid leakage into the interior of the flexible scope causing expensive damage. As the ball tip burns back with the first use of the fibre, this advantage over the flat tip evens out. Importantly, the stone disintegration efficiency between the flat tip and the ball tip laser fibre is not significantly different.²⁵

The Ho:YAG laser fibre consist of three primary parts. The innermost piece is the silica core, which has the property of total internal reflection that allows the transmission of the laser energy. The core is encased by the cladding which helps to trap the light in the core and prevents energy from escaping the fibre, especially during fibre bending. The core and the cladding are in turn encased by the outer jacket. The jacket is usually coloured in order to improve visibility but takes no part in transmission of laser energy.^{29,30}

Both a single-use and reusable laser Ho:YAG laser fibre are commercially available.^{25,31} The theoretical advantage of the single-use Ho:YAG laser fibre over the reusable fibre is that the former comes with perfectly prepared fibre tip that is cleaved and stripped by the manufacturer. Another advantage is that of reliable laser fibre shaft integrity which is not likely to fail during use and lead to inadvertent damage of the flexible ureteroscope. The connector of the single-use laser fibre that has not been previously used is likely to be better and more efficient than that of the reusable one. Also there is no need for re-processing and sterilization of the fibre. The re-processing of laser fibre in itself can be cumbersome and is an imperfect process.²⁵

However, reusable Ho:YAG laser fibre has been found to be more cost-effective. And very importantly, the overall performance between single-use and reusable Ho:YAG laser fibre has been found to be similar.^{32,33} In recent years, there has been an incomplete but gradual shift towards the use of single-use fibre.²⁵

Holmium- Yttrium-Aluminium-Garnet setting and efficiency

The Ho:YAG laser parameters include the pulse energy, pulse frequency and pulse duration,²⁷ These parameters could be adapted by the operator to achieve desirable effects on stone disintegration.

Pulse energy is the optical energy emitted at the laser fibre tip and is measured in Joules (J). Factors that influence the selection of pulse energy include mainly the stone density and the desired fragment sizes.³⁴

Urologists have shown a particular interest for low pulse energy setting. This setting seems to produce particularly fine fragments (stone dust) for stones of different composition including calcium and non-calcium containing stones. The fine fragments evacuate spontaneously obviating the need for time-consuming retrieval of the larger stone fragments.³⁵ Recently, high-frequency, high-power Ho:YAG laser generators have been developed for more efficient stone dusting at low pulse energy settings and very high frequency.²⁶

Pulse frequency on the other hand is the measure of optical pulses emitted from the fibre tip in one second expressed in hertz (Hz). Increasing the pulse frequency while keeping the pulse energy constant results in faster fragmentation rates.³⁶

Pulse duration is the period in which a single optical pulse is emitted in microseconds. The conventional laser systems use fixed pulse duration setting at 150 – 350microseconds (short pulse) whereas the high-power Ho:YAG laser systems allow selection of longer pulse duration of up to 1,200microseconds.^{37,38} Long pulse duration deliver the same amount of pulse energy as short pulse, but over a longer period of time. This difference is exploited to enhance lithotripsy performance. The main advantage of using long pulse is to decrease retropulsion and reduce fibre tip degradation³⁸

Different pulse modulation for Ho: YAG laser including Moses-effect, vapour tunnel, virtual basket and bubble blast have been introduced by different Ho: YAG laser manufacturers, seeking to optimize renal stone disintegration.²⁶

The virtual basket, like the Moses-effect, consists of

double pulse emission. The first pulse generates the vapour bubble while the second pulse is propagated through the bubble to hit the stone. The virtual basket is believed to combine a low stone retropulsion with fragment suction effect.³⁹

The vapour tunnel mode consists of a single long pulse. It is designed to minimize peak power, leading to formation of elliptical and elongated bubble instead of the familiar spherical bubble as found in short pulse. This prevents stone retropulsion. In bubble blast, the second pulse is emitted after the complete collapse of the first bubble.³⁹

Flexible ureteroscopy and Ho:YAG laser are applied with varying ease depending on the size, location and complexity of the stone within the renal pelvicalyceal system. The modality has become a major technique in the treatment of stones less than 2.0cm located within the pelvicalyceal system.⁴⁰

In the recent European guideline in the management of renal stones, both the flexible ureteroscopy and external shock wave lithotripsy (ESWL) have become the first line management options for stones less than 2.0cm located in the renal pelvis, upper and middle calyces.⁴¹ Grasso and Ficazozola^[42] recorded a stone-free rate of 95% for intrarenal stones measuring 1.1-2.0mm with this technique.

While, percutaneous nephrolithotomy (PCNL) is the gold standard for treatment of large and complicated renal stones, it has steep learning curve and it is associated with significant complications.^{43,44}

Flexible ureteroscopy with Ho:YAG laser remains a less morbid option and has been applied by some urologist in complex stone scenarios particularly in high risk patients.^{44,45}

Flexible ureteroscopy and Ho:YAG lithotripsy also has been described as a good adjunct to the PCNL for the successful treatment of staghorn and other complex renal stones in order to reduce the number of the PCNL tracts and enhance stone-free rate.^{46,47} This combination could be in stages, carried out for residual stones after the PCNL, or as endoscopic combined intrarenal surgery (ECIRS) in same sitting

with the PCNL.⁴⁸

In the lower pole of the kidney it may be difficult to orient Ho:YAG laser fibre to the stone, and may prove a risk for fibre failure and damage from the fibre as the laser leak to the ureteroscope.⁴⁹ This difficulty is due to the dependent position and peculiar anatomy of the lower calyces which make them less accessible to the flexible ureteroscope compared to the mid and upper calyces.^{50,51}

So, in the lower pole stones, relocating the stone with Nitinol basket to a more favourable calyx (middle or upper calyx) is advised before lasing them. The nitinol baskets cause minimal loss of scope active deflection and lead to less interference with irrigation flow in comparison to the smallest of the Ho:YAG laser fibre. This facilitates successful access with the basket to the lower pole with better visibility facilitating relocating the stone.^{52,53}

However, with the manufacture of scopes with extended active deflection abilities, single-use flexible ureteroscopes as well as the more efficient laser systems, insitu Ho:YAG laser lithotripsy of stones in the lower pole is becoming common place.⁵³

Obesity can negatively affect the treatment options for renal stones. The success rate of ESWL is reduced remarkably because of the skin to stone distance.^{54,55}

Also, PCNL in obese patients is not ideal due to long tract and increased anesthetic complications particularly when the PCNL is carried out in prone position. Flexible ureteroscopy with Ho:YAG lithotripsy is efficacious in this setting as documented by many authors.^{55,56,57}

Again, ESWL and PCNL are contraindicated in the setting of bleeding diathesis as well as in patients on anticoagulants. Flexible ureteroscopy with Ho:YAG laser has been found to be safe for the treatment of renal stones in these category of patients.^{58,59}

Techniques of renal stone disintegration with Holmium-yttrium-aluminium-garnet Laser

In using the Ho:YAG laser with flexible ureteroscopy, stone disintegration can be performed by several techniques:

Dusting

Here, dust-sized fragments are produced by painting movements across the surface of the stone. The stone is pulverized into fine dust with no real clinical need to remove the resulting fragments (usually less than 1mm in diameter).⁶⁰ The potential advantage in this technique is reduced operation time because it avoids multiple passes with the scope to remove the stone fragments. The drawback is that where the fragments fail to pass and remain in the collecting system, they may become nidus for recurrent stone formation. Dusting is achieved by using lower energy level of (0.2J -0.5J) and higher pulse frequency of 15Hz and above, leading to small debris.⁶⁰

Fragmentation

Fragmenting technique leaves the stone pieces of more than 1mm. Many authors prefer this technique for harder stones (such as calcium oxalate monohydrate and cystine stones) where dusting may not be efficacious. The larger fragments produced by this technique require endoscopic basketing or other forms of extraction. The main advantage of this technique is that basketing the resulting fragments reduces residual stone burden and ultimately enhances stone-free rates. The main disadvantage is potentially longer operating time. Fragmentation is achieved by higher pulse energy level of 1.5 – 2J and pulse frequency of 5Hz.⁶⁰

Popcorning

In this technique, the laser fibre is placed some distance away from a collection of stone fragments, especially in a confined area, usually the minor calyx. The laser vapour bubbles cause the stones fragments to bounce like 'popcorn'. As the fragments are agitated, with intermittent contact with the laser fibre, photothermal disintegration takes place. Ultimately, the 'popcorning' effect produce smaller and smaller fragments resulting in fine stone dust. Studies have shown that Ho:YAG setting of 1.0J and 20Hz results the most efficient stone dusting when using this technique.⁶⁰

Safety and complications of Holmium: yttrium-aluminum-garnet laser

The use of Ho:YAG laser has been found to be safe in a wide range of settings.^{61,62} However, there are still some safety concerns and complications that may arise from its use in renal stone disintegration.

For instance, there is usually local temperature rise within the kidney during the use of Ho:YAG laser use for the renal stone disintegration. Many authors have documented that the temperature rise of up to 70 degree Celsius or even more raising concern of potential tissue injury.^{63,64} The high temperature rise during Ho:YAG lithotripsy could theoretically cook the surrounding renal tissue. In particular, high-power Ho:YAG laser presents greater energy deposition and so increased risk of induction of thermal tissue injury.⁶³ Therefore to prevent this complication, intermittent laser activation, higher irrigation flow rate and shorter surgery time should be employed to mitigate this complication.^{63,65}

Ho:YAG laser energy could also lead to perforation if the energy is directly in contact with the urothelium of the pelvicalyceal system. It is therefore essential to operate with the laser fibre under direct vision at all times and avoid contact with the wall of the pelvicalyceal system during lithotripsy.⁶⁶

Also, eye injury is one of the main concerns when Ho:YAG laser is in use. However, it has been demonstrated that eye injury is possible only in high-energy laser settings, very close distances (0-5cm) and when the eyes are not protected. Indeed, no eye injury has been reported with Ho:YAG lasers during lithotripsy for renal stone in contemporary series.⁶⁷

Related to material-safety, Ho:YAG laser can damage the very delicate and expensive flexible ureteroscope as well as some accessories such as guide-wire and stone baskets. For instance, the fibre tip is sharp and can act as a 'hagoon' within the working channel of the ureteroscope if the fibre is passed through a deflected ureteroscope. To prevent this, the laser fibre should not be passed through a deflected flexible ureteroscope.⁶⁸

Also, to prevent the damage to the ureteroscope, laser

fibre must be activated at a safe distance from the optical end of the scope, approximately one-fourth of the endoscopic field of view.⁶⁸ Again, when acute angle deflection of the scope is required to reach the lower calyceal stone, smaller core fibre which are less likely to fracture and cause damage to the scope is recommended.⁶⁹

CONCLUSION

Holmium: yttrium-aluminum-garnet laser is the most robust and commonly used energy source for renal stone disintegration. Understanding its physics, proper choice of laser fibres and appropriate setting of the laser machine are essential for its optimal use in flexible ureteroscopy for renal stone

REFERENCE

- Norlin A, Lindell B, Granberg PO, Lindvall N. Urolithiasis: a study of frequency. *Scand J Urol Nephrol*1976; 10: 150–153.
- Scales CD Jr, Smith AC, Hanley JM, Saigal CS. Prevalence of kidney stones in the United States. *Eur Urol*2012; 62: 160–165.
- Esho JO. Experience with urinary calculus disease in Nigerians as seen at the Lagos University Teaching Hospital. *Niger Med J* 1976; 6: 18–22.
- Mbonu O, Attah C, Ikeakor I. Urolithiasis in an African population. *Int urol Nephrol* 1984; 16: 291–296.
- Aji SA, Alhassan SU, Mohammed AM, Mashi SA. Urinary stone disease in Kano, North-Western Nigeria. *Niger Med J*2011; 52: 83–85.
- Meshelia DS, Gali BM, Naaya UH, Habu SA. Chemical composition of urinary calculi in Maiduguri, Nigeria. *Afr J Med Sci* 2005; 34: 185–188.
- Emokpae MA, Gadzama AA. Anatomical distribution and biochemical compositions of urolithiasis in Kano. *Int J Bio Chem Sci* 2012; 6: 1158–1166.
- Miller N. Management of kidney stones. *BMJ* 2007; 334: 468–472.
- Grasso M, Bagely D. A 7.5/8.2F actively deflectable, flexible Ureteroscope: a new device for both diagnostic and therapeutic upper urinary tract endoscopy. *Urology*1994; 43: 435-441.
- Denstedt JD, Razvi H, Sales JL, Eberwein PM. Preliminary experience with holmium:YAG laser lithotripsy. *J Endourol* 1995; 9: 255–258.
- Natalin RA, Landman J. Where next for the endoscope? *Nat Rev Urol*2009; 6: 622–628.
- Boyle WS, Smith GS. Charge couple semiconductor devices. *Bell Syst Tech J* 1970; 49: 587–593.
- Andonian S, Okeke Z, Smith AD. Digital Ureteroscopy: the next step. *J Endourol* 2008; 22: 603–605.
- Miller J, Stoller ML. Intracorporeal lithotripsy: Electrohydraulic, pneumatic and ultrasonic. In: Monga M, editor. *Ureteroscopy: Indications, Instrumentation and Technique*. New York: Human Press.2013; p 149–158.
- Marks AJ, Teichman JM. Lasers in clinical urology: state of art and new horizons. *World Journal of Urology*2007; 25: 227–233.
- Sofer M, Denstedt J. Flexible Ureteroscopy and lithotripsy with holmium: YAG laser. *Can J Urol* 2007; 7: 952–956.
- Leveillee RJ, Lobik L. Intracorporeal lithotripsy: which modality is the best? *Current Opin Urol* 2003; 13: 249–253.
- Meija J, Coplen TB, Berglund M, Brand WA, Bièvre PD, Gröning M, et al. Atomic weights of the elements. IUPAC Technical Report.2016; 88: 265–291.
- Kiss ZJ, Pressley RJ. Crystalline solid lasers. *Proceedings of the IEEE*.1996; 54: 1236–1247.
- Pollnau, M. Phase aspect in photon emission and absorption. *Optica* 2018; 5: 465–474.
- Treat MR, Trokel SL, Reynolds RD, De Filippi VJ, Andrew J, Liu JY, Cohen MG. Preliminary evaluation of pulsed 2.15µm laser system for fibreoptic endoscopic surgery. *Lasers Surg Med* 1988; 8: 322–326.
- Chan KF, Vassar GJ, Pfefer TJ, Teichman JM, Glickman RD, Weintraub, et al. Holmium: YAG laser lithotripsy: a dominant photoablative

- mechanism with chemical decomposition of urinary calculi. *Laser Surg Med* 1999; 25: 22–37.
23. Aldoukhi AH, Robert WW, Hall TL, Ghani KR. Holmium laser lithotripsy in the new Stone Age: dust or bust? *Front Surg* 2017; 4:57. doi 10.3389/fsurg.2017.00057.
 24. Dushinski JW, Lingeman JE. High speed photographic evaluation of holmium laser. *J Endourol* 1998; 12: 177–181.
 25. Knudsen BE. Laser fibres for holmium: YAG lithotripsy: what is important and what is new? *Urol Clin N Am* 2019; 46: 185–191.
 26. Aldoukhl AH, Roberts WW, Hall TL, Ghani KR. Watch your distance: the role of laser fibre working distance on fragmentation when altering pulse width or modulation. *J Endourol* 2018; 33: 120–126.
 27. Black KM, Aldoukhi AH, Ghani KR. A user's guide to holmium laser lithotripsy settings in the modern era. *Front Surg* 2019; 6: 48. Doi: 10.3389/fsurg.2019.00048.
 28. Mullerad M, Ayuinaga JR, Aro T, Kastin A, Goldin O, Kravtsov A, et al. Initial clinical experience with a modulated holmium laser pulse-Moses Technology: does it enhance laser lithotripsy efficacy? *Rambam Maimonides Med J* 2017; 8: e00038. doi: 10.5041/RMMJ.10315.
 29. Nazif OA, Teichman JM, Glickman RD, Welch AJ. Review of laser fibres: a practical guide for urologists. *J Endourol* 2004; 18: 818–829.
 30. Fried NM, Irby PB. Advances in laser technology and fibreoptic delivery systems in lithotripsy. *Nat Rev Urol* 2018; 15: 563–573.
 31. Knudsen BE, Pedro R, Hinck B, Monga M. Durability of reusable holmium:YAG laser fibres: a multicenter study. *J Urol* 2011; 185: 160–163.
 32. Knudsen BE, Glickman RD, Stallman KJ, Maswadi S, Chew BH, Beiko DT, et al. Performance and safety of holmium:YAG laser optical fibres. *J Endourol* 2005; 19: 1092–1097.
 33. Mues AC, Teichman JM, Knudsen BE. Evaluation of 24 holmium: YAG laser optical fibres for flexible Ureteroscopy. *J Urol* 2009; 182: 348–354.
 34. Spore SS, Teichman JMH, Corbin NS, Champion PC, Williamson EA, Glickman RD. Holmium:YAG lithotripsy: optimal power settings. *J Endourol* 1999; 13: 559–566.
 35. Wu Z, Gao P, Feng C, Wang L, Mao S, Ding Q, et al. MP-04.10 flexible ureteroscopic stone dusting with holmium: YAG laser for treatment of renal stones. *World J Urol* 2016; 34(Suppl): 19–25.
 36. Li R, Ruckle D, Keheila M, Maldonado J, Lightfoot M, Alsyon M, et al. High frequency dusting versus conventional holmium laser lithotripsy for intrarenal and ureteral calculi. *J Endourol* 2017; 31: 272–277.
 37. Kang HW, Lee H, Teichman, Oh J, Welch AJ. Dependence of calculus retropulsion on pulse duration during Ho:YAG laser lithotripsy. *Lasers Surg Med* 2006; 38: 762–772.
 38. Sroka R, Pongratz T, Scheib G, Khoder W, Stief CG, Hermann T, et al. Impact of pulse duration on Ho:YAG laser lithotripsy: treatment aspects on the single-pulse level. *World J Urol* 2015; 33: 479–485.
 39. Pul Moises E, Rodriguez ME, González LL, Reinoso J, Rivas JA, Alamo VC, et al. Pulse Modulation for Holmium Laser: Vapor Tunnel–Virtual Basket–Bubble Blast. *Videourology* 2020; 34: doi.org/10.1089/vid.202.00818.
 40. Alene Zitt, Denstedt JD. Flexible Ureteroscopy: technological advancements, current indications and outcomes in the treatment of urolithiasis. *Asian Journal of Urology* 2015; 2: 133–141.
 41. Türk C, Neisius A, Seitz PC, Skolarikos A, Somani B, Thomas K, et al. EAU guidelines on urolithiasis. 2021: 29–30.
 42. Grasso M, Ficazzola M. retrograde ureteropyeloscopy for lower pole caliceal calculi. *J Urol* 1999; 162: 1904–1908.
 43. Chung BI, Aron M, Hegarty NJ, Desai MM. ureteroscopic versus percutaneous treatment for medium-size (1-2cm) renal calculi. *J Endourol* 2008; 22: 343–346.
 44. Ferroud V, Lapouge O, Dousseau A, Rakototiana A,

- Robert G, Ballanger P. Flexible ureteroscopy and minipercutaneous nephrolithotomy in the treatment of renal lithiasis less or equal to 2cm. *Prog Urol* 2011; 21: 79–84.
45. Sabnis RB, Jagtap J, Mishra S, Desai M. Treating renal calculi 1-2cm in diameter with minipercutaneous nephrolithotomy or retrograde intrarenal surgery: a prospective comparative study. *BJU Int* 2012; 10: 346–349.
 46. Margret CG, Springhart WP, Tan YH, Patel A, Undre S, Albala DM, et al. simultaneous combined use of flexible Ureteroscopy and percutaneous nephrolithotomy to reduce the number of access tracts in the management of complex renal calculi. *BJU Int* 2005; 96: 1097–1100.
 47. Zeng G, Zhao Z, Wu W, Zhong WE. Combination of debulking single-tract percutaneous nephrolithotomy followed by retrograde intrarenal surgery for staghorn stones in solitary kidneys. *Scand J Urol* 2014; 48: 295–300.
 48. Hamamoto S, Yasui T, Okada A, Taguchi K, Kawai N, Ando R, et al. endoscopic combined intrarenal surgery for large calculi: simultaneous use of flexible Ureteroscopy and minipercutaneous nephrolithotomy overcomes the disadvantages of percutaneous nephrolithotomy monotherapy. *J Endourol* 2014; 28: 28–33.
 49. Elbahnasy AM, Shalhav AL, Hoenig DM, Elashry OM, Smith DS, Mcdougall EM, et al. Lower caliceal stone clearance after shockwave lithotripsy or Ureteroscopy: the impact of lower pole radiographic anatomy. *J Urol* 1998; 159: 676–682.
 50. Geavlete P, Mutescu R, Geavlete B. Influence of pyelocaliceal anatomy on the success of flexible ureteroscopic approach. *J Endourol* 2008; 22: 2235–2259.
 51. Resorlu B, Oguz U, Resorlu EB, Oztuna D, Unsal A. The impact of pelvicaliceal anatomy on the success of retrograde intrarenal surgery in pateints with lower pole renal stones. *Urology* 2012; 79: 61–66.
 52. Kourambas J, Delvecchio F, Munver R, Preminger GM. Nitinol stone retrieval- assisted ureteroscopic management of lower pole renal calculi. *J Urol* 2012; 4295: 935–939.
 53. Schuster TG, Hollenbeck BK, Faerber GJ, Wolf JS. Ureteroscopic treatment of lower pole calculi: comparison of lithotripsy insitu and after displacement. *J Urol* 2002; 168: 43–45.
 54. Aboumarzouk OM, Somani B, Monga M. Safety and efficacy of ureteroscopic lithotripsy for stone disease in obese patients: a systematic review of literature. *BJU Int* 2012; 110: 374–380.
 55. Chew BH, Zavaglia B, Paterson RF, Teichman JMH, Lange D, Zappavigna C, et all. A multicenter comparison of the safety and effectiveness of ureteroscopic laser lithotripsy in obese and normal weight patients. *J Endourol* 2013; 27: 710–714.
 56. Pompeo A, Molina WR, Juliano C, Sehr D, Kim FJ. Outcomes of intracorporeal lithotripsy of upper tract stones is not affected by BMI and skin-to-stone distance (SSD) in obese and morbid patients. *Int Braz J Urol* 2013; 39: 702–711.
 57. Caskurlu T, Atis G, Arikan O, Pelit ES, Kilic M, Gurbuz C. The impact of body mass index on the outcomes of retrograde intrarenal stone surgery. *Urology* 2013; 81: 517–521.
 58. Watterson JD, Girvan AR, Cook AJ, Beiko DT, Nott L, Auge BK, et al. Safety and efficacy of holmium: YAG laser lithotripsy in patients with bleeding diastheses. *J Urol* 2002; 168: 442–445.
 59. Kuo RL, Aslan P, Fitzgerald KB, Preminger GM. Use of Ureteroscopy and holmium:YAG laser in patients with bleeding diastheses. *Urology* 1998; 52: 609–613.
 60. Patel AP, Knudsen BE. Optimizing use of the homium:YAG laser for surgical management of urinary lithiasis. *Curr Urol Rep* 2014; 15: 397. doi: 10.1007/s11934-014-0397-2.
 61. Gosh A, Somani BK. Safety and feasibility of a day care Ureteroscopy and laser lithotripsy (URSL) in patients with a solitary kidney. *Centre Eur J Urol* 2016; 69: 91–95.
 62. Yoshioka T, Otsuki H, Uehara S, Shimizu T, Murao W, Fujio K, et al. Effectiveness and safety of

- ureteroscopic holmium laser lithotripsy for upper urinary tract calculi in elderly patients. *Acta Med Okayama* 2016; 70: 159–166.
63. Aldoukhi AH, Ghani, Hall TL, Roberts WW. Thermal response to high-power holmium laser lithotripsy. *J Endourol* 2017; 31: 1308–1312.
64. Buttice S, Sener TE, Proietti S, Dragos L, Tefik T, Doizi S, et al. Temperature changes inside the kidney: what happens during holmium:yttrium-aluminium-garnet laser usage? *J Endourol* 2016; 30: 574–579.
65. Gross AJ, Netsch C. Editorial comment on: thermal response to high-power lithotripsy by Aldoukhi et al. *J Endourol* 2017; 31: 1313.
66. Matlaga BR, Lingeman JE. Surgical management of stones: a new technology. *Adv Chronic Kidney Dis* 2009; 16: 60–64.
67. Althunayan AM, Elkoushy MA, Elhilali MM, Andonian S. Adverse events resulting from the lasers used in urology. *J Endourol* 2014; 28: 256–260.
68. Talso M, Emilliani E, Haddad M, Berthe L, Baghdadi M, montanari E, et al. Laser fibre and flexible ureterorenoscopy: the safety distance concept. *J Endourol* 2016; 30: 1269–1274.
69. Haddad M, Emiliani E, Rouchausse Y, Coste F, Dozi S, Berthe L, et al. Impact of curve diameter and laser settings on laser fibre fracture. *J Endourol* 2017; 31: 918–921.