

ORIGINAL ARTICLE

Use of EarPopper® for The Treatment of Otitis Media with Effusion: A First Pilot Study in Africa

Titus S **IBEKWE**^{1,2}

Enoch A **DAHILO**¹

David O

FOLORUNSHO¹

Toochukwu

UZOCHUKWU¹

Bosa **EGBE**¹

Oladeji R **QUADRI**¹

Frederick **DAMTONG**¹

Basil C **NWANKWO**¹

Iboro **ETUKUMANA**¹

Ibeneche O **GBUJIE**^{1,3}

¹Department of
Otorhinolaryngology
University of Abuja &
University of Abuja
Teaching Hospital Abuja,
NIGERIA

²Garki Hospital Abuja

³Abuja Clinic Abuja

Author for Correspondence

Prof Titus **IBEKWE**

University of Abuja Teaching
Hospital

Gwagwalada Abuja

PMB 228 Abuja, NIGERIA

Email:

titus.ibekwe@uniabuja.edu.ng

Phone: +234 803 348 4380

Received: January 25th, 2021

Accepted: February 10th, 2021

DISCLOSURE

Authors declare no conflict of interest or financial support for the study

ABSTRACT

Background: A missed or non-diagnosed otitis media with effusion at very early age in life can impair the cognitive developmental milestone, especially hearing. Therefore, early diagnosis and treatment (medical, surgical or physiological) is pertinent. A search for an inexpensive, minimally invasive method led to the development of EarPopper®

Methodology: A prospective interventional study on the use of EarPopper® in the treatment of otitis media with effusion. The EarPopper® uses the Politzer method of pressure equilibration to decongest the middle ear through the Eustachian tube.

Result: Seven patients (4 males, 3 females) aged between 11 and 54 years were enrolled. Five were bilateral and 2 were unilateral (12 ears). All had type B curves and mild to moderate conductive hearing loss. The pre-therapy EarPopper Scoring System were 60-98%, while the post therapy result dropped to 0-25%.

Conclusion: The EarPopper® showed a good prospect in the treatment of otitis media with effusion in an African population.

Key words Otorhinolaryngologic diseases, EarPopper Scoring System, Pilot study, Ear diseases, Otitis media

INTRODUCTION

Otitis media with effusion (OME) is a common middle ear disorder particularly but not exclusive in children, typically characterized by the accumulation of serous fluid within the middle ear cavity.


A missed or non-diagnosed OME at very early age in life can impair the cognitive developmental milestone.^{1,2} Every child aged 2 months to 12 years is prone to developing otitis media with effusion.³ In the first year of

life, more than 50% of children will experience OME, increasing to more than 60% by age 2 years. Downs syndrome, craniofacial abnormalities or congenital anatomical defects of the nasopharynx are predisposing factors leading to up to 93% prevalence of OME in infants, before surgical repairs.⁴ Adenoid enlargement, Eustachian Tubes (ET) dysfunctions, atopy, barotrauma also predispose to OME.

The Methods of managing persistent OME include medical, surgical or physiological measures to equalize the middle ear with the atmospheric pressure. Medical measures include administration of decongestants, antihistamines, corticosteroids, and antibiotics. The benefits of antihistamines and antibiotics have been questioned and may or may not be recommended for treatment.⁵ It is expedient to get the OME under control until the time that such surgical procedures could be carried out where necessary.

To this end, the search for a cheap, efficient, non-traumatic and minimally-complication-prone method for the management of OME is still on. This led to the development of the EARPOPPER® (Figure 1) based on the Politzer physiology principles, which is basically the equalization of middle ear with the atmospheric pressures.⁴

Figure 1. The Ear-popper device showing the major components including the nose-piece, start button and the base battery end



It is a medical device that brings about the decongestion of the middle ear cavity via insufflations of the Eustachian tubes. It has passed through all necessary stages of scrutiny including clinical trials in the USA and finally got the approval of FDA in 2007.^{6,7} The method appears safe and efficient among users in USA and Europe but yet to be tried among Africans.

The study aims to ascertain the suitability and efficiency of EarPopper® device in the treatment of OME in our setting.

METHODOLOGY

A prospective interventional (on-going) study of volunteers diagnosed with OME from three medical centres in Abuja: University of Abuja Teaching Hospital, Garki Hospital and Abuja Clinic.

Ethical approval for the research with registration number FCT/UATH/HREC/PR/330, was obtained from the University of Abuja Teaching Hospital Health Research Ethics Committee. Ethical considerations in line with the Helsinki declaration were followed and informed consents were obtained from the participants or the parents/guardian of the minors.

The enrolment of the patients was through convenience sampling method. Pneumatic otoscopy, Video-otoscopy, Tympanometry and Pure Tone Audiometry were done to confirm OME. The criteria for inclusion were: Clinical evidence of OME viz symptoms and otoscopic features, confirmation of OME through Type B tympanogram obtained using Amplaid-tymp model A756, evidence of Conductive Hearing Loss (CHL) with tuning fork and Pure Tone Audiometry using Amplivox 270 model audiometer/ISO calibrated. There was no known negative effect associated with the procedure.

Table 1. Participant characteristics

Age (years)	Gender	Diagnosis	Duration of illness before EarPopper treatment	Duration of EarPopper treatment (weeks)	Tympanometry and Audiogram before treatment	Tympanometry /audiogram after treatment
25	F	Rt. OME	6months	3	Type B/ Moderate CHL	Type As/mild CHS
30	M	Bil. OME	1year	4	Type B(Bil) /mild CHL(Bil)	Type A(Rt)/normal Audiogram Type B(Lt)/mild CHL
54	M	Bil. OME	2years	11	Type B(Bil)/ moderate CHL(Bil)	Type A (Rt)Bil/ normal Audiogram
11	F	Bil. OME	5months	3	Type B(Bil) /mild CHL(Bil)	Type A/Bil normal Audiogram
17	M	Bil. OME	13months	2	Type B(Bil) /mild CHL(Bil)	Type A(Bil)/normal audiogram
45	M	Bil. OME	3years	10	Type B(Rt)/ moderate CHL(Rt)	Type A/mild CHL
21	F	Bil. OME	9months	2	Type B(Bil)/ moderate CHL	Type A(Bil)/normal audiogram(Bil)

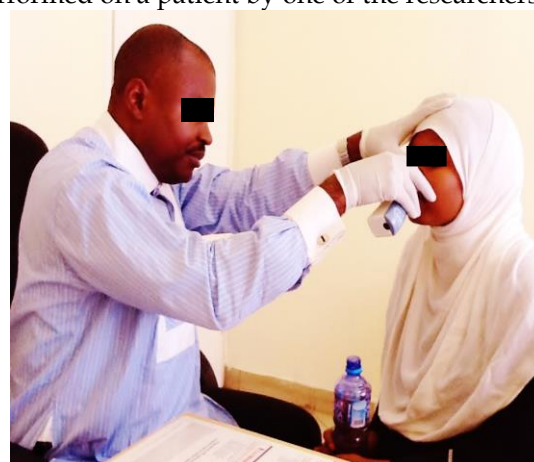Bil=Bilateral; Rt.=Right; Lt=Left; OME=Otitis Media with Effusion; CHL=Conductive Hearing Loss

The procedures and reading of the results were done by the specialist Ear, Nose and Throat surgeons involved in the research following standardized methods (Figure 2).⁸

Participants had serial EarPopper® (model EP-3000) therapies, twice weekly for 2-12weeks. Outcome was evaluated using patients' reports, EarPopper Scoring System(ESS) and the Audiometric Assessment Parameters Cure for OME. This (outcome) refers to a total resolution of effusion within the middle ear which is assessed using a dichotomous variable of "absence or presence" of effusion post treatment and clinical features. Non-cure for OME implies persistence or presence of middle ear effusion after 12 weeks of treatment with EarPopper®.

Data were analysed using Statistical Package for Social Sciences (SPSS) version 21 software.

Figure 2. The EarPopper procedure being performed on a patient by one of the researchers



RESULTS

Seven patients (4 males, 3 females) aged between 11 and 54 years were enrolled (Table 1). There were five bilateral and 2 unilateral cases (12 ears). All had type B curves and mild to moderate conductive hearing loss. The pre-therapy ESS were 60-98%. The durations of the EarPopper therapies ranged from 2 to 12 weeks. Post-EarPopper therapy outcome revealed resolution in all unilateral cases and 4 bilateral cases. The 5th bilateral case had unilateral resolution. Post-therapy ESS dropped to 0-25%.

DISCUSSION

The EarPopper® has been tested in young children. Arick and Silman in 2005 carried out a randomised control study on children between 4 and 11 years.⁵ The study reported significant improvements with remarkable recovery of hearing sensitivity. They noted that further studies of safety and effectiveness were required in children younger than four years, adolescents and adults.

Our study considered children and adults. Many episodes resolved spontaneously within 3 months, but about 30% to 40% of children have recurrent OME and 5% to 10% of episodes last 1 year or longer. In this ongoing study, the duration of the disease before ear popper therapy was also considered. Eleven out of the 12 ears involved in this study so far, have achieved complete resolution and no harm or injury was noticed in any of the patients.

Similarly, a related problem to OME where the EarPopper therapy could be indicated is the Eustachian Tube Dysfunction(ETD). This could be found in any age group and could be a serious source of distress especially during air travels and in divers. The ascent or descent from heights can cause serious discomfort which sometimes threaten career prospects. The Valsalva manoeuvres and Politzer have been employed in managing

such patients and sometimes decompression may be necessary. ETD could be significantly recalcitrant to surgery and as a result more sophisticated and relatively expensive methods like the Balloon dilatation are on experimental trials currently.¹¹ The EarPopper® was also reported to be effective among the Americans in this regard.¹²

CONCLUSION

This preliminary study highly suggests a good prospect in the use of EarPopper® in the management of OME among Africans. There is need for an expanded multi-center randomized control study.

REFERENCES

1. Rosenfeld RM, Shin JJ, Schwartz SR, Coggins R, Gagnon L, Hackell JM, *et al.* Clinical Practice Guideline: Otitis Media with Effusion Executive Summary (Update). *Otolaryngol Head Neck Surg* 2016 ;154(2):201-14. doi: 10.1177/0194599815624407. PMID: 26833645.
2. Ibekwe TS. Otitis Media focusing on developing world. Available at: <http://ptolemy.library.utoronto.ca/sites/default/files/reviews/2009/April%20-%20otitis%20media.pdf3/23/2013>.
3. Rosenfeld RM, Culpepper L, Doyle KJ, Hoberman A, Kenna MA, Lieberthal AS *et al.* Clinical Practice Guideline: otitis media with effusion. *Otolaryngol head Neck Surg* 2004, 130: S95-118.
4. Barr E, Dungworth J, Hunter K, Mcfarlane M, Kubba H. The prevalence of ear, nose and throat disorders in preschool children with Down's syndrome in Glasgow. *Scott Med J* 2011, 56:98-103.
5. Arick DS, Silman S. Non surgical Home treatment of middle-ear effusion and associated hearing loss in children. Part 1: Clinical trials. *Ear, Nose and Throat Journal* 2005, 84:567-578.
6. Tham T. Efficacy of the EarPopper Device in Children With Recurrent Otitis Media. Available at : <https://clinicaltrials.gov/ct2/show/NC T03534219>. Last updated: December 23,2020. [Date accessed: February 8, 2021

7. Tham T, Rahman L, Costantino P. Efficacy of a non-invasive middle ear aeration device in children with recurrent otitis media: A randomized controlled trial protocol. *Contemp Clin Trials Commun* 2018 4; 12:92-97. doi: 10.1016/j.conctc.2018.09.008. PMID: 30320237; PMCID: PMC6180339.
8. Kutz JW, Mullin G, Campbell KCM, Talavera F, Gianoli GJ, Meyers AD. Audiology Pure-Tone Testing: Medscape. Available at: <https://emedicine.medscape.com/article/1822962-overview>. Last updated: August 17,2018. [Date accessed: February 8, 2021]
9. Silman S, Arick DS, Emmer MB. Non surgical Home treatment of middle-ear effusion and associated hearing loss in children. Part ii: Clinical trials-validation. *Ear, Nose and Throat Journal* 2005, 84:646, 648, 650.
10. Silman S, Arick DS. Efficacy of a modified apparatus in the management of Eustachian tube dysfunction in adults. *J M Acad Audiol* 1999; 10: 496-501.
11. Jurkiewicz D, Bien D, Szczgielski K, Kantor I. Clinical evaluation of balloon dilatation Eustachian tuboplasty in the Eustachian tube dysfunction *Eur Arch Otorhinolaryngol* 2013, 270: 1157-1160.doi:10.1007/s00405-012-2243-9
12. Parella A, Hiller J, Mundy L. National Horizon Scanning Unit, Horizon scanning prioritising summary; Volume 11, Number 4: EarPopper for the treatment of otitis media with effusion in children, December 2005. Available at: <http://www.horizonsscanning.gov.au>. [Date accessed: February 7, 2021]