

## CASE REPORT

## Partial Recovery of Traumatic Spinal Cord Injury Following Posterior Decompression/ Free Hand Pedicle Screw Instrumentation: A Case Report

Obinna H **OBIEGBU**  
Chibuzor U **NDUKWU**

*Department of Orthopaedic  
Surgery  
Nnamdi Azikiwe University  
Teaching Hospital Nnewi  
Anambra State, NIGERIA*

**Author for Correspondence**

Dr Obinna H **OBIEGBU**  
*Department of Orthopaedic  
Surgery  
Nnamdi Azikiwe University  
Teaching Hospital Nnewi  
Anambra State, NIGERIA*

*Email:  
obinnaobiegbu@yahoo.com  
Phone: +234 803 382 7517*

*Received: November 15<sup>th</sup>, 2019*

*Accepted: January 17<sup>th</sup>, 2020*

**DISCLOSURE**

The authors declare no conflict of interest

**ABSTRACT**

Spinal cord injuries can be highly disabling. Although effective treatment for spinal cord injuries remains limited, operative stabilization and decompression of the neural canal may give rise to a better outcome and a faster rehabilitation.

We report the operational management and rehabilitation of a 30-year-old woman who sustained L1 traumatic spinal cord injury with paraplegia (ASIA B) after being hit on the back by a pack of falling bricks. She sustained multiple vertebral fractures and a traumatic spondylolisthesis of L2/ L3, with canal stenosis were noted at the same level on MRI.

Pedicle screw fixation of L1 to L4 (free-hand technique) was done with decompression of L2/L3 segments.

Immediate recovery of power to the hip flexors was noted on the second post-operative day, with corresponding reduction in low back pain and subsequent mobilization on wheel chair at the end of the second post-operative week. At the end of the eight post-operative week, patient began full weight bearing on a Zimmer's frame without support.

**Key words:** *Spondylolisthesis, Neural canal, ASIA, Spinal recovery*

**INTRODUCTION**

Spinal cord injuries many a times could be a highly disabling injury, often leading to significant morbidity and sometimes mortality. It remains a major problem for surgeons in West Africa, where its management is complicated by both lack of

appropriate facilities for patient management and paucity of skilled manpower.<sup>1</sup> Documented experiences from Nigeria are few and the overwhelming problems remain unresolved.<sup>1</sup>

The mechanism of spinal cord injury in Nigeria has largely been dominated by road traffic accidents, fall from height (mainly by palm wine tappers) and contact sports.<sup>2</sup> Early and adequate management of spinal cord injured patients remain crucial for optimal outcomes. However, despite extensive studies on thoraco-lumbar spinal cord injury, divergent views still exist regarding appropriate type of treatment (conservative or surgical), the timing of surgery, need for fusion and role of spinal canal decompression and fusion.<sup>3</sup>

We report a case of lumbar multilevel traumatic spine injury (L1-L3 vertebral levels) on a female artisan following a fall of a pack of bricks on her lower back. The patient had reconstructive surgery and improved from ASIA (American Spinal Injury Classification) B to ASIA D. We also described the clinical presentation and surgical management.

### Case Presentation

A 30-year-old female (who breaks and stacks construction bricks) presented to our accident and emergency department having been referred from a private hospital (a day prior to presentation). While working at the construction site, a layer of improperly stacked bricks gave way and hit her on the back, with associated immediate onset of severe low back pain. There was no loss of consciousness nor associated injuries to any other part of her body. She was immediately rushed to a nearby private hospital where first aid was given before referral. She presented to the accident and emergency of our hospital with severe low back pain, inability to move both lower limbs, and a kyphotic deformity of the lumbar region. There were no other associated injuries. She

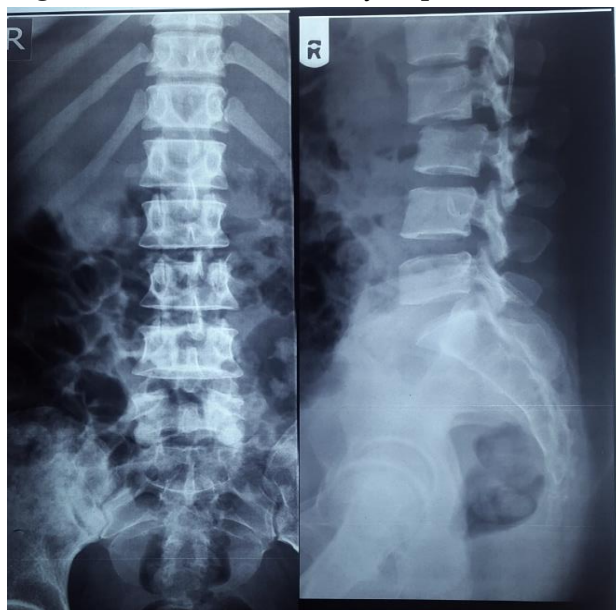
had a muscle power of 0/5 from L1-S1. We graded her ASIA B. Plain radiograph showed a fracture of the pars inter-articularis of L2 vertebrae and a fracture of the L3 spinous process with translation of L2 on L3 vertebrae (Fig 1). A computed tomography scan was requested but could not be done because of financial constraints. Magnetic resonance imaging (MRI) showed canal compression at L2 level.

Surgery (L1-L4 pedicle screw instrumentation/ decompression) was done on the 6<sup>th</sup> day post injury. She had her spine approached via a longitudinal posterior midline incision exposing L1 to L5 vertebrae. There was a deep haematoma collection and contusion of the para-spinal muscles, fracture of the spinous process of L3 level, fracture of the transverse process of L2/ L3 and fracture involving the pars inter-articularis of L2 vertebrae. Evacuation of the haematoma was done, pedicle screws were inserted (using a free-hand technique) at L1, L2 and L4 on the right, and on L1 and L4 on the left (Fig 2). Decompression of the neural canal (over L2-L3) was done via a laminectomy, and nerve root forminotomy of the corresponding spinal levels were also done. Titanium rods were then tightened over the pedicle screws, and inter-transverse fusion using autogenous bone grafts (from the spinous process). There was no intra-operative fluoroscopic guidance during the entire procedure.

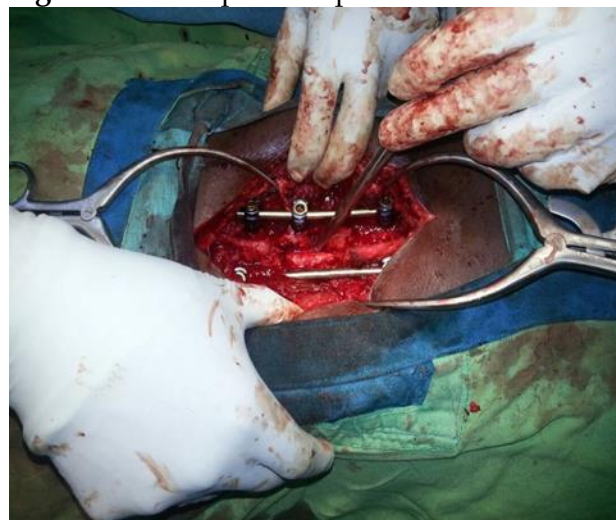
The patient's motor power improved at the second post-operative week (L2: 2/5). At the eight post-operative week, power at L2 was 4/5; L3: 3/5, L4: 3/5; L5: 3/5 and S1:2/5. Patient could now stand without support. Physiotherapy was begun at the second day

post-operative day and was continued thereafter. Patient was mobilized on a Zimmer's frame, and was discharged on the 9<sup>th</sup> week post-surgery. The ASIA score improved to D. On follow up visit at 6 months, patient could ambulate with a cane, but was yet to return to work.

**Figure 1.** Lumbosacral X-ray of patient



**Figure 2.** Intra-operative picture



## DISCUSSION

The management of traumatic lumbar spinal injury remains challenging especially in

resource constrained environments where lack of health insurance coupled with dearth of manpower exists.<sup>4</sup>

Stabilization of the unstable injured spine plays an important role in preventing further injury. In a patient with spinal cord injury, injury to the neural structures occurs both by primary, non-modifiable factors (occurring at the time of injury) and secondary, potentially modifiable factors (occurring within a finite period).<sup>5</sup>

Lumbar spine injuries can be managed by non-operative or operative methods. Non-operative methods are traditionally done for stable fractures (including simple compression or stable burst fractures without neurological injury).<sup>6</sup> It includes bed rest, use of commercially available thoracolumbar orthoses or a hyper-extension cast that can permit early ambulation. However, it has been shown that external support has no mechanical stabilizing effect over the lumbar spine.<sup>7</sup> A systematic review by Giele *et al.* concluded that there is no evidence for bracing in patients with traumatic thoracolumbar fractures.<sup>8</sup>

The advantage of operative treatment of thoracolumbar fractures over the non-operative approach include avoiding an orthosis in the presence of multiple injuries (including skin injuries), immediate mobilization and early rehabilitation, and a better restoration of sagittal alignment.<sup>8</sup> Studies in animal models have demonstrated that neurological recovery is enhanced by early surgery, though this has not been proven in human studies with acute spinal cord injury.<sup>9</sup> The severity of neurological injury is determined by the extent of neuronal

injury incurred at the time of primary injury.<sup>3</sup> However, it is still worthwhile to consider early surgical decompression in patients with acute spinal cord injury in the presence of spinal cord compression, as this reliably provides a better environment for restoration of neurological injury.<sup>3</sup>

#### CONCLUSION

In a limited resource setting with both infrastructural and manpower deficiencies, there is a tendency to manage patients with lumbar spinal cord injury conservatively. Operative decompression (in the presence of neural compression) and stabilization may improve chances of neurological recovery.

#### REFERENCES

1. Owosina FA. Spine injuries in Nigeria. In: Adelola Adeloye, editor. Care of the injured: Proceedings of the first international postgraduate symposium of the West African College of Surgeons 1977: 100-107.
2. Solagberu BA. Spinal cord injuries in Ilorin, Nigeria. *West Afr J Med* 2002; 21(3): 230-232.
3. Rajasakaran S, Mugesh R, Ajoy P. Management of thoracolumbar spine trauma: An overview. *Indian J Orthop* 2015; 49(1): 72-82.
4. Mwake E, Nyati M, Orwotho N, Mugarura R. Oesophageal perforation in anterior spine plating: a case report. *East Central Afr J Surg* 2011; 16(3): 125-128.
5. Bunge PP, Puckett WR, Becarra JL, Marath A, Quencer RM. Observation on the pathology of human spinal cord injury. A review and classification of 22 new cases with details from a case of chronic cord compression with extensive focal demyelination. *Adv Neurol* 1993; 59: 75-89.
6. Mumford J, Weinstein JN, Spratt KF, Goel VK. Thoracolumbar burst fractures: The clinical efficacy and outcome of non-operative management. *Spine (Phila Pa 1976)* 1993; 18: 955-70.
7. Shen WJ, Shen YS. Non-surgical treatment of three column thoracolumbar junction burst fractures without neurological deficit. *Acta Orthop* 2013; 78: 133-137.
8. Giele BM, Wiertsema SH, Beelen A, Lucas C, Been HD, Vander Schaaf M *et al.* No evidence for the effectiveness of bracing in patients with thoracolumbar fractures. *Acta Orthop* 2009; 80: 226-232.
9. Fehlings MG, Penri RG. The role and timing of early decompression for cervical spinal cord injury: update with a review of recent clinical evidence. *Injury* 2005; 36(2): 13-26.