

## ORIGINAL ARTICLE

# Relationship between Hormonal Profile and Therapeutic Testicular Biopsy/ TESE Findings in Azoospermic Men

Chimaobi G OFOHA  
Nuhu K DAKUM

Division of Urology  
Department of Surgery  
Jos University Teaching  
Hospital/  
College of Health Sciences  
University of Jos  
Jos, NIGERIA

### Author for Correspondence

Dr Chimaobi G OFOHA  
Department of Surgery  
Jos University Teaching  
Hospital/  
College of Health Sciences  
University of Jos  
Jos, NIGERIA

Phone number:  
+2348034502746  
Email: drchimao@yahoo.com.

Received: July 20<sup>th</sup>, 2019  
Accepted: January 22<sup>nd</sup>, 2020

### DISCLOSURE

No conflict of interest  
declared.

Nil financial support  
received for the study

### ABSTRACT

**Background:** Ten to twenty per cent of infertile men are azoospermic. Luteinizing hormone (LH), follicle-stimulating hormone (FSH) and testosterone, control development and maturation of the gonad as well as spermatozoa production. Understanding these hormonal interactions have significant clinical consequences in the evaluation and treatment of azoospermic men.

**Objective** To determine the pattern of hormonal derangement in azoospermic men, the histology of testicular tissue obtained at therapeutic testicular biopsy/ testicular sperm extraction (TESE) and the relationship between hormonal profile and histology of testicular tissue.

**Methodology:** This study was conducted on patients with infertility from 2015 to 2019 in a fertility centre in Jos, Nigeria. Clinical evaluation included history, physical examination and seminal fluid analyses. Azoospermic men had hormonal profiles (FSH, LH, Prolactin and Testosterone) assay and subsequently counselled for therapeutic testicular biopsy/ testicular sperm extraction for artificial reproductive technology. Hormonal assay levels and histologic findings were analysed, using SPSS version 23.

**Results:** Twenty-nine (n=29) men with azoospermia were analysed in this study. The mean age was 36.97±8.28 years with a range of 24-56years. Eight patients (n=8, 27.59%) had normal spermatogenesis while twenty-one patients (n=21, 72.41%) had various forms of abnormality, the commonest being spermatogenic arrest 31%. All patients with normal spermatogenesis (27.59%) and spermatogenic arrest at spermatocyte level(24.14%) had normal FSH and LH levels. FSH showed a strong correlation with testicular function, LH showed strong correlation while Prolactin showed negligible correlation.

**Conclusion:** Hormonal profile of azoospermic men can provide an insight into the possibility of testicular sperm retrieval. Normal hormonal levels do not indicate adequate testicular sperm (spermatogenic arrest at spermatocyte level) at therapeutic testicular biopsy/TESE. Elevated hormonal levels, however, indicate various forms of impaired spermatogenesis, these men should be advised to have donor sperm backup for ICSI.

**Keywords:** Infertility, Azoospermia, Hormonal profile, FSH, LH, Therapeutic testicular biopsy, TESE

## INTRODUCTION

The propagation of any specie depends on its ability to reproduce, more so humanity and especially in Africa where it is a sociocultural norm to reproduce. Infertility is defined as the inability of a couple to conceive despite regular unprotected sexual intercourse or therapeutic donor insemination, usually for one year or more.<sup>1,2</sup> In the general population, up to 15% of couples are infertile.<sup>3</sup> In Africa, male factor infertility accounts for 50% of this problem.<sup>4,5</sup>

The absence of spermatozoa in two consecutive seminal samples or centrifuged semen aptly describes azoospermia. Ten to twenty per cent of infertile men are azoospermic.<sup>6</sup> Causes of azoospermia include infections, idiopathic epididymal obstruction, congenital absence of the vas deference, germ cell aplasia, hormone problems, history of mumps orchitis, lifestyle or environmental factors, varicocele and genetic abnormalities.<sup>6,7</sup>

The production of sperm and androgens by the testis is under endocrine control. Luteinizing hormone (LH) and follicle-stimulating hormone (FSH) are glycoprotein hormones secreted by the pituitary gland. They control development, maturation and function of the gonad. It is assumed that either testosterone or FSH alone can initiate, maintain and reinitiate spermatogenesis.<sup>8</sup> Understanding these hormonal interactions have significant clinical consequences in the evaluation and treatment of azoospermic men.

Testicular biopsy was the main investigative modality for assessing men with azoospermia and normal testicular volume however with the advent of in-vitro fertilization(IVF), there is a growing trend towards therapeutic testicular biopsy/ sperm

retrieval and sperm banking in the management of azoospermic men.<sup>9</sup> The current emphasis with assisted reproductive technologies (ARTs) is on identifying motile sperm in the semen, or of elongated spermatids in testicular tissue during therapeutic biopsy or testicular sperm extraction (TESE) for intracytoplasmic sperm injection (ICSI).<sup>10</sup>

Infertility is a sociocultural problem with a negative impact on the couple. It is associated with anguish, shame, isolation and embarrassment. Family pressure contributes significantly to the stress felt by the couple. Thus, an adequate evaluation will provide a proper guide for appropriate treatment, which will bring succor and help in relieving the pressure on these patients.

The objective of this study is to determine the pattern of hormonal derangement in azoospermic men, the histology of testicular tissue obtained at therapeutic testicular biopsy/ testicular sperm extraction (TESE) and the relationship between hormonal profile and histology of testicular tissue. These will help in counselling patients appropriately in terms of testicular sperm extraction vis-a-viz in vitro fertilization and donor insemination.

## METHODOLOGY

This was a retrospective study conducted in a fertility centre in Jos, Nigeria. It involved patients that presented with infertility from 2015 to 2019. Clinical evaluation included history, physical examination and seminal fluid analyses. Azoospermic men (Azoospermia was diagnosed after microscopic examination of the ejaculate) were subjected to further evaluation. They had hormone profiles (FSH, LH, Prolactin and Testosterone assay) using the Ichroma

TM automatic immunoassay analyser. The patients were counselled and written informed consent obtained before open therapeutic testicular biopsy/ sperm retrieval, which was performed synchronously by the same surgeon. Testicular samples for analyses were fixed in Bouin's solution, while samples for ART were used immediately or banked.

The histologic parameters were recorded (normal spermatogenesis, hypo-spermatogenesis, spermatogenic arrest at spermatogonia level, spermatogenic arrest at spermatocyte level, absent spermatogenesis: testicular atrophy and Sertoli cell-only - descriptive classification of human spermatogenesis).<sup>11</sup> Hormone assay levels were recorded. Data were analysed using statistical package for the social sciences (SPSS) version 23. The relationship between hormone assay and testicular histology were derived using the ETA correlation.

**RESULTS**

Twenty-nine (n=29) men with azoospermia were analysed in this study. The mean age was 36.97±8.28 years with a range of 24-56years. Eight patients (n=8, 27.59%) had normal spermatogenesis while twenty-one patients (n=21, 72.41%) had various forms of abnormality. The findings on the histology of therapeutic testicular biopsy/TESE are depicted in Figure 1.

The mean values of hormone profile and other measures of central tendencies are shown in Table 1. The normal values for the hormone profiles are as follows; follicle-stimulating hormone (1-14miu/ml), luteinizing hormone (2-15miu/ml), testosterone (2.5-10ng/ml) and prolactin (0.94-11.4ng/ml).

All patients with normal spermatogenesis (n=8, 27.59%) and spermatogenic arrest at spermatocyte level (n=7, 24.14%) had normal FSH and LH levels. The hormone profile levels and findings on therapeutic testicular biopsy/ TESE are shown in Table 2.

The correlation between the hormone profile levels and histology of testicular tissues using the ETA correlation is shown in Table 3. FSH showed a strong correlation with testicular function, LH showed strong correlation while PRL showed negligible correlation.

**DISCUSSION**

Spermatogenic arrest, which is the disruption of the process of germ cell differentiation was the commonest abnormality followed by testicular atrophy in the index study. Overall, thirty-one per cent of the patients had spermatogenic arrest, with 24% having spermatogenic arrest at the spermatocyte level and 7% at spermatogonia level.

In the study of azoospermic men by Al-Dabbagh *et al.*, maturation arrest was 58.2%, these patients showed no spermatozoa with

**Table 1.** Mean values of the hormone profile

Variables	Mean	Median	Mode	Range	Minimum	Maximum
FSH	25.57	13.80	4.00	193.90	1.20	195.10
LH	7.55	6.30	5.00	15.50	2.60	18.10
Testosterone	9.42	8.50	6.10	25.20	1.50	26.70
PRL	25.22	9.51	6.10	400.20	1.00	401.20

**Table 2.** Showing the hormone profile level and therapeutic Testicular biopsy/ TESE findings (n=29)

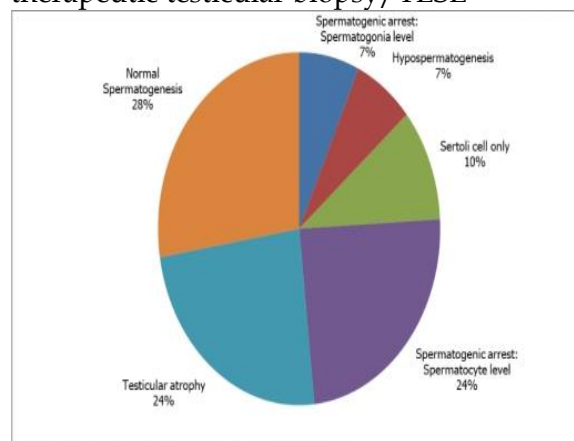
Hormonal Profile	Therapeutic testicular biopsy/ TESE findings					
	Normal Spermatogenesis	Hypospermatogenesis	Spermatogenic arrest. Spermatocyte level.	Absent Spermatogenesis. Testicular Atrophy	Spermatogenic arrest. Spermatogonia level.	Sertoli cell only
<b>FSH</b>						
1-14	8(27.59%)	0	7(24.14%)	0	0	0
15-28	0	0	0	6(20.69%)	2(6.90%)	3(10.35%)
>28	0	2(6.90%)	0	1(3.45%)	0	0
<b>Total</b>	8(27.59)	2(6.90%)	7(24.14%)	7(24.14)	2(6.70%)	3(10.35%)
<b>LH</b>						
1-15	8(27.59%)	2(6.90%)	7(24.14%)	6(20.69%)	1(3.45%)	3(10.35%)
16-30	0	0	0	1(3.45%)	1(3.45%)	0
<b>Total</b>	8(27.59%)	2(6.90%)	7(24.14%)	7(24.14%)	2(6.90%)	3(10.35%)
<b>Testosterone</b>						
8(27.59%)	8(27.59%)	0	3(10.34%)	6(20.69%)	1(3.45%)	1(3.45%)
1-10	0	2(6.90%)	3(10.34%)	0	1(3.45%)	1(3.45%)
11-20	0	0	1(3.45%)	1(3.45%)	0	1(3.45%)
21-30	8(27.59%)	2(6.90%)	7(24.15%)	7(24.14%)	2(6.90%)	3(10.35%)
<b>Total</b>	8(27.59%)	2(6.90%)	7(24.15%)	7(24.14%)	2(6.90%)	3(10.35%)
<b>Prolactin</b>						
1-11.4	5(17.24%)	2(6.90%)	4(13.80%)	5(17.24%)	1(6.90%)	1(3.45%)
11.5-22.8	2(6.90%)	0	1(3.45%)	2(6.90%)	1(6.90%)	3(10.35%)
>22.9	1(3.45%)	0	1(3.45%)	0	0	0
<b>Total</b>	8(27.59%)	2(6.90%)	6(20.69%)	7(24.14%)	2(6.90%)	4(13.80)

**Table 3.** Showing the relationship between hormone profile levels and abnormal testicular biopsy/ TESE findings (n=29)

Variables	Abnormal testicular biopsy findings (r)	P-value
FSH	0.989	0.989
LH	0.770	0.770
Testosterone	0.545	0.545
PRL	0.284	0.284

presence of immature germ cells, including several primary spermatocytes and spermatids.<sup>11</sup> Sertoli cell-only had 26 per cent incidence followed by testicular atrophy with 18 per cent incidence in a study by Purohit *et al.*, while Parikh *et al.*

**Figure 1.** Showing findings on histology of therapeutic testicular biopsy/ TESE



reported Sertoli cell-only syndrome (SCOS) as the most common lesion (18.75 %) followed by maturation arrest and testicular atrophy (11.25 % each).<sup>12,13</sup> These findings

showed that there is no particular pattern of histologic abnormality in azoospermic men.

In this study, the mean age was  $36.97 \pm 8.28$  years with a range of 24-56 years. This is similar to the finding by Tournaye *et al.* who had a mean age of  $39.1 \pm 7.6$  years and a range of 21 to 69 years in men undergoing testicular biopsies for sperm retrieval.<sup>14</sup>

Gonadotropic cells of the anterior pituitary produce and secrete gonadotropins; luteinizing hormone (LH) and follicle-stimulating hormone (FSH). These hormones play a critical role in the control of gonadal function. Under physiological condition, it is expected that patients with normal spermatogenesis at testicular biopsy should have normal hormone profiles. This correlates with the findings of this study, all the patients with normal spermatogenesis (n=8, 27.57%) had normal levels of FSH, LH and testosterone. It was also noted that patients with spermatogenic arrest at the spermatocyte level (n=7, 24.14%) had normal FSH and LH.

There is no definitive consensus on the role of FSH and LH on the postmeiotic spermatogenic stages. Some studies ascertain that these stages are FSH and LH independent and may be associated with normal levels of FSH and LH.<sup>15,16</sup> However, in a review of hormonal regulation of male germ cell development, the role of FSH and LH in the maintenance of human spermatogenesis showed some indications that FSH and LH (or intratesticular androgens) support postmeiotic spermatogenic stages.<sup>17,18,19</sup> Although many groups have not demonstrated a relationship between testicular histology and sperm retrieval rate, some groups argue that a prior testicular biopsy may help to determine the sperm retrieval success during therapeutic

testicular biopsy/TESE in patients with a normal hormonal profile.<sup>20,21</sup>

Abnormal testicular findings (hypospermatogenesis, spermatogenic arrest at spermatogonia level, absent spermatogenesis: testicular atrophy and Sertoli cell-only) were associated with elevated FSH and LH in this study. von Eckardstein *et al.* noted that the elevations of FSH correlates with the number of seminiferous tubules lacking germ cells but lacks predictive value for the actual histological type while Lei *et al.* noted that FSH and LH levels were significantly higher in patients with Sertoli-cell-only (SCO) syndrome and severe hypospermatogenesis than in those with normal spermatogenesis.<sup>22,23</sup>

The possible mechanisms for the high hormonal profile in azoospermic men include; the action of a hypothalamic FSH releasing hormone (activin) distinct from Gonadotropin releasing hormone (GnRH), an alteration in the pattern of GnRH pulses, a differential sensitivity of FSH and LH to sex steroid feedback inhibition and inhibin deficiency.<sup>24</sup>

A significant correlation between histologic findings of testicular tissues and levels of FSH, LH, testosterone and prolactin has been established.<sup>21</sup> However, in the index study FSH and LH showed a strong correlation ( $r=0.989$  and  $r=0.770$  respectively) with testicular findings in azoospermic men while testosterone showed moderate correlation ( $r=0.545$ ).

Prolactin had a negligible correlation. Loss of germ cells, tubular shrinkage and interstitial fibrosis, showed a very good correlation with high LH and FSH levels. However, plasma testosterone levels did not correlate with any

histologic structure of the testicular parenchyma.<sup>25</sup> Testicular biopsy as a diagnostic procedure may not be necessary for patients with elevated levels of hormone profile, as these significantly correlates with abnormal testicular finding. These patients should be counselled to have donor sperm as a backup during therapeutic testicular biopsy/ testicular sperm extraction.

### CONCLUSION

Hormonal profile of azoospermic men can provide an insight into the possibility of testicular sperm retrieval. Normal hormonal level does not indicate adequate testicular sperm (spermatogenic arrest at spermatocyte level) at therapeutic testicular biopsy/TESE. Elevated hormonal level however, indicates various forms of impaired spermatogenesis and correlates strongly with histologic diagnosis in azoospermic men. These men should be advised to have donor sperm backup for ICSI.

### REFERENCES.

1. Zegers-Hochschild F, Adamson GD, de Mouzon J, Ishihara O, Mansour R, Nygren K, et al. International Committee for Monitoring Assisted Reproductive Technology., World Health Organization. *Fertil Steril* 2009 ; 92(5):1520-1524.
2. Practice Committee of the American Society for Reproductive Medicine. Definitions of infertility and recurrent pregnancy loss: a committee opinion. *Fertil Steril* 2013;99(1):63.
3. Iammarrone E, Balet R, Lower AM, Gillott C, Grudzinskas JG. Male Infertility. *Best Pract Res Clin Obstet Gynaecol* 2003;17 (2):211-229.
4. Agarwal A, Mulgund A, Hamada A, Chyatte MR. A unique view on male infertility around the globe. *Reproductive*

*Biology and Endocrinology* 2015;13(1):37-46.

5. Ikechebelu JI, Adinma JI, Orié EF, Ikegwuonu SO. High prevalence of male infertility in South-eastern Nigeria. *Obstet Gynaecol* 2003; 23(6):657-659.
6. Hernández UL, Hernández M, Cervera-Aguilar R, Ayala AR. Frequency and aetiology of azoospermia in the study of infertile couples. *Gynaecol Obstet Mex* 2001; 69:322-326.
7. Wosnitzer M, Goldstein M, Hardy MP. Review of azoospermia. *Spermatogenesis* 2014;4(1):e28218-7.
8. Oduwolé OO, Peltoketo H, Huhtaniemi IT. Role of follicle-stimulating hormone in spermatogenesis. *Frontiers in Endocrinology* 2018;9:763.
9. Dohle GR, Elzanaty S, Van Casteren NJ. Testicular biopsy: clinical practice and interpretation. *A J Andro* 2012;14(1):88.
10. McLachlan RI, Rajpert-de Meyts E, Hoei-Hansen CE, de Kretser DM, Skakkebaek NE. Histological evaluation of the human testis—approaches to optimizing the clinical value of the assessment: mini review. *Hum Reprod* 2007;22(1):2-16.
11. Al-Dabbagh AA, Ahmed BS. Testicular Fine Needle Aspiration Cytology versus Open Biopsy in the Evaluation of Azoospermic Men. *Open J Urol* 2015; 5(09):133-141.
12. Purohit TM, Purohit MB, Dabhi BJ. Study of semen analysis and testicular biopsy in the infertile male. *Indian J Pathol Microbiol* 2004; 47(4):486-490.
13. Parikh UR, Goswami HM, Deliwala KJ, Shah AM, Barot HP. Testicular Biopsy in Male Infertility: Study of 80 Cases. *JIMSA* 2012; 25(2): 75-77.
14. Tournaye H, Liu J, Nagy PZ, Camus M, Goossens A, Silber S, et al. Correlation between testicular histology and outcome after intracytoplasmic sperm injection using testicular spermatozoa. *Human Reprod* 1996;11(1): 127-132.
15. Plant TM, Marshall GR. The functional significance of FSH in spermatogenesis

- and the control of its secretion in male primates. *Endocrine Reviews* 2001; 22(6):764-786.
16. Bergmann M, Behre HM, Nieschlag E. Serum FSH and testicular morphology in male infertility. *Clin Endocrinol* 1994;40(1):133-136
  17. Ruwanpura SM, McLachlan RI, Meachem SJ. Hormonal regulation of male germ cell development. *J Endo* 2010; 205(2):117-131.
  18. Matthiesson KL, McLachlan RI, O'Donnell L, Frydenberg M, Robertson DM, Stanton PG, *et al.* The relative roles of follicle-stimulating hormone and luteinising hormone in maintaining spermatogonial maturation and spermiation in normal men. *J Clin Endo Metab* 2006; 91(10):3962-3969.
  19. Foresta C, Bettella A, Ferlin A, Garolla A, Rossato M. Evidence for a Stimulatory Role of Follicle-Stimulating Hormone on the Spermatogonial Population in Adult Males. *Fertility and Sterility* 1998;69(4):636-642.
  20. Gudeloglu A, Parekattil SJ. Update in the evaluation of the azoospermic male. *Clinics* 2013;68(S1):27-34.
  21. Ramasamy R, Schlegel PN. Microdissection testicular sperm extraction: effect of prior biopsy on success of sperm retrieval. *J Urol* 2007;177(4):1447-1449.
  22. Bohring C, Schroeder-Printzen I, Weidner W, Krause W. Serum levels of inhibin B and follicle-stimulating hormone may predict successful sperm retrieval in men with azoospermia who are undergoing testicular sperm extraction. *Fertility and Sterility* 2002;78(6):1195-1198.
  23. Lei B, Lv D, Zhou X, Zhang S, Shu F, Ding Y *et al.* Biochemical hormone parameters in seminal and blood plasma samples correlate with histopathologic properties of testicular biopsy in azoospermic patients. *Urology* 2015;85(5):1074-1078.
  24. Matin-du-Pan RC, Bischof P. Increased follicle stimulating hormone in infertile men. *Human Repro* 1995;10 (8):1940-1945.
  25. Lardone MC, Piottante A, Valdevenito R, Ebensperger M, Castro A. Histological and hormonal testicular function in oligo/azoospermic infertile men. *Andrologia* 2013;45(6):379-385.