

## ORIGINAL ARTICLE

## Effectiveness of the Ponseti Technique in the Management of Clubfoot

Henry O OBIEGBU<sup>1</sup>  
Christopher C  
NDUKWU<sup>2</sup>  
Titus O  
CHUKWUANUKWU<sup>3</sup>

<sup>1</sup>Orthopaedic Surgery Unit

<sup>2</sup>Orthopaedic Surgery Unit

<sup>3</sup>Plastic Surgery Unit

Department of Surgery  
Nnamdi Azikiwe University  
Teaching Hospital Nnewi  
Anambra State, NIGERIA

**Author for Correspondence**

Dr Henry Obinna

**OBIEGBU**

Department of Surgery  
Nnamdi Azikiwe University  
Nnewi campus  
Anambra state, NIGERIA

Phone: +234 8033827517

Email:

obinnaobiegbu@yahoo.com

Received: March 27<sup>th</sup>, 2019

Accepted: June 4<sup>th</sup>, 2019

**DISCLOSURE**

The authors declare no conflict of interest

**INTRODUCTION**

Club foot also known as congenital idiopathic talipes equinovarus is not an embryonic malformation.<sup>1</sup> It occurs when a normally developing foot turns into the

shape of a club during the second trimester of pregnancy. It is of an unproven aetiology.

It may be unilateral or bilateral. The pathological changes seen in club foot include both bony deformities (particularly of the talus) and soft tissue contractures. The

**ABSTRACT**

**Background:** Clubfoot is a common developmental anomaly of the musculoskeletal system and it remains a burden to developing countries due to lack of appropriate medical care, poverty and ignorance. The Pirani scoring system is an instrumental tool for assessing both the severity of the deformity, and the progress of treatment.

**Objectives:** To determine the effectiveness of the Ponseti technique in clubfoot correction in our centre.

**Methodology:** This was a prospective study carried out in a tertiary hospital. Ethical clearance was obtained from the hospital Ethics Committee. Patients who met the inclusion criteria were randomly selected. The Pirani score of all feet were obtained before initial manipulation was commenced, and was also done at each follow up visit until correction was achieved.

**Results:** A total of 50 patients (64 clubfeet) were recruited. The mean Pirani score at presentation was  $4.33 \pm 1.56$  while the mean number of casts used for correction was  $7.61 \pm 2.87$ . Clubfoot correction using the Ponseti technique was achieved in 58 (90.6%) clubfeet. Tenotomy was done in 37 (57.8%) clubfeet.

**Conclusion:** From the results of this study, it is concluded that the Ponseti technique is an effective method for clubfoot correction. The Pirani scoring system is also an effective tool in monitoring progress obtained in the clubfoot during correction. It is therefore recommended that the Ponseti technique be used routinely in the treatment of clubfoot.

**Keywords:** CTEV, Ponseti technique, Pirani score, Congenital feet malformation

bony deformities affect the tarsal bones which in the early stages are cartilaginous and are easily moulded in extreme positions of flexion, adduction and inversion at birth. Clubfoot is characterized by equinus, varus, adduction and cavus deformities, affecting individual bones of the foot, the joints of the foot and also soft tissues.

Divergent views exist with regards to management of this malformation; as to what population that should be managed by closed non operative methods instead of an operative method.<sup>2</sup> Over the past few decades, there has been extensive research regarding the appropriate treatment of clubfoot. Historically, surgical correction, specifically an extensive posteromedial soft tissue release was the mainstay of treatment.<sup>3</sup> This intervention however has been shown to result in scarring, joint stiffness, muscle weakness and gait disturbances.<sup>3</sup> Additionally, complications including wound infections, skin necrosis and neurovascular injuries have been reported. Furthermore, the deformity can be over or under-corrected and the talus may become flattened or even end up in necrosis.<sup>4,5</sup>

Given the potential devastating complications and sometimes discouraging long term results, treatment preferences have since changed to primarily a non-operative approach via the Ponseti method. The Ponseti technique which involves closed manipulation and application of well moulded plaster casts is considered to offer the best and safest correction of most club feet in infants.<sup>2</sup> The Ponseti technique of club foot management has gained considerable popularity in the last decade with a success rate of over 90%.<sup>6</sup>

Even though there is no agreed method of grading severity, monitoring the natural history or accessing relapse of clubfoot, the Pirani scoring system is useful, especially in

grading the initial extent of deformity and the progress of foot correction. Pirani *et al.* devised a simple scoring system based on six clinical signs of contracture.<sup>7</sup> Each is scored according to the following principle:

- 0: no abnormality
- 0.5: moderate abnormality
- 1: severe abnormality

The six signs are separated into three, related to the hind foot (severity of posterior crease, emptiness of the heel and rigidity of the equines) and three, related to the midfoot (curvature of the lateral border of the foot, severity of the medial crease and position of the lateral part of the head of the talus).

The objective of this study was to determine the effectiveness of the Ponseti method in the management of clubfoot.

#### METHODOLOGY

This was a prospective study done at the orthopaedic outpatient department of Nnamdi Azikiwe University Teaching Hospital Nnewi, Anambra state. All new patients diagnosed of clubfoot without the under listed exclusion criteria were enrolled.

Those with neglected clubfoot (i.e. above two years of age), prior treatment of their clubfoot (conservative or surgical), clubfoot as part of a syndrome and those whose caregivers refused to give consent for the study were excluded.

Approval for the study was obtained from the Institutions Ethics Review Board before commencing the study.

After diagnosis of clubfoot had been made, the Pirani score of the affected foot (feet) was obtained and documented before serial manipulation and casting (Ponseti technique) was commenced. The standard Ponseti technique was used and high groin cast applied.<sup>7</sup> The tenotomy if required was

done under local anaesthesia as an outpatient procedure. The casts before the tenotomy was changed at weekly intervals, while the cast after the tenotomy was changed at the end of three weeks.

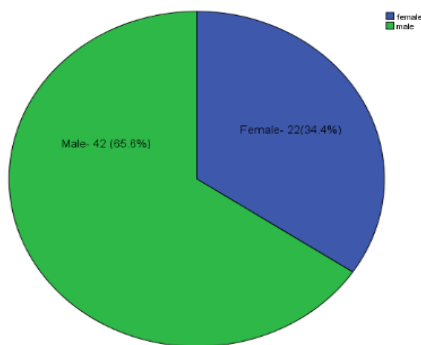
**RESULTS**

A total of 50 patients (64 clubfeet) were enrolled into this study and their data analysed. The age range of the patients is 2-17 months, with a mean age of 1.42 months.

**Table 1.** Age distribution of the patients

Age (months)	Frequency	Percent
0-6	42	65.6
7-12	17	26.6
13-18	5	7.8
<b>Total</b>	<b>64</b>	<b>100.0</b>

**Figure 1:** Sex Distribution of the patients



This shows a male preponderance with a male to female ratio of 1.7:1

**Table 2:** Mean of test Variables

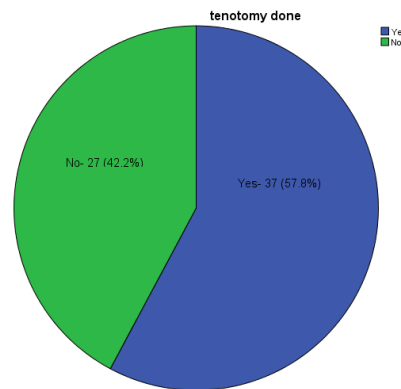
Variables	Mean ± Standard deviation
Number of casts	7.61±2.87
Midfoot score at presentation	2.1 ±0.94
Hindfoot score at presentation	2.2 ±0.75
Pirani score at presentation	4.33±1.56

Table 2 showed the mean number of casts applied, midfoot and hindfoot scores on presentation and the mean Pirani score on presentation.

**Table 3:** Overall correction rate of Clubfoot using the Ponseti technique

	Freq	Percent
Corrected	58	90.6
Un- corrected	6	9.4
<b>Total</b>	<b>64</b>	<b>100</b>

**Figure 2:** Showing percentage of feet that had tenotomy



**Table 4:** Correlation between Pirani score and tenotomy

Pirani score	Tenotomy	
	Done	Not done
	Freq (%)	Freq (%)
<4	6 (27.3)	16 (72.7)
≥4	31 (73.8)	11 (26.2)

P=0.001

Table 4 showed that subjects with Pirani score of ≥4 had more tenotomies (73.8%). This difference is statistically significant.

**DISCUSSION**

This was a prospective study on the effectiveness of the Ponseti method in the management of idiopathic congenital talipes equinovarus. In this study, congenital talipes equinovarus (CTEV) was found to

occur within the age of 2-17 months with a peak age range of 0-6 months. This is similar to findings by Adewole *et al.* and Asuquo *et al.* where the most commonly involved age done by Asuquo *et al.* in their series.<sup>9</sup> This is in contrast to the study done by Birhanu *et al.* where the age range was from 2-10 years.<sup>9</sup> However, in the study by Birhanu *et al.* only subjects with neglected clubfoot were studied.<sup>9</sup>

This study also found a male preponderance with a male to female ratio of 1.7: 1, which is within the ratio reported by Asuquo *et al.* and Kazi *et al.*<sup>8,10</sup> However, the cause of the overall male preponderance of clubfoot is unknown, and questions of whether vascular disruption disproportionately affects males and contributes to the increase in males have been put forward.

The mean pre-treatment Pirani score in this study was  $4.33 \pm 1.56$ . This is similar to those reported previously.<sup>10,11,12</sup>

In our study, the mean number of casts used in the correction of clubfoot is  $7.61 \pm 2.87$ . This is similar to the findings by Aggarwal *et al.* where the overall mean number of casts used for clubfoot correction was 7.7.<sup>13</sup> This is also similar to the findings by Laaveg and Ponseti.<sup>14</sup> This was in contrast to a study done by Kazi *et al.*, where the mean number of casts used in their study was 3.75. This may be attributed to differences in the population studied (as only neonates were analysed in this study).

In our study, the mean pre-treatment Pirani score at presentation was  $4.33 \pm 1.56$ . This is similar to findings by Adewole *et al.*<sup>7</sup> However, a slightly higher score of 5.57 was found in the study by Kazi *et al.*<sup>10</sup> Also, in a study by Matar *et al.*, a mean pre-treatment Pirani score of 5.5 was found.<sup>15</sup> However in this Matar's study, only subjects with arthrogryptic talipes equinovarus deformity were studied.

bracket was also between 0-6 months of age.<sup>7,8</sup> Similarly, the mean age of 1.4 months found in this study also agrees with studies

In this our study, the Ponseti technique was found to be effective in the management of clubfoot with a correction rate of 90.6%. In a similar study by Kazi *et al.*, 96.6% of their patients were managed successfully using the Ponseti technique.<sup>10</sup> In the study by Matar *et al.*, satisfactory outcome (painless, plantigrade feet) was achieved in 83.3%, however the study population were children with clubfoot associated with myelomeningocele.<sup>16</sup>

## CONCLUSION

The Ponseti technique is effective in the management of congenital talipes equinovarus, giving rise to a painless plantigrade foot in a majority of cases without the need for an extensive soft tissue or bony surgery.

## REFERENCES

1. Ponseti IV. Current concepts review: treatment of congenital club foot. *J Bone J Surg Am* 1992; 74(3):448-454.
2. Aronson J, Puskarich C. Deformity and disability from treated club foot. *J Pediatr Orthop* 1990; 10:109
3. Kessler JL. A new flexible brace used in the Ponseti treatment of talipes equinovarus. *J Pediatr Orthop B* 2008; 17(5): 247-250
4. Crawford AH, Gupta AK. Clubfoot controversies, complications and causes for failure. *Instr Course Lect* 1991; 45: 339-346
5. Abdelgawad AA. Treatment of idiopathic clubfoot using the Ponseti method. Minimum 2 year follow up. *J Pediatr Orthop B* 2007; 16(2):98-105
6. Ponseti IV. Clubfoot management. *J Pediatr Orthop.* 2000; 20:699-700
7. Adewole OA, Giwa SO, Williams OM, Kayode MO. Early experience with

- Ponseti clubfoot management in Lagos, Nigeria. *East Cent Afr J Surg* 19; 74-78
8. Asuquo J, Abang I, Anisi C, Uroni S, Agwaye P, Okeke N. Descriptive epidemiology and predisposing factors to idiopathic talipes equinovarus in South-South Nigeria. *Joint Pub Hea Ed* 2016; 8(8): 147-151
  9. Birhanu A, Peter J. Good results after Ponseti treatment for neglected congenital clubfoot in Ethiopia. *Acta Orthop* 2014; 85 (6): 641-645
  10. Kazi F, Ullah S, Sayed A. Management of congenital talipes equinovarus by Ponseti casting technique in neonates. *J Neonatal Surg* 2013; 2(2):17-21
  11. Dobbs MB, Rudzki JR, Purcell DB, Walton T, Porler KR. Factors predictive of outcome after use of the Ponsetti method for the treatment of idiopathic club feet. *J Bone Joint Surg Am* 2004; 86-A; 22-7
  12. Idelberger KZ. Ultrasound imaging of the fetus with clubfoot. *Orthop* 1939; 691-693
  13. Aggarwal D, Gupta N. The role of Pirani scoring system in the management and outcome of idiopathic clubfoot by the Ponseti method. *Int Journ Sc Res* 2013 (6): 2319-2322
  14. Laaveg SJ, Ponseti IV. Long-term results of treatment of congenital club foot. *J Bone J Surg Am* 1980;62-A:23-31.
  15. Matar HE, Garg NK. The effectiveness of the Ponseti method for treating clubfoot associated with arthrogryposis: up to 8 years follow up. *J Child Orthop* 2016 (1):15-18
  16. Matar HE, Beirne P, Garg NK. Effectiveness of the Ponseti method for treating clubfoot associated with myelomeningocele: 3-9 years follow-up. *J Pediatr Orthop B* 2017;26(2): 133-136