

CASE REPORT

An Unusual Case of Fracture of the Shaft of the Lateral Four Metatarsals with Dislocation of the Metatarso-Phalangeal Joint of the Big Toe Following a Trivial Trauma

Ifeanyi C NWAGBARA¹
Kingsley O OPARA²

¹Orthopaedic Surgery Unit

²Plastic Surgery Unit

Department of Surgery
Imo State University Teaching
Hospital
Orlu, Imo State
NIGERIA

Author for correspondence
Dr Ifeanyi C NWAGBARA
P.O Box 331
Ihiala, Anambra State
NIGERIA

Phone:+234 8033388292

Email: icnwagbara@gmail.com

Received: April 11th, 2018

Accepted: May 20th, 2018

DISCLOSURE

Source of funding- None
No conflict of interest

ABSTRACT

Metatarsal fractures are about the most common fractures seen in foot injuries. They are however under-reported. The fracture may occur as an isolated injury involving only one metatarsal, concurrently with fractures of additional metatarsals, or as Lisfranc injuries.

These injuries may occur as a result of repetitive stress, low energy trauma, sporting activities or as a result of major trauma as seen in road traffic accidents. The choice of treatment of metatarsal fractures can be either conservative or operative depending on anatomical region involved, patient history and radiological findings. The treatment outcome of these fractures is however not encouraging especially when multiple contiguous sites are involved.

This report looks at a case of fracture of the shaft of the lateral four metatarsals with an associated open dislocation of the first metatarso-phalangeal joint in a diabetic patient following a trivial injury, which was managed by open reduction and k-wire fixation.

Keywords: Foot trauma, Multiple metatarsal fractures, Pathologic fracture, Kirschner wire fixation, Diabetic foot.

INTRODUCTION

Metatarsal fractures are frequently encountered injuries of the foot.¹ They represent a common cause of forefoot pain, accounting for 5 to 6% of all fractures and 35% of all foot fractures.^{2,3,4,5} Fifth metatarsal fractures account for 68% of all cases.⁶ Any part of the metatarsal can be affected, thus metatarsal fractures are classified based on the region of occurrence into three groups:⁷

1. proximal or metaphyseal
2. diaphyseal or shaft
3. head and neck fractures.

The fractures may occur as an isolated injury, concurrently with fractures of additional metatarsals, or as Lisfranc injuries.

Lisfranc injuries are ligament injuries with associated fracture-dislocations involving the tarso-metatarsal (TMT) joints. The injury can be caused by both low energy trauma as seen in stress fractures, sports injuries and high energy crush injuries.^{8,9} Thus depending on the degree of violence, the injury may be purely ligamentous or associated with fractures of the metatarsals, cuneiforms, navicular and cuboid.^{6,10}

Fractures of the proximal 5th metatarsal deserve special mention. Sir Robert Jones was the first to describe a fracture of the proximal fifth metatarsal which he described as a fracture in the proximal three quarter segment of the shaft distal to the styloid.^{11,12}

The Jones fracture was later defined by Stewart as a transverse fracture at the junction of the diaphysis and metaphysis of the 5th metatarsal.^{13,14} Since then there has been a focus in the literature on fractures of the proximal fifth metatarsal due to the high incidence of poor healing of some fractures in this region. Fractures of the proximal fifth metatarsal are classified into three zones.^{15,16}

Tuberosity avulsion fractures represent zone one. Fractures at the metaphysis-diaphyseal junction represent zone two (Jones) fractures while zone three or diaphyseal stress fractures occur in the proximal 1.5 cm of the diaphysis.

Standard radiological imaging for a suspected metatarsal fracture includes three views of the foot: lateral, antero-posterior, and a 45 degree oblique. Acute stress fractures are typically not detected on the standard three views of the foot at the time of the injury. Repeat radiographs should be taken at 10 to 14 days after the initial onset of symptoms for these cases.¹⁷ At this time a radiolucent resorption gap around the fracture confirms the diagnosis.¹⁷ In cases of complex midfoot injury, a CT scan is recommended to rule out Lisfranc fracture/ dislocation.¹⁷

The choice of treatment of metatarsal fractures varies depending on the anatomical region, patient history and radiological findings. About 80% of the fractures are non-displaced or minimally displaced, which often makes conservative management appropriate. The available options for non-operative treatment include elastic dressing and a rigid shoe, short leg walking cast, posterior splint, or a hard plastic cast shoe with weight-bearing as tolerated.¹⁸

When significant displacement occurs however, operative treatment is required. The criteria cited is more than 10 degrees of plantar angulation or three to four millimeters of translation in any plane.¹⁹ For Lisfranc injuries on the other hand, the general consensus is that anatomical reduction and rigid stabilization of the Lisfranc joint through operation are necessary for good outcome.^{10,20} There is however some controversies surrounding the management of acute non-displaced Jones fractures. A number of studies

advocate early operative fixation for acute Jones fractures in the active population.^{21, 22}

Diaphyseal stress fractures of 5th metatarsal (zone three) are managed conservatively but often require prolonged immobilization of up to twenty weeks.¹³ Despite prolonged immobilization zone three diaphyseal stress fractures may still go on to non-union.

The modalities for operative management of metatarsal fractures include percutaneous fixation with an intramedullary screw, cortico-cancellous bone graft, closed reduction and cross-pinning with Kirschner-wire (K-wire) fixation, or open reduction and internal fixation with mini-fragment plate and screws.^{15,17}

Postoperatively the foot should be immobilized for a period of 1 to 2 weeks, with progressive weight bearing in a short-leg walking cast or air cast for four to six weeks.^{13,15,19} Subsequently, a functional brace or foot orthosis may be worn if the patient is returning to strenuous competitive activity.^{18,19} Following inlay cortico-cancellous bone grafting in Jones fractures, the foot should be immobilized for six weeks.¹⁹

In this report, a case of fractures involving the lateral four metatarsals and dislocation of the first metataraso-phalangeal joint of the left foot and its management was presented.

Case Presentation

A 66 year old patient, presented to the emergency room with a three hours history of injury to the left foot. The foot was swollen and very painful and the patient was unable to bear weight on the affected limb. He was said to have tripped and fell while walking in his compound. He had a pre-existing contra lateral hip pain and stiffness with an

associated limping gait. The hip pathology was due to gunshot injuries he sustained about 6 years earlier. He volunteered that because of the hip pathology, he depended mainly on the left foot for mobilization. Thus, when he tripped on the good limb, he could not support himself on the right limb, but rather fell awkwardly which resulted in the fracture. He was a known hypertensive and diabetic, both of which were under control with medication.

Examination revealed swollen dorsum of the left foot with an open dislocation of the first metatarso-phalangeal joint. The X-ray of the left foot showed normal bone stock with displaced fractures of the distal end of the shafts of the 2nd to 5th metatarsals and dislocation of the first metatarso-phalangeal joint (Figure 1). The X-ray of the right hip joint showed features of severe osteoarthritis.

He was subsequently worked up for surgery which took place the next day under spinal anaesthesia and mid- thigh tourniquet. He had wound debridement and reduction of the dislocated joint and the fractures. Each fracture site was exposed through a dorsal approach and reduction maintained with a Kirschner wire (Figure 2).

Subsequently, he was placed on antibiotics, analgesics, anti-hypertensives and oral hypoglycemic agents. The foot was immobilized in a back-slab and a non- weight bearing mobilization was commenced with the aid of a Zimmer frame. This was however with some difficulty because of the hip pathology in the contra-lateral limb.

In the immediate post-operative period he had a breakdown of the wound over the first metatarso-phalangeal joint. This was managed by wound debridement, followed by serial dressing changes and later split thickness skin

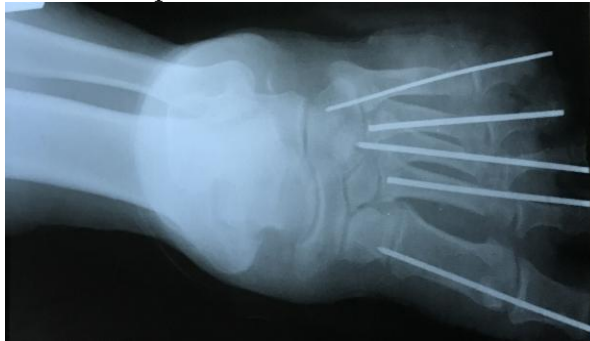
grafting. Following wound healing, graduated weight bearing was commenced and the fractures healed satisfactorily. The K-wires were removed after 6 weeks (Figures 3 & 4). Patient has since returned to pre-morbid functional status.

Figure 1. Pre-operative X-ray

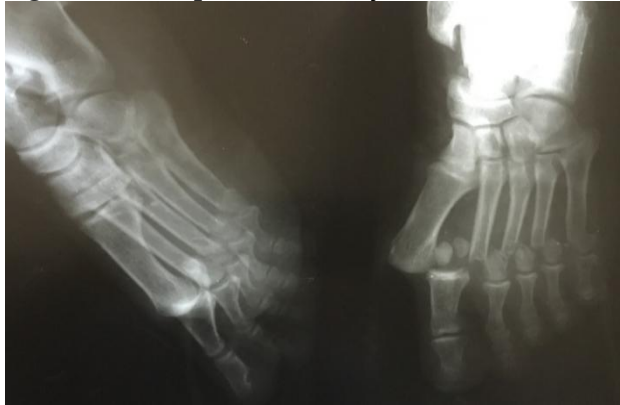

Figure 2. Immediate post-operative x-ray

2A. Antero-posterior view



2B. Oblique view

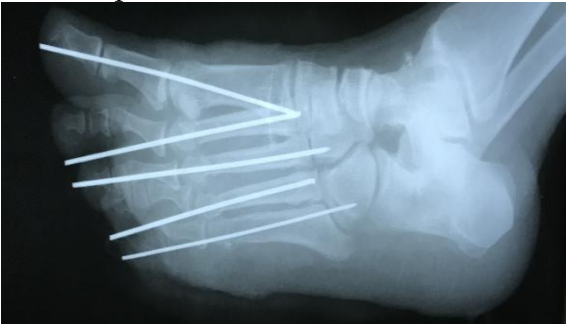


Figure 3. Six weeks post-operative X-ray

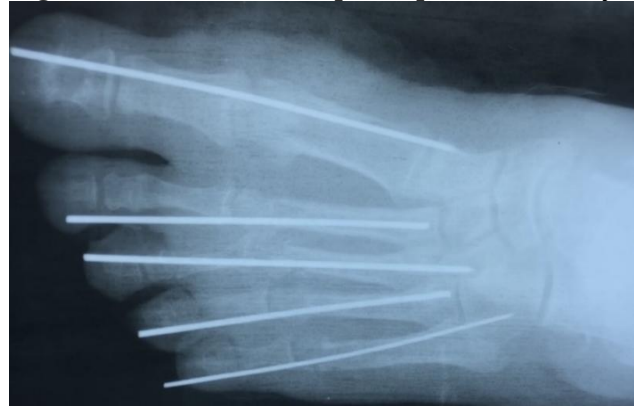
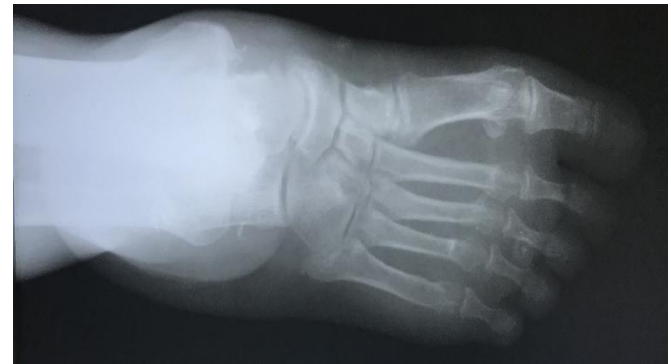
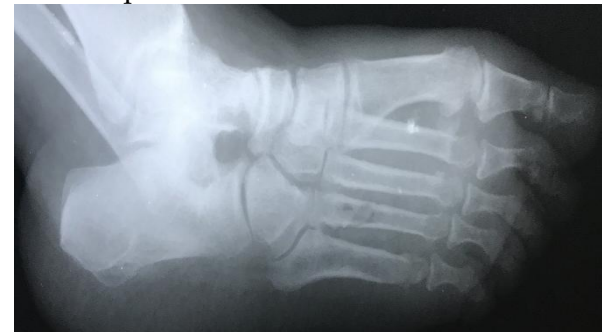
Figure 4. Six month's post-operative X-ray

4A. Antero-Posterior view



4B. Oblique view



DISCUSSION

Very few articles in the literature have addressed fractures involving multiple metatarsals. The mechanism of injury usually is a direct force as seen in motor vehicle accident, which is reported to be the most

common, and twisting forces as seen in the index case. Other causes include fall from height, assault, and repetitive stress. The patients usually present with pain, swelling, ecchymosis and inability to bear weight. Application of an axial load along the head of the metatarsals produces pain at the fracture site. In isolated soft tissue injuries, this test, the metatarsal loading test, is negative.²³

Most metatarsal fractures are oblique or transverse. Displacement of the fracture is usually minimal except with multiple fractures. This is because in isolated metatarsal fractures, adjacent metatarsals act as splints for the fractured metatarsal. In displaced fractures, the head of the metatarsal is usually displaced in a plantar direction as a result of traction from the flexor tendons and the intrinsic muscles of the foot.²⁴

The treatment of these fractures is aimed at restoring the alignment of the five metatarsals, thereby preserving the longitudinal and transverse arch of the forefoot. This helps to ensure a normal weight distribution under the metatarsal heads. If these objectives are not achieved, the common consequence is a disabling metatarsalgia.²⁵

Most non-displaced metatarsal shaft fractures are managed conservatively. This may require only soft elastic dressing or firm supportive weight bearing.^{26,27} Operative treatment is however indicated when there is significant displacement.^{26,28} This is also the case in multiple contiguous fractures as seen in the case under review. The recommended operative treatment protocol is closed reduction and percutaneous pinning through a dorsal approach.

Occasionally, however the displacement is severe enough to require open reduction and internal fixation. In both cases, care should be taken to re-align the toes in the sagittal plane, and this assessment is done primarily while

palpating the levels of the metatarsal heads to ensure they are in the same plane.²⁹ In the case under review, percutaneous pinning through the dorsal approach was employed with satisfactory outcome.

The outcome of treatment of metatarsal fractures is generally not encouraging. In a series by Alepuz *et al.* that considered 57 patients treated operatively and non-operatively for central metatarsal fractures, poor results were recorded in 39% of cases.³⁰

Only 32% of the patients had good results irrespective of the type of treatment. Baumfeld *et al.* however recorded an excellent result in the assessment of 15 patients with lesser metatarsal fractures managed by percutaneous antegrade pinning.³¹ They observed an American Orthopaedic Foot & Ankle Society [AOFAS] functional scores for the postoperative period, averaging more than 95 points, and no complications were identified related to the type of treatment used.

Similarly in the case under review, though there was significant displacement of all the metatarsals in the horizontal plane, a good result was obtained following the choice of treatment. The patient returned to pre morbid functional status within 3 months of the injury and has remained pain free as at the last review which was 8 months after the procedure.

The observed poor prognostic factors in metatarsal fractures include sagittal plane displacement, open fractures, severe soft tissue injury, obesity, female sex and diabetes mellitus.⁷ It has been observed that mid lateral plane displacement may be tolerated but sagittal plane displacement of a metatarsal head, either in extension or plantar flexion or excessive shortening of a metatarsal leads to metatarsalgia and chronic foot pain. Our patient was diabetic and this may have played a role in the wound breakdown involving the

big toe. The fractures however healed satisfactorily.

CONCLUSION

This reported case of multiple contiguous metatarsal fractures resulted in a good outcome following treatment by open reduction and percutaneous pinning.

REFERENCES

1. De Lee JC, Evans JP, Julian J. Stress fracture of the fifth metatarsal. *Am J Sports Med* 1983; 11:349– 353.
2. Petrison BA, Ekrol I, Court-Brown C. The epidemiology of metatarsal fractures. *Foot Ankle Int* 2006; 27:172–174.
3. Boutefnouchet T, Budair B, Backshayesh P, Ali SA. Metatarsal fractures: a review and current concepts. *Trauma*2014; 16 (3):147-163.
4. Hatch RL, Alsobrook JA, Clugston JR. Diagnosis and management of metatarsal fractures. *Am Fam Physician*2007; 76 (6):817-826.
5. Buddecke DE, Matthew A, Polk M A, Eric A, Barp EA. Metatarsal Fractures. *Clin Podiatr Med Surg*2010; 27: 601–624.
6. Petrison BA, Ekrol I, Court-Brown C. The epidemiology of metatarsal fractures. *Foot Ankle Int*2006;27:172–174.
7. Cakir H, Van Vliet-Koppert ST, Van Lieshout EM, De Vries MR, Van Der Elst M, Schepers T. Demographics and outcome of metatarsal fractures. *Arch Orthop Trauma Surg* 2011; 131(2):241-245.
8. Vuori JP, Aro HT. Lisfranc joint injuries: trauma mechanisms and associated injuries. *J Trauma*1993;35(1):40–45
9. Nithyananth M, Boopalan PR, Titus VT, Sundararaj GD, Lee VN. Long-term outcome of high-energy open Lisfranc injuries: a retrospective study. *J Trauma*2011;70(3):710–716.
10. Stavlas P, Roberts CS, Xypnitos FN, Giannoudis PV. The role of reduction and internal fixation of Lisfranc fracture-dislocations: a systematic review of the literature. *Int Orthop*2010;34(8):1083–1091.
11. Jones R. I. Fracture of the Base of the Fifth Metatarsal Bone by Indirect Violence. *Ann Surg*1902;35:697–700.2.
12. Armagan OE, Shereff MJ. Injuries to the toes and metatarsals. *Orthop Clin North Am*2001;32:1–10.
13. Zwitter EW, Breederveld RS. Fractures of the fifth metatarsal; diagnosis and treatment. *Injury*2010;41:555–562.
14. Stewart IM. Jones's fracture: fracture of base of fifth metatarsal. *Clin Orthop*1960;16:190–198.
15. Dameron TB. Fractures of the Proximal Fifth Metatarsal: Selecting the Best Treatment Option. *J Am Acad Orthop Surg*1995;3:110–114.
16. Dameron TB. Fractures and anatomical variations of the proximal portion of the fifth metatarsal. *J Bone Joint Surg Am*1975;57:788–792.
17. Rammelt S, Heineck J, Zwipp H. Metatarsal fractures. *Injury* 2004;35 Suppl 2:SB77–SB86.
18. Raikin SM, Slenker N, Ratigan B. The association of a varus hindfoot and fracture of the fifth metatarsal metaphyseal-diaphyseal junction: the Jones fracture. *Am J Sports Med* 2008;36:1367–1372.
19. Fetzer GB, Wright RW. Metatarsal shaft fractures and fractures of the proximal fifth metatarsal. *Clin Sports Med* 2006 ; 25:139–150.
20. Watson TS, Shurnas PS, Denker J. Treatment of Lisfranc joint injury: current concepts. *J Am Acad Orthop Surg*2010;18(12):718–728.
21. Porter DA, Duncan M, Meyer SJ. Fifth metatarsal Jones fracture fixation with a 4.5-mm cannulated stainless steel screw in the competitive and recreational athlete: a clinical and radiographic evaluation. *Am J Sports Med* 2005;33:726–733.
22. Mindrebo N, Shelbourne KD, Van Meter CD, Rettig AC. Outpatient percutaneous screw fixation of the acute Jones fracture. *Am J Sports Med*1993;21:720–723.
23. Hatch RL, Alsobrook JA, Clugston JR. Diagnosis and management of metatarsal fractures. *Am Fam Physician*2007;76(6):817-826.
24. Hatch R L, Alsobrook J A, Clugston J R. Diagnosis and Management of Metatarsal Fractures. *American Family Physician*2007; 76(6): 817-826.

25. Rammelt S, Heineck J, Zwipp H. Metatarsal fractures J. Injury 2004; 35, S-B77–S-B86
26. Eiff MP, Hatch RL, Calmbach WL. Fracture Management for Primary Care. 2nd ed. Philadelphia, Pa: Saunders; 2003. p.331-352.
27. Zenios M, Kim WY, Sampath J, Muddu BN. Functional treatment of acute metatarsal fractures: a prospective randomised comparison of management in a cast versus elasticated support bandage. *Injury* 2005; 36:832-835.
28. Greene WB. Essentials of Musculoskeletal Care. 2nd ed. Rosemont, Ill.: American Academy of Orthopaedic Surgeons; 2001.p.453-455.
29. Canale S T, Beaty J H editors. Campbell's Operative Orthopaedics, 11th ed. Philadelphia, Pa.: Mosby; 2003 p.4270-4274.
30. Alepuz ES, Carsi VV, Alcántara P. Fractures of the central metatarsals. *Foot Ankle Int* 1996; 17:200.
31. Baumfeld D, Macedo BD, Nery C, Esper L E, Filho MAB. Antegrade Percutaneous Treatment of Lesser Metatarsal Fractures: Technical Description And Clinical Results. *Revista Brasileira de Ortopedia*. 2012;47(6):760-764. doi:10.1016/S2255-4971(15)30035-5.