

CASE REPORT

Intra-Abdominal Gossypiboma: An Unusual Cause of Intestinal Obstruction

Chimezie I
MADUBOGWU

Department of Surgery
Chukwuemeka Odumegwu
Ojukwu University
Awka Campus, Anambra State
South-East, NIGERIA

Phone: +234 803 400 5584
Email: chymezo@yahoo.com

Received: May 21st, 2018
Accepted: July 3rd, 2018

DISCLOSURE
No conflict of interest

ABSTRACT

Background: Retained foreign object (RFO) of which gossypiboma is one of them have been identified as a rare cause of intestinal obstruction but the incidence is rising with increasing number of surgeries. Gossypiboma is a general term used for surgical materials made of cotton which may vary from a small piece of gauze to a large abdominal mop or towel. Gossypiboma is an uncommon surgical embarrassment which is associated with increased morbidity and mortality as well as litigation against the Surgeon or hospital. This study presents two concurrent cases of intestinal obstruction secondary to gossypiboma presenting in our centre within a space of a week from surgeries done in 2 different private hospitals several years ago. A high index of suspicion is needed to make the diagnosis and all efforts should be geared towards its prevention.

Keywords: Retained foreign body, Morbidity, Litigation, Acute abdomen, Gauzeoma

INTRODUCTION

Intestinal obstruction is the impedance of cephalo-caudal movement of gastro-intestinal contents. It has a wide range of causes and may occur as post-operative complication following a laparotomy. Retained foreign object (RFO) of which gossypiboma is one of them has been identified as a rare cause of intestinal obstruction, though the incidence is rising with increasing number of surgeries being done.^{1,2,3,4,5,6,7,8} Retained foreign objects could vary from cotton surgical materials to plastic and metallic surgical instruments or other materials.⁴ Gossypiboma is a general term used for surgical materials made of cotton which may vary from a small piece of

gauze to a large abdominal mop or towel. Some authors have used other terms to describe RFO of cotton origin like: textiloma, gauzeoma, muslinoma, cottonoid and cottonballoma.^{9,10,11,12}

Gossypiboma has been reported in surgeries involving several parts of the body but is most common following intra-abdominal surgeries.^{10,12,13,14,15,16,17} Gossypiboma is a very devastating but preventable post-operative complication that can lead to increased morbidity and mortality on the part of the patients as well as litigation, loss of self confidence and reputation on the part of the surgeon.^{1,12} The actual incidence of

gossypiboma is unknown due to under reporting because of associated medico-legal implications and prolonged latency which may last several years.^{1,5,13,18,19,20}

Intra-abdominal gossypiboma could present in a number of ways depending on its location and the type of body reaction induced. It could be: asymptomatic or delayed presentation for several years; aseptic fibrotic reaction leading to formation of an abdominal mass which may lead to later complications; exudative reaction with abscess formation, intra-luminal migration, intestinal obstruction or fistula formation.^{3,5,6, 21,22,23,24,25}

The aim of this study is to report two concurrent cases of intestinal obstruction secondary to gossypiboma presenting in our centre within a space of a week from surgeries done in 2 different private hospitals several years ago. It is also to highlight gossypiboma as a possible aetiology in any post laparotomy intestinal obstruction.

CASE REPORTS

Case 1

A 36 year old single lady presented to our centre with an on and off history of abdominal pains of a year duration. Pain was colicky and transiently relieved by some oral analgesics and antibiotics. The current episode started a week ago, more severe with associated abdominal distension, vomiting and constipation. She gave a history of hysterectomy done at a private hospital 2 years prior to presentation.

On admission, patient was acutely ill-looking, in painful distress, pale, anicteric and dehydrated. Pulse rate of 140 beats/min and blood pressure of 120/80mmHg were recorded. Abdomen was distended with generalized tenderness. There was a mid-line sub-umbilical incision scar and bowel sound was hypoactive. Abdominal ultrasound showed dilated and aperistaltic loops of small bowel floating on large pool of intra-abdominal and pelvic fluid. A preoperative diagnosis of strangulated intestinal

obstruction secondary to post-operative adhesions was made. She was counseled and worked up for laparotomy. Intra-operative findings were: intra-abdominal and pelvic abscesses mixed with faeces, adherent loops of ileum forming a huge mass and multiple perforations on the part of the bowel forming the mass with proximal bowel distension.

Resection of the mid ileum bearing the mass was done with end to end ilio-ileal anastomosis. Warm saline lavage of the abdomen was done. Opening of the resected mass showed a large piece of surgical mop/towel completely surrounded by bowel loops and partly intra-luminal (see Figure 1). She had a turbulent post-operative recovery as she developed intra-abdominal abscess for which a second laparotomy was done. She subsequently recovered and was discharged home sifter 38days on admission. A litigation threat was sent to the doctor that performed the initial hysterectomy by the patient's attorney, but the matter was eventually settled out of court.

Case 2

A 34 year old married woman presented at our facility with 6 year history of left lower abdominal mass and pains. The pain was worse after feeding, colicky and relieved by some unknown drugs. There was associated anorexia, weight loss, abdominal fullness and occasional constipation but no fever or vomiting. Above symptoms were noticed after a caesarean section was done 6 years ago at a private hospital. She is not a known hypertensive or diabetic. On examination, she was chronically ill-looking, afebrile, pale, anicteric, not dehydrated and with a pulse rate of 110 beats/sec. Abdominal examination revealed a Pfannenstiel incision scar with hard intra-abdominal mass located on the left iliac fossa, mildly tender and measures 10x12cm. Abdominal ultrasound showed a mass on left lower abdomen sitting close to the fundus of the uterus with acoustic shadow. There were lots of gases and fluid dilatation of the bowel.

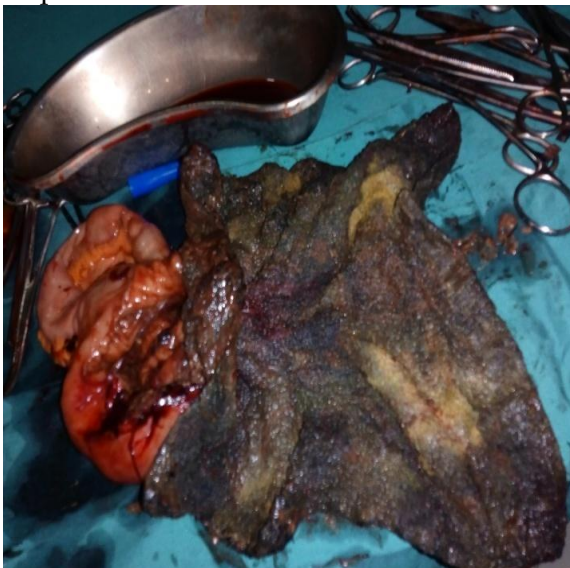
An initial diagnosis of partial intestinal obstruction secondary to intra-abdominal

retained foreign body with a differential of left colonic tumour was made. She was counseled for surgery. Intra-operative findings were: intra-abdominal mass inside a loop of ileum with associated loops of adherent small bowel to the anterior abdominal wall over the previous scar. Adhesiolysis, resection of bowel mass with ileo-ileal anastomosis were done. Opening of the bowel mass showed a surgical towel completely intra-luminal (Figure 2). Post-operative recovery was uneventful and she was discharged on the eight post-operative day.

Figure 1. Surgical mop partly intra-luminal with multiple perforation and walled off by loop of ileum.

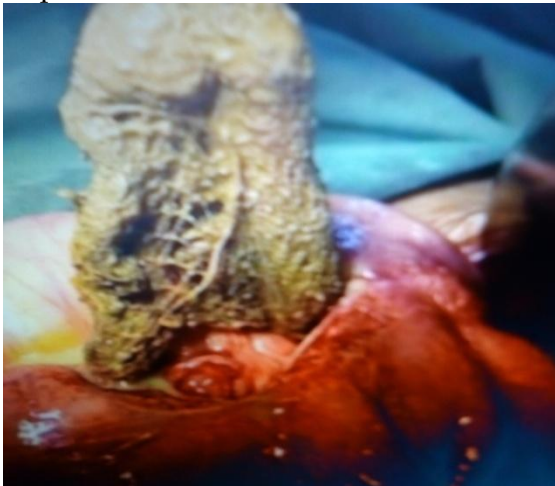

Figure 2. Post-operative picture of a surgical mop/towel completely intra-luminal in a loop of ileum.



DISCUSSION

Gossypiboma is a term used to describe a retained foreign object inadvertently left in the body following a surgical procedure.^{6,7,12,16,19,23,25} Gossypiboma is an uncommon surgical embarrassment which is associated with increased morbidity and mortality. The actual data concerning gossypiboma is unknown because it is highly under reported because of the high risk of litigation associated with it and because some can remain asymptomatic for a very long time.^{1,5,13,18-20} However, its incidence has been reported to be as high as 1 in 100-5000 for all surgical procedures and 1 in 1000-1500 for intra-abdominal surgeries.^{16,17,25}

Gossypiboma is an important cause of intestinal obstruction as shown in our 2 index cases. The clinical presentation of intra-abdominal gossypiboma could vary widely from being asymptomatic to presentations with symptoms and signs of intestinal obstruction.^{7,16,23,25} Some of the more common presentations as noted by Wan *et al.* are: Pain/irritation (42%), palpable mass (27%), and fever (12%).¹⁵ It could also be complicated by: adhesion (31%), abscess (24%), and fistula (20%).^{13,15}

Adhesions as seen in our second case usually result from a prolonged phase of aseptic fibrosis, encapsulation and formation of an intra-abdominal mass. On the other hand, abscess formation as seen in our first case could result from initial exudation and then secondary bacterial infection. These 2 typical scenarios could manifest with: abdominal pain, abdominal mass, intestinal obstruction, gastrointestinal hemorrhage, intra-abdominal sepsis, granulomatous peritonitis and fistula formation in the nearby structures.³

Fistulae involving various structures following intra-abdominal gossypiboma have been reported.^{3,5,6,17,25} Transmural migration of gossypiboma is usually a prelude to bowel or visceral perforation, obstruction or fistula formation.²⁰ The site of the fistula depends on the primary surgery and the location of the foreign object which migrates into the surrounding structures. Transmural

migration of an intra-abdominal gossypiboma has been reported to occur in stomach, ileum, colon, bladder, vagina and diaphragm.^{3,5,6,17,20,25}

Gossypiboma in general occur more following gynecological and upper abdominal emergency surgeries but it can also be seen after thoracic, orthopedic, urological, and neurosurgical operations.^{13,18} For intra-abdominal gossypiboma, the commonest initial surgical procedure according to Lv *et al.* are: cholecystectomy (32.6%); caesarean section (19.6%) and hysterectomy (15.2%).¹⁹

Some of the noted causes of gossypiboma are: unexpected change in the surgical procedure, emergency surgeries, obesity, difficult surgeries, inexperienced staff, hurried/inadequate counting of surgical materials, fatigued surgical team, involvement of more than one surgical team and change of nursing staff during the surgical procedure among others.^{6,13}

Detection of gossypiboma is made difficult due to its rarity, prolonged latency in some cases and because it could be asymptomatic.^{1,3,5,13} Some imaging technique can be of help in detection of gossypiboma, they include: plain x-ray; ultrasonography, CT-Scan and MRI.^{12,14,19} According to Wan *et al.*, the most common detection methods were computed tomography (61%), radiography (35%) and ultrasound (34%).¹⁵ Detection by radiological screening is very difficult particularly if the sponge does not have radio-opaque marker on it.¹⁸

Ultrasound may show a cystic or a solid mass. The cystic lesion may present with a wavy echogenic structure while the solid type may appear as a complex mass with hyper and hypo-echoic regions.¹⁴ The retained material may also show an acoustic shadowing due to calcification as seen in our second index case. CT-Scan may show a low-density, heterogeneous mass with a thick peripheral rim due to calcification.¹⁴ The presence of mottled, bubbly gas shadows with

spongiform pattern will suggest the diagnosis.^{12,14}

Gossypiboma whenever discovered or diagnosed should be removed. The mode of retrieval or removal of a gossypiboma could vary widely from non-surgical endoscopic retrieval to laparoscopic or open surgical removal with possible resection and anastomosis as seen in the index cases. The chosen mode of removal will depend on the location of the gossypiboma, the clinical presentation and the available technological knowhow and facility.^{12,19,20}

There have been documentations on spontaneous passage of an intra-luminal gossypiboma through the anus during defaecation.^{12,19,25} Some cases of endoscopic retrieval of intra-luminal gossypiboma through a gastro-duodenoscope have been achieved successfully but should only be attempted if there is no associated active gastro-intestinal bleeding, intestinal obstruction, or free perforation.¹⁹

Open surgical operation for removal of gossypiboma could also vary from percutaneously making an incision directly over the palpable mass or through a formal laparotomy as in the index cases. Making a direct incision over the palpable mass could simplify a formal laparotomy and reduce the extensive dissections that may be involved in a formal laparotomy.¹² A formal laparotomy may be very imperative in cases with associated intestinal obstruction, bowel perforation or fistula formation.^{12,19}

Gossypibomas are better prevented because of their devastating effects to the patient, the surgeon and the hospital involved. A number of steps are involved in the prevention of gossypiboma and they include: counting the surgical materials and instruments before and after the surgery by the scrub nurse; re-counting whenever there is change in the operative staff; exploration of the entire abdomen by the surgeon at the end of the surgery for confirmation after correct counting; use of only sponges or towels with radio-opaque marker; avoiding the use of

small pieces of gauze inside the abdomen; radiographic imaging with a high resolution X-ray in high risk cases before closure and adopting an effective hospital protocol which must be adhered to during surgeries.^{6,12}

There are however some newer technologies used in some centres to reduce human errors in counting. They include: the use of radiofrequency device; barcode sponge system; utilization of a tag made of a

specialized magnetic metal, which emits when demagnetizes, a radio wave that can be detected by a hand held detector.^{12,25,26}

CONCLUSION

Gossypiboma is a rare but emerging cause of intestinal obstruction. A high index of suspicion is needed to make the diagnosis and all efforts should be geared towards prevention.

REFERENCES

1. Silva SM, Sousa JB Gossypiboma after abdominal surgery is a challenging clinical problem and a serious medico legal issue. *Arq Bras Cir Dig* 2013; 26(2):140-143.
2. Patil KK, Patil SK, Gorad KP, Panchal AH, Arora SS, Gautam RP. Intraluminal migration of surgical sponge: gossypiboma. *Saudi J Gastroenterol* 2010; 16:221-222.
3. Kato T, Yamaguchi K, Kinoshita K, Sasaki K, Kagaya H, Meguro T, Morita *et al.* Intestinal Obstruction due to Complete Transmural Migration of a Retained Surgical Sponge into the Intestine. *Case Rep Gastroenterol* 2012; 6(3):754-759.
4. Khan HS, Malik AA, Ali S, Naeem A. Gossypiboma as cause of intestinal obstruction. *J Coll Physicians Surg Pak* 2014; 24(Suppl 3):S188-89.
5. Margonis E, Vasdeki D, Diamantis A, Koukoulis G, Christodoulidis G, Tepetes K. Intestinal obstruction and ileocolic fistula due to intraluminal migration of a gossypiboma. *Case Rep Surg* 2016; 2016:3258782.
6. Faghani M, Fazel AR and Roshandel G. Small Bowel Obstruction and Enterocolic Fistula from a Gossypiboma after Caesarean Section. *West Indian Med J* 2014; 63(5): 539-540.
7. Khan YA, Asif M, and Al-Fadhli W. Intraluminal Gossypiboma. *APSP J Case Rep* 2014; 5(2): 17.
8. Ogundiran T, Ayandipo O, Adeniji-Sofoluwe A, Ogun G, Oyewole O, Ademola A. Gossypiboma: complete transmural migration of retained surgical sponge causing small bowel obstruction. *BMJ Case Rep* 2011; 2011:4073.
9. Soares FV, Vicentini L, Dell'Aringa AR, e Silva LC Textiloma in abdominal cavity: 35 years later. *Arq Bras Cir Dig* 2013; 26(1):74-75.
10. Yoon MA, Kim E, Kwon BJ, Kim JE, Kang HS, Park JH, *et al.* Muslinoma and muslin-induced foreign body inflammatory reactions after surgical clipping and wrapping for intracranial aneurysms: imaging findings and clinical features. *J Neurosurg* 2010;112(3):640-647.
11. Kawahara S, Honda M, Kosuda S, Tamura K, Miwa K, Hashimoto T, *et al.* CT and US findings of gauzeoma. *Nihon Igaku Hoshasen Gakkai Zasshi* 1990;50(4):375-381.
12. Rabie ME, Hosni MH, Al Safty A, Al Jarallah M and Ghaleb FH. Gossypiboma revisited: A never ending issue. *Int J Surg Case Rep* 2016;19:87-91.
13. Lata I, Kapoor D, Sahu S. Gossypiboma, a rare cause of acute abdomen: a case report and review of literature. *Int J Crit Illn Inj Sci* 2011;1:157-160.
14. Pole G and Thomas B. A Pictorial Review of the Many Faces of Gossypiboma - Observations in 6 Cases. *Pol J Radiol* 2017; 82: 418-421.
15. Wan W, Le T, Riskin L, Macario A. Improving safety in the operating room: a systematic literature review of retained surgical sponges. *Curr Opin Anaesthesiol* 2009;22 (2):207-214.
16. Yagmur Y, Akbulut S and Gumus S. Post Cholecystectomy Gossypiboma Mimicking a Liver Hydatid Cyst: Comprehensive Literature Review. *Iran Red Crescent Med J* 2015 Apr; 17(4): e22001.
17. Chopra S, Suri V, Sikka P, Aggarwal N. A case series on gossypiboma - varied clinical presentations and their management. *J Clin Diagn Res* 2015;9(12):QR01-03.
18. Moslemi MK, Abedinzadeh M. Retained Intra abdominal Gossypiboma, five years after

- bilateral orchiopexy. *Case Report Med* 2010;2010:420357.
19. Lv YX, Yu CC, Tung CF, Wu CC. Intractable duodenal ulcer caused by transmural migration of gossypiboma into the duodenum—a case report and literature review. *BMC Surgery*. 2014;14, article 36 doi: 10.1186/1471-2482-14-36.
 20. Sozutek A, Yormaz S, Kupeli H, Saban B. Transgastric migration of gossypiboma remedied with endoscopic removal: a case report. *BMC Res. Notes* 2013;6 (1):413.
 21. Susmallian S, Raskin B, and Barnea R. Surgical sponge forgotten for nine years in the abdomen: A case report. *Int J Surg Case Rep* 2016; 28: 296–299.
 22. Kansakar R, Thapa P, Adhikari S. Intraluminal migration of gossypiboma without intestinal obstruction for fourteen years. *JNMA J Nepal Med Assoc* 2008;47(171):136–138.
 23. Zhang H, Jiang Y, Wang Q, and Liu J. Lower abdominal gossypiboma mimics ovarian teratoma: a case report and review of the literature. *World J Surg Oncol* 2017; 15: 6.
 24. Akbulut S, Arikanoğlu Z, Yagmur Y, Basbug M. Gossypibomas mimicking a splenic hydatid cyst and ileal tumor : a case report and literature review. *J Gastrointest Surg* 2011 Nov;15(11):2101-2107.
 25. Sistla SC, Ramesh A, Karthikeyan VS, Ram D, Ali SM, Subramaniam RV S. Gossypiboma presenting as coloduodenal fistula—report of a rare case with review of literature. *International Surgery*. 2014;99(2):126–131.
 26. Steelman VM, Alasagheirin MH. Assessment of radiofrequency device sensitivity for the detection of retained surgical sponges in patients with morbid obesity. *Arch Surg* 2012;147 (10):955–960.
 27. Greenberg CC, Diaz-Flores R, Lipsitz SR, Regenbogen SE, Mulholland L, Mearn F, et al. Bar-coding surgical sponges to improve safety: a randomized controlled trial. *Ann Surg* 2008;247(4):612–616.