

## ORIGINAL ARTICLE

## Penile Fractures in North Central Region of Nigeria

Edwin I OGWUCHE<sup>1,2</sup>  
Victor E ONOWA<sup>2</sup>  
Idorenyin C AKPAYAK<sup>3</sup>

<sup>1</sup>Department of Surgery  
Benue State University  
Teaching Hospital  
Makurdi, Benue State  
NIGERIA

<sup>2</sup>Department of Surgery  
Federal Medical Centre  
Makurdi, Benue State  
NIGERIA

<sup>3</sup> Department of Surgery  
Jos University Teaching  
Hospital Jos, Plateau State  
NIGERIA

**Author for Correspondence**

Edwin Iduh OGWUCHE  
Department of Surgery  
Benue State University  
Teaching Hospital Makurdi,  
Benue State. NIGERIA

Phone: +234 805 775 2066

Email:

iduhogwuiche@gmail.com

Received: 10<sup>th</sup> December, 2018

Accepted: 20<sup>th</sup> July, 2018

**DISCLOSURE**

The authors declare no source of funding or conflicting interests

**ABSTRACT**

**Background:** Penile fracture is defined as a rupture of the tunica albuginea of the corpus cavernosum as a result of blunt trauma to an erect penis.

**Objectives:** To study the aetiological factors, presentation, site of injury, treatment, as well as the treatment outcome of all patients that presented to us with penile fracture .

**Methodology:** Data were obtained retrospectively from the patients' clinical records from three centres: Benue State University Teaching Hospital, Urodiagnostic Specialist Centre and Federal Medical Centre, all in Makurdi, North Central Nigeria over a five year period (January 2012 to December, 2016). The bio-data, aetiological factors, time of presentation, site of injury, treatment given and outcome of treatment were analysed.

**Results:** Six patients with median age of 39yrs were seen within the study period. Coitus with the woman on top was the precipitating factor in four patients.

The time interval from injury to presentation ranged from 12 - 72hours. The classical presentation was noted in all patients. Five patients had surgical exploration. All injuries were in the mid shaft of the corpora cavernosa with the right side affected in three patients. Average hospital stay was 4 days. All patients had full erection at three months post exploration, however one patient reported penile deviation.

**Conclusion:** The outcome of penile fracture following surgical repair was good.

**Keywords:** Penis, Penile rupture, Trauma, Coitus, Penile reconstruction, Phallic injuries,

## INTRODUCTION

Penile fracture is defined as a rupture of the tunica albuginea of corpus cavernosum as a result of blunt trauma to an erect penis.<sup>1,2,3</sup> Penile fracture which was said to be a rare urological emergency is now increasingly reported worldwide.<sup>4,5,6,7</sup> Injuries involving the flaccid penis are not included in this definition. It is diagnosed clinically when a history of blunt trauma to the erect penis occurs with a resultant cracking or popping sound, pain, immediate detumescence and swelling of the penis. The association of blood at the external meatus or gross urethrorrhagia suggests urethral injury.

Even though penile fracture is a rare entity, the typical clinical presentation is usually diagnostic, hence surgical exploration can be undertaken without delay even if diagnostic procedures such as caverno-sonography and magnetic resonance imaging (MRI) have not been done.<sup>8,9</sup> Urethrogram is recommended if an associated urethral injury is suspected.

It is believed that it is difficult to establish the true incidence of penile fracture as many patients may not seek medical care as it is considered embarrassing.<sup>5,10</sup>

Studies on this rare urological entity have been limited to case reports and case series.

One of the largest series of 172 cases was reported by Zargooshi T from the Republic of Iran where the practice of "taghaandan" (to click or snap when forcibly pushing the erect penis down to achieve detumescence) was identified as the commonest aetiological agent.<sup>6</sup>

We report six patients with penile fractures seen over a five year period at three centres in Makurdi, Benue State, North Central Nigeria.

## METHODOLOGY

The data for this study was collected retrospectively from the patients' clinical records at the Urology unit of Benue State University Teaching Hospital, Federal Medical Centre and Urodiagnostic Centre all in Makurdi, Benue state, North Central Nigeria between January 2012 and December 2016.

All patients with a clinical diagnosis of penile fracture in the institutions were included in the study. Information on the patients' age, marital status, precipitating event, time of presentation, mode of presentation, site of the injury treatment given and complications were obtained using a proforma. Data were analysed using the SPSS for Windows, Version 16.0. Chicago, SPSS Inc.

## RESULTS

Six patients were seen within the study period. The age range was 28-60years with a median age of 39yrs. Three patients were married while the remaining three were single.

Coitus with woman sitting on top was the precipitating factor in 4 patients (Table 1).

One patient had fracture from forcefully bending the penis after he was denied sex by his partner, while another patient fractured from masturbation.

Time interval from injury to presentation ranged from 12 - 72hours with an average of 36hours. All the patients complained of hearing a cracking sound accompanied by severe pain, immediate detumescence and penile swelling. None of the patients had bleeding per urethram.

All the patients were evaluated and counselled as to the nature of the injury and the need for immediate surgical exploration.

Five patients consented to surgical exploration while one declined because he felt surgery will affect his fertility, left hospital against medical advice and was lost to follow up. Surgical exploration was done under general anaesthesia.

The Laubschers subcoronal sleeve approach was used in all cases to deglove the penis and expose the fracture sites. However 2 patients who presented at about 72hours post injury required additional transverse incisions over the fracture site for adequate access due to oedema and haematoma preventing adequate exposure of the fracture site for repair.

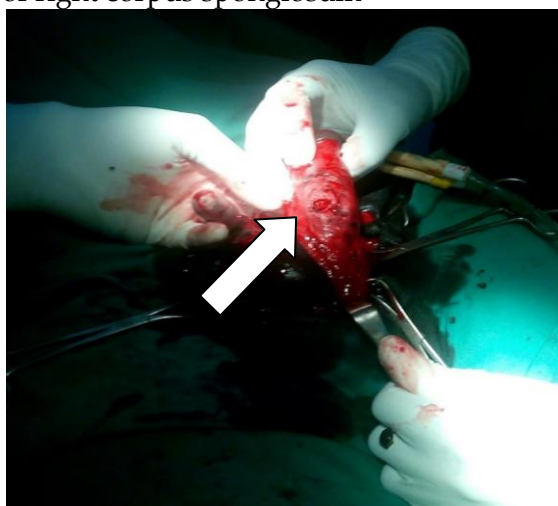
All five patients had a single corporal injury with transverse tear on the tunica albuginea measuring 2-3cm long on the corpus

cavernosum. All injuries were on the mid shaft (Figure 1). The right corpus carvenosum was involved in 3 cases while 2 injuries were on the left side (Table 1). Repair was done using Vicryl® 2/0 suture after evacuation of the haematoma and debriding the wound. They all had perioperative antibiotics and non-steroidal anti - inflammatory drugs. Post-operative recovery was uneventful with an average hospital stay of 4days.

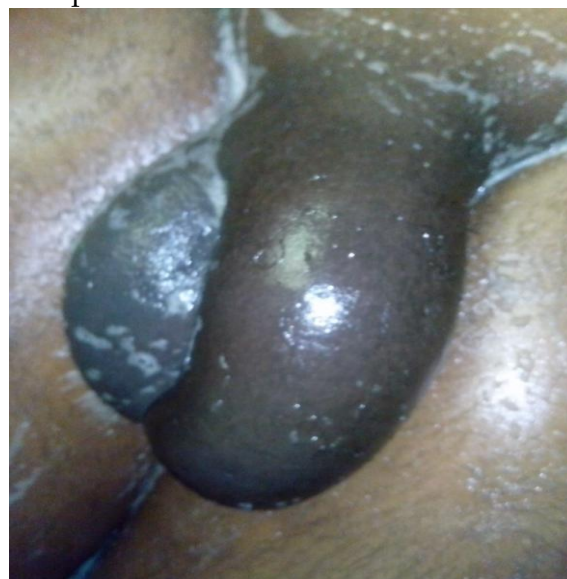Only one patient maintained follow up visits for six months while the other 4 were lost to follow up after 3months duration.

A patient had penile curvature on erection. All patients reported full erections at 3 months of follow up.

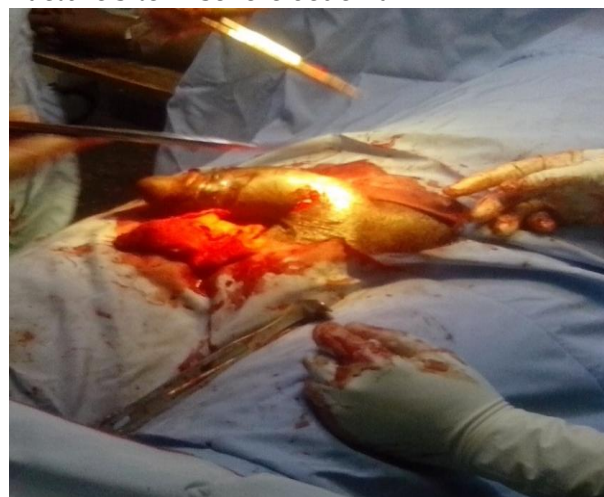**Figure1.** Fracture site on mid shaft of right corpus spongiosum



**Figure2.** Penile oedema extending to the mons pubis



**Figure3.** Additional incision over the fracture site in severe oedema



**Table 1.** Summary of patients’ information

S/ No	Age(yrs)	Marital status	Time of presentation (Hrs)	Aetiological factor	Coital position	Site of fracture
1	60	M	12	Coitus	Woman on top	Left midshaft
2	28	S	72	Coitus	Woman on top	Right midshaft
3	33	S	24	Coitus	Woman on top	Refused surgery
4	51	M	72	Coitus	Woman on top	Right midshaft
5	38	S	24	Masturbation	NA	Left midshaft
6	40	M	40	Forceful detumescence	NA	Right midshaft

M = Married    S = Single    NA = Not applicable

**DISCUSSION**

The rising incidence of penile fractures have been reported worldwide.<sup>4,5,6,7</sup>

Diagnosis is usually clinical because of the stereotypical presentation.<sup>11</sup> All patients in this study reported hearing a cracking sound followed by immediate pain, detumescence

and swelling. This is the typical presentation in previous studies by several authors<sup>1,2,3,4,5,6,7</sup> None of the patients in these series needed additional radiological diagnostic aid in view of the classical presentation. More so, none had blood at the urethral meatus that would have suggested urethral rupture necessitating a urethrogram.

Vigorous Sexual intercourse with the woman sitting on top of the man was the aetiological factor in four (4) of our patients. This is comparable to reports by Nicoliasen *et al.* from the United States of America, while in Iran only 8% were related to sexual intercourse with self-manipulation being responsible for a majority of cases as reported by Zargooshi T in a series of 172 patients.<sup>6,12</sup> Masturbation and rolling over in bed are the most common causes in Japan with only 19% resulting from coitus.<sup>13</sup>

The median age at presentation in this study was 39years as opposed to the 32.3yrs in the series by Bali *et al.*, while the mean age in studies by Ekeke *et al.* in the Niger Delta region of Nigeria was 32.28years.<sup>2,14</sup> Reported mean age from South-West Nigeria is 26.4years according to Tijani *et al.*<sup>2,7</sup>

All patients in this series presented within 72hours of the injury. Longer periods of 5 and 6 months have been reported by Tijani *et al.*<sup>7</sup>

Immediate surgical exploration has been shown to have a better outcome than conservative management hence this approach was adopted for the management of the 5 patients who consented.<sup>15,16,17</sup>

Many approaches to the fracture site have been described but the Laubscher's subcoronal sleeve approach is the most popular<sup>1,5,10</sup>. This was used in the 5 patients that were explored. However a disadvantage of this procedure which was encountered in 2 patients is inadequate exposure of the fracture site as a result of oedema and haematoma extending to the mons pubis (Figure 2). This necessitated additional

transverse skin incisions over the fracture site for ease of repair (Figure 3). The severe oedema and haematoma was noted in the 2 patients who presented at 72hours post injury.

Three fractures in this cohort of patients occurred in the mid shaft of the right corpora cavernosa while 2 occurred in the mid shaft of the left. The right corpora cavernosa has been reported as the commonest site in previous studies from Nigeria.<sup>18,19</sup>

Several complications including wound infection, abscess formation, penile deviation and erectile dysfunction have been reported.<sup>2,20,21,22</sup> However only one patient had penile deviation in this study though long term follow up is necessary to fully assess late complications. The patient who declined surgical exploration was lost to follow up hence the long term outcome cannot be ascertained.

## CONCLUSION

Vigorous sexual intercourse is the commonest aetiological factor for penile fracture in this study. The immediate outcome of penile fracture following exploration in this study is good but long term follow up studies as well as larger number of cases are needed for a comprehensive conclusion.

## REFERENCES

1. Mazaris EM, Livadas K, Chalikopoulos D, Bisas A, Deliveliotis A, Skolarikos A. Penile fractures: immediate surgical approach with a midline ventral incision. *BJU Int* 2009; 104:520-523.
2. Bali RS, Arsha A, Mushtaque M, Nabi S, Bhat RA. Penile fracture: experience from a third world country. *Adv Urol* 2013; 2013:708362.
3. Jallu A, Wani NA, Rashid PA. Fracture of the penis. *J Urol* 1980; 123:285-286.
4. Malis J. Zur K. Der Fractura penis. *Arch Klin Chir* 1924; 129:651.
5. Eke N. Fracture of the penis. *Br J Surg* 2002; 89:555-565.
6. Zargooshi J. Penile fracture in Kermanshah, Iran: report of 172 cases. *J Urol* 2000; 164:364-366.



7. Tijani KH, Ogo CN, Ojewola RW, Akanmu NO. Increase in fracture of the penis in south-west Nigeria. *Arab J Urol* 2012; 10(4):440-444.
8. Ozen HA, Erkan I, Alkibay T, Kendi S, Remzi D. Fracture of the penis and long-term results of surgical treatment *BJU Int* 1986;58(5):551-552.
9. Fedel M, Venz S, Andreessen R, Sudhoff F, Loening SA, "The value of magnetic resonance imaging in the diagnosis of suspected penile fracture with atypical clinical findings," *J Urol* 1996;155:1924-1927.
10. Ugwu BT, Yiltok SJ, Uba AF, Abdulmajid UF. Fracture of the penis-a rare injury on the Jos Plateau, Nigeria. *Cent Afr J Med* 1998; 44:107-109.
11. Ghanem AN. Re: penile fractures in Kermanshah. *Br J Urol* 2002; 89:890.
12. Nicoliasen GS, Melamud A, McAninch JW. Rupture of the corpus cavernosum: surgical management *J Urol* 1983; 130:917-919.
13. Ishikawa T, Fujisawa M, Tamada H, Shimatani N. Fracture of the penis: nine cases with evaluation of reported cases in Japan. *Int J Urol* 2003; 10:257-260.
14. Ekeke ON, Eke N Fracture of the penis in the Niger delta region of Nigeria. *J West Afr Coll Surg* 2014 Jul-Sep; 4 (3):1-19.
15. Muentener M, Suter S, Hauri D, Sulser T. Long-term experience with surgical and conservative treatment of penile fracture. *J Urol* 2004; 172:576-579.
16. Gamal WM, Osman MM, Hammedy A, Aldahshoury ZM, Hussein MM, Saleem M. Penile fracture: long-term results of surgical and conservative management. *J Trauma* 2011; 71:492-493.
17. El Atat R, Sfaxi M, Benslama MR, Amine D, Ayed M, Mouelli SB, *et al.* Fracture of the penis: management and long-term results of surgical treatment. Experience in 300 cases. *J Trauma* 2008; 64:121-125.
18. Mbonu OO, Aghaji AE. 'Fracture' of the penis in Enugu, Nigeria. *J R Coll Surg Edinb.* 1992; 37:309-310
19. Omisano OA, Bioku MJ, Ikuerowo SO, Sule GA, Esho JO. A prospective analysis of the presentation and management of penile fracture at the Lagos State University Teaching Hospital (LASUTH), Ikeja, Lagos, Nigeria. *Afr J Urol* 2015; 21: 52-56.
20. Jack GS, Garraway I, Reznichuk R, Rajfer J. Current treatment options for penile fractures. *Rev Urol* 2004; 6: 114-120.
21. Ateyah A, Mostafa T, Nasser TA, Shaer O, Hadi AA, Al-Gabbar MA. Penile fracture: surgical repair and late effects on erectile function. *J Sex Med* 2008; 5:1496-502.
22. El-Assmy A, El-Tholoth HS, Mohsen T, Ibrahim el HI. Long-term outcome of surgical treatment of penile rupture. *J Sex Med* 2010; 7:3784-3788.