

## ORIGINAL ARTICLE

## Computed Tomography Evaluation of Petrous Bone Fractures

Uzoamaka R

**EBUBEDIKE<sup>1</sup>**Eric Okechukwu **UMEH<sup>1</sup>**

Evaristus A

**AFIADIGWE<sup>2</sup>**<sup>1</sup>Department of Radiology<sup>2</sup>Department of SurgeryNnamdi Azikiwe University  
Teaching Hospital Nnewi  
NIGERIA**Author for Correspondence**Eric Okechukwu **UMEH**

Radiology Department

Nnamdi Azikiwe University  
Teaching Hospital PMB 5025  
Nnewi, NIGERIA

Phone: +234 813 089 9639

Email: erada1996@yahoo.co.uk

Received: November 11<sup>th</sup>, 2016Accepted: January 12<sup>th</sup>, 2017**DISCLOSURES:**

The authors declare neither financial support, sponsorship nor conflict of interest.

**ABSTRACT**

**Background:** Petrous bone trauma is the sequel of blunt head injury and can have life threatening complications resulting in immediate mortality. Early detection and good knowledge of the Computed Tomography (CT) findings ensure prompt treatment of both fractures and complications.

**Objective:** To document the frequency and prevalent most type of petrous bone fracture, co-existing intracranial haemorrhage and other skull fractures as well as establish association between them.

**Methodology:** Forty-six CT images of patients aged  $\geq 1$  year were investigated for petrous fractures and complications in two South-East hospitals, Nnamdi Azikiwe University Teaching Hospital (NAUTH) Nnewi, Anambra State and Iyenu Mission Hospital Ogidi, Anambra State, were enrolled into the study. Statistical analysis of data was done using SPSS software version 17.0 for windows.

**Results:** The study population had a mean age of 30.4 years  $\pm 17.4$  with an age range of 1.4 to 80 years. Subjects aged 21–30 years were of the highest frequency. The most common petrous fracture is longitudinal (58.7%), while the least was mixed petrous fracture (6.5%). Amongst other skull fractures, the most common was parietal fracture while the most common intracranial haemorrhage was intracerebral. An association was found only between the mixed type and intracerebral haemorrhage, *p*-value 0.042. There was no association between petrous fractures and other skull fractures.

**Conclusion:** The most common petrous bone fracture was the longitudinal type with intracerebral haemorrhage and parietal bone fractures being the most prevalent complications. An association is established only between the mixed petrous fracture and intracerebral haemorrhage.

**Keywords:** Complications, Intracranial haemorrhage, Longitudinal fractures

**INTRODUCTION**

Temporal bone fractures are gradually being classified into petrous and non-petrous types.<sup>1,2</sup> Petrous fracture is defined as a fracture extending to the petrous apex or otic capsule or both.<sup>1,2</sup> Petrous fractures are subdivided into longitudinal, transverse and oblique (mixed) types following the

orientation of the fracture line to the longitudinal axis of the petrous pyramid.<sup>3</sup> This traditional classification has been used in this study because it gives clinicians a conceptual idea of the fracture pattern.

A longitudinal fracture occurs along the longitudinal axis of the petrous pyramid,

which extends parallel to the external and internal auditory canals towards the petrous apex.<sup>4</sup> Parietal bones are commonly involved.<sup>5,6</sup> Transverse fracture is perpendicular to the petrous bone longitudinal axis, crosses the temporal bone from a posterior to an anterior direction with occipital bone, frontal bone and craniocervical junction commonly involved, while oblique (mixed) fracture has transverse and longitudinal elements.<sup>3,7</sup> Anatomically, the petrous part of temporal bone is located deep in the skull base and is considered as one of the toughest bones in the body.

Petrous bone trauma as is the case in other temporal bone fractures is the sequelae of blunt head injury.<sup>8</sup> Damage to the temporal bone typically requires application of great force and may cause fracture, haemorrhage or disruption of the middle or inner ear structures. Also, intracranial injuries such as extra-axial haemorrhage, shear (or diffuse axonal) injury and brain contusion are common.<sup>8</sup> In a study by Olabinri *et al.* in South-West Nigeria, petrous temporal bone fractures were found to be the most common basal fracture, the longitudinal type being predominant.<sup>9</sup> Amin *et al.*, reported petromastoid fractures as the common in head injury patients and 67% of the petrous fractures were of the longitudinal type.<sup>10</sup>

Petrous bone fracture is known to be associated with facial nerve injury, cerebrospinal fluid leak, meningitis, hearing loss and vestibular dysfunction.<sup>11,12,13,14</sup> However, none of the complications is more life-threatening than the intracranial bleeding that can cause immediate mortality.<sup>14</sup>

Many imaging modalities available for the evaluation of the temporal bone include plain radiography, angiography, air and non-ionic contrast cisternography, computed tomography (CT) and magnetic resonance imaging (MRI). The latter two modalities, CT and MRI, are currently the most widely used and have largely replaced the other modalities.<sup>15,16</sup> The CT excels in the evaluation of bone and air-space anatomy and disorders,

and it offers high contrast images with spatial resolution. Thus, detailed scans of petrous fractures and their complications could be demonstrated, readily.

In this study, the pattern of petrous bone fractures, co-existing intracranial haemorrhage and other skull fractures were investigated. This would benefit the clinicians particularly the otorhinolaryngologists who are often involved with the management of this type of fractures.

#### METHODOLOGY

This was a 2-year prospective study of patients aged 1-80years conducted from January 2013 to December 2015. The source population was from patients with head injury who presented to the accident and emergency units of two health institutions; Nnamdi Azikiwe University Teaching Hospital (NAUTH), Nnewi and Iyien Mission Hospital, both in Anambra State, South-East Nigeria.

Head injury was defined as a definite history of blow to the head with or without laceration of the scalp, or altered consciousness, no matter how brief.<sup>17</sup> In these patients, a high resolution CT scan of the temporal bone was ordered at the time of injury when indicated. The CT indications were bleeding from the ear or nose, scalp haematoma, bruising or laceration around the ear region, watery otorrhoea or rhinorrhoea, persistent hearing loss or vertigo, facial palsy and orbital haematoma.

All patients were positioned supine on the scanning couch and images were acquired at 2.5mm axial cuts at skull base through the brain to the vertex using GE Brightspeed and 32-slice Toshiba Alexion CT Machines at NAUTH and Iyien Mission Hospitals respectively. However, reformatting was done at 0.5mm cuts in sagittal, coronal and axial planes to facilitate evaluation of the petrous temporal bone and its components. The CT images were independently evaluated by two consultant radiologists and the findings entered into a pre-designed data

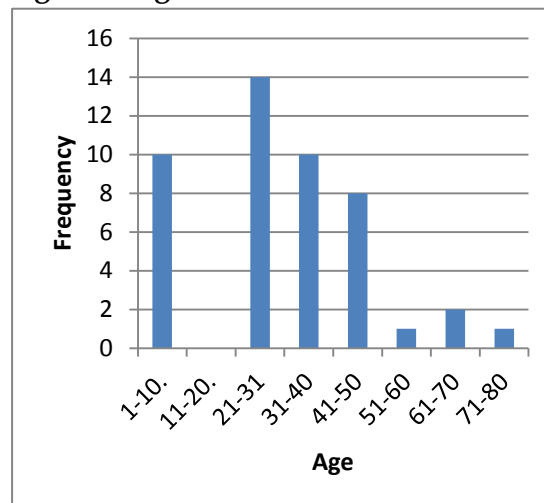
sheet. Patients biodata including age and gender were also recorded. The patients whom their CT images showed evidence of petrous temporal bone fracture were included in this study. The findings of other associated skull fractures and/or intracranial haemorrhage together with the petrous fractures were also considered as inclusion criteria. CT images of patients without petrous bone fractures were excluded from the study. To protect the eyes of patients, acquisition for the relevant field of view began at the orbitomeatal baseline which excludes most of the orbits bilaterally but includes the petrous bones. Data analysis was done using Statistical Package for Social Sciences (IBM SPSS statistics for windows, Version 21.0. Armonk, NY: IBM Corp). The results were represented in frequency tables and bar charts. Pearson's Chi squared test or Fisher's Exact test where appropriate were used to determine the association between petrous bone fractures and intracranial haemorrhage. Statistical significance was inferred at p-value of less than or equal to 0.05

#### RESULTS:

Forty-six (29.6%) subjects out of 173 cases of head injury were recruited for this study. Age of patients ranged from 1.4 to 80 years with a mean age of 30.38 years  $\pm$ 17.4. Subjects aged 21 to 30 years 12(27.3%) were of the highest frequency; followed by 1 to 10 years, 10(22.7%) and 31 to 40 years, 10 (22.7%). The least fell within the 11 to 20 years age group 0(0%).

Longitudinal petrous bone fractures had the highest frequency, 27 (61.4%) with the least being mixed petrous bone fracture, 3(6.8%) as shown in table 1. CT images showing petrous fracture types are shown in Figs 2 - 4.

**Figure 1. Age distribution**

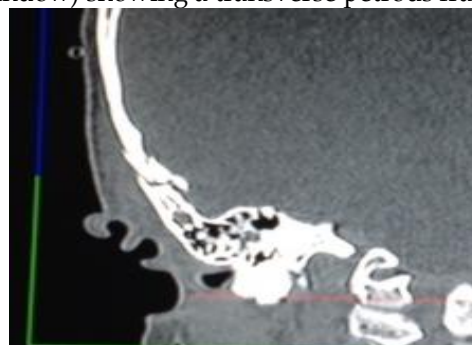


Among the intracranial haemorrhages, intracerebral 31(33.3%) had the highest frequency while epidural 5 (5.4%) was the least. An association between mixed petrous fractures and intracerebral haemorrhage was established, *p-value* 0.042. The rest of the haemorrhages showed no association with the types of petrous bone fractures ( Table 2 ).

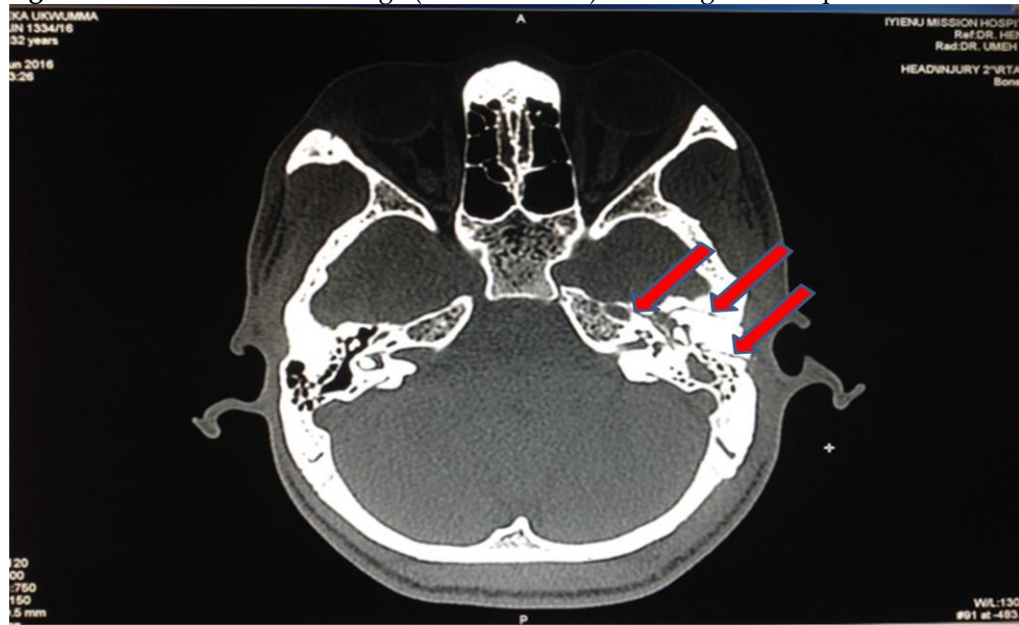
Among the calvarial fractures seen in patients with petrous bone fractures, parietal bone fractures had the highest frequency 19(33.9%) while the least frequency was seen in frontal sinus fractures, 1 (1.8%) as well as ethmoidal sinus fractures which also has a similar frequency of 1(1.8%). Also no association was established between these calvarial fractures and the petrous bone fractures, (Table 3).

There were more male patients 37 (80.4%) compared to their female counterparts 9(19.6%) with petrous fractures. This was not statistically significant (*p*= 0.710).

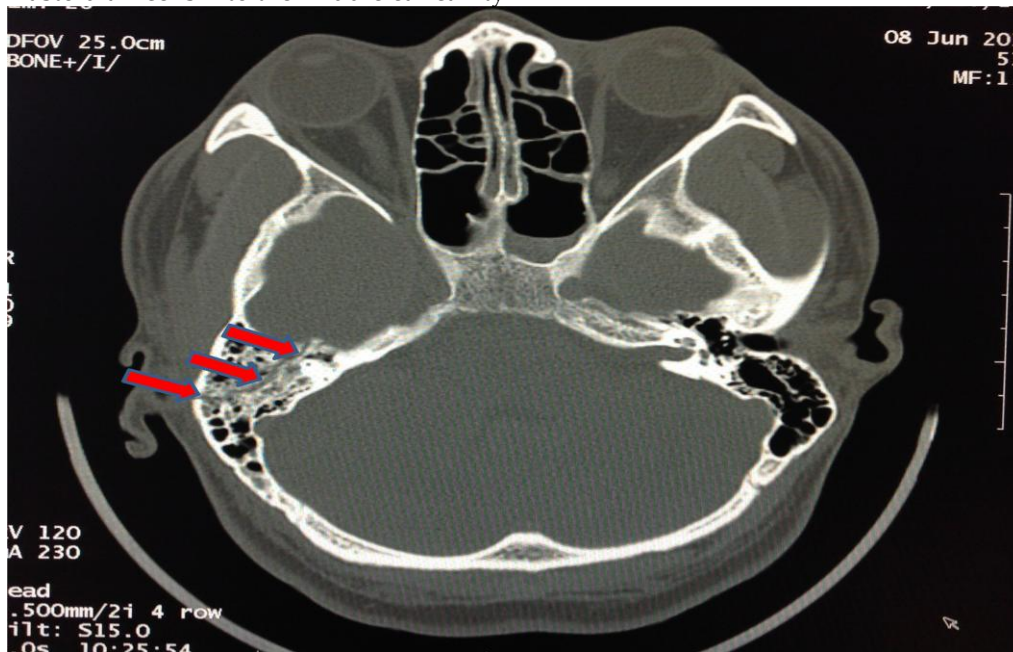
**Figure 2.** Reformatted coronal image (Bone Window) showing a transverse petrous fracture



**Figure 3.** Reformatted axial image (Bone Window) showing a mixed petrous fracture



**Figure 4.** Axial CT image showing a right longitudinal fracture extending through the mastoid air cells into the middle ear cavity



**Table 1.** Types of petrous bone fractures

	Frequency	Percent
Transverse	14	31.8
Longitudinal	27	61.4
Mixed	3	6.8
<b>Total</b>	<b>44</b>	<b>100.0</b>



**Table 2.** Petrous fractures and intracranial haemorrhage.

Types of PTB fractures	Types of bleeding		X2	P-value
	YES	NO		
	<b>Intra cavity bleed</b>			
	YES	NO		
Transverse	3	11	3.223	0.073
Longitudinal	14	13	3.462	0.063
Mixed	1	2	0.076	0.638
	<b>Intra-cerebral Bleed</b>			
Transverse	8	6	0.374	0.541
Longitudinal	20	7	3.290	0.070
Mixed	3	0	5.634	0.042*
	<b>Subdural Bleed</b>			
Transverse	2	12	2.909	0.84
Longitudinal	11	16	2.564	1.09
Mixed	1	2	0.003	0.693
	<b>Epidural Bleed</b>			
Transverse	2	12	0.174	0.515
Longitudinal	3	24	0.004	0.947
Mixed	3	0	0.413	0.690
	<b>Subarachnoid bleed</b>			
Transverse	5	9	3.727	0.054
Longitudinal	18	9	2.763	0.096
Mixed	2	1	0.127	0.604

\*  $p < 0.05$ . P-value 0.042 shows significant association between mixed petrous fractures and intra-cerebral haemorrhage.

**Table 3.** Petrous fractures and other skull fractures

Type of PTB fractures	Other skull fractures	X <sup>2</sup>	P value	
	<b>Zygomatic Fracture</b>			
	YES	NO		
Transverse	2	12	1.802	0.234
Longitudinal	1	26	1.067	0.329
Mixed	3	0	0.236	0.805
	<b>Maxillary Sinus Fracture</b>			
Transverse	1	13	0.319	0.54
Longitudinal	1	26	0.114	0.629
Mixed	3	0	0.153	0.867
	<b>Frontal Sinus Fracture</b>			
Transverse	0	14	0.478	0.682
Longitudinal	1	26	0.644	0.614
Mixed	3	0	0.75	0.93
	<b>Sphenoidal Fracture</b>			
Transverse	2	12	1.257	0.232
Longitudinal	8	19	0.799	0.300
Mixed	1	2	0.118	0.580
	<b>Ethmoidal Fracture</b>			
Transverse	14	0	0.478	0.682
Longitudinal	1	26	0.644	0.614
Mixed	3	0	0.75	0.932
	<b>Orbital Fracture</b>			
Transverse	1	13	0.094	0.621
Longitudinal	2	25	0.240	0.504
Mixed	1	2	2.289	0.254
	<b>Occipital Fracture</b>			
Transverse	5	9	2.939	0.97
Longitudinal	4	23	1.306	0.215
Mixed	3	0	2.939	0.97
	<b>Parietal Fracture</b>			
Transverse	5	9	0.467	0.363
Longitudinal	14	13	2.141	0.174
Mixed	3	0	2.447	0.143

$P < 0.05$ . No significant association found between petrous fractures and other calvarial fractures

## DISCUSSION

Most of the petrous bone fractures were in young people, with four times male predominance consistent with epidemiological data in previous studies.<sup>1, 3,13,14</sup> One of these studies reported on statistical significance which was also similar to findings in our study. The incidence of petrous bone fracture was 26.6% of the total number of cases of head injury seen. This incidence was higher when compared to other studies which are foreign literature.<sup>1,17,18,19</sup> Local literatures on particularly petrous fractures are scarce. This can be indicative of more severe forces involved in the cause of head injury in our population.

Zamsil *et al.*, in a one-year review of head injury with temporal bone fractures, found out that out of 1309 patients, 61(4.7%) patients were diagnosed of having temporal bone fractures.<sup>1</sup> The right temporal bone was more frequently fractured (62.3%) with most being of the petromastoid type (88.5%). Sixty seven percent of the petrous fractures were of the longitudinal type. In this study, the majority of the petrous bone fractures were of the longitudinal type (61.4%), in concordance with findings in some previous studies.<sup>1,17, 20</sup> No case of bilateral petrous bone fracture was seen in this study in concordance with findings in a study by Zamsil *et al.* despite the incidence of 10–15% reported.<sup>17,18</sup>

Due to the rough anatomy of the petrous bone, a shearing force may injure the vessels that are in close proximity, such as the petrous portion of the carotid artery, large venous structures, as well as the dural attachments of the temporal bone in the middle and posterior fossa leading to intracranial bleeding. Thus, patients with skull fractures also frequently experience critical intracranial injuries such as subarachnoid, subdural, epidural haemorrhage, brain contusions and cerebral edema that often require early management. In this study, some of the patients also had intracranial haemorrhages. However, the mixed fractures were found to be strongly

associated with intracerebral haemorrhage in this study despite longitudinal fractures being the commonest. This is contrary to findings in previous studies where mixed fractures were reported to be associated with more injury to the cochlear, labyrinth and other middle or inner ear structures and that by Zamsil *et al.* where longitudinal fractures were significantly associated with intracranial haemorrhage.<sup>3,17</sup>

Intracerebral haemorrhage was the most common intracranial bleed in this study, contrary to previous reports, where subdural haemorrhage was the most common.<sup>1,21,22,23</sup> In contrast, another study revealed that epidural and subarachnoid bleeds are more significantly associated with petrous fractures.<sup>3</sup> However, the majority of our patients were young patients, elasticity of the arterial vessels in these patients may be the reason for the lack of association between epidural hematomas and petrous fracture in this study. Among the other types of skull fractures found in cases of petrous fractures, the parietal bone fractures were the most common, but no association was found between any of these skull fractures and the various types of petrous bone fractures.

The poor association between the types of petrous bone fractures and the complications may be due to the relatively small number of cases of petrous fractures(46). This is a limiting factor for the study.

Dahiya *et al.* reported that up to one third of temporal bone fractures, remain undetected during the initial assessments.<sup>3</sup> Thus the number of cases may have been greater had a second review been done.

## CONCLUSION

In this study, a significantly greater proportion of petrous bone fractures were found in young adults, with the most common type being longitudinal; however, only mixed petrous bone fractures were significantly associated with intracranial haemorrhage. A larger sample size is recommended to reach more definite

conclusions on petrous bone fractures and its serious complications.

#### REFERENCES

- Zamsil AA, Raja A, Jamalludin R, Rosmida AY, Norie K. Pattern of intracranial haemorrhage in petrous temporal bone fracture. *Auris Nasus Larynx* 2012; 39: 151 - 155.
- Brodie HA, Thompson TC. Management of complications from 820 temporal bone fractures. *Am J Otolaryngol* 1997; 18: 188-197
- Dahiya R, Keller JD, Litofsky NS, Bankey PE, Bonassar LJ, Megerian CA. Temporal bone fractures: otic capsule sparing versus otic capsule violating clinical and radiographic considerations. *J Trauma* 1999; 47: 1079-1083.
- Vogt TJ, Juergens M, Balzer JO. Glomus tumours of the skull base: combined use of MR angiography and Spin-echo imaging. *Radiography* 1994; 192: 3-110.
- Avrahami E, Chen Z, Solomon A. Modern high resolution computed tomography (CT) diagnosis of longitudinal fractures of the petrous bone. *Neuroradiology* 1988; 30: 166-168.
- Griffin JE, Altenau MM, Schaefer SD. Bilateral longitudinal temporal bone fractures: a retrospective review of seventeen cases. *Laryngoscope* 1979; 89: 1432-1435.
- Canon CR, Jahrsdoerfer RA. Temporal bone fractures: review of 90 cases. *Arch Otolaryngol* 1983; 109: 285-288.
- Johnson F, Semaan MT, Megerian CA. Temporal bone fracture, evaluation and management in the modern era. *Otolaryngol Clin North Am* 2008; 41: 597-618.
- Olabinri EO, Ogbole GI, Adeleye AO, Dairo DM, Malomo AO, Ogunseyinde AO. Comparative analysis of clinical and computed tomography features of basal skull fractures in head injury in Southwestern Nigeria. *J Neurosci Rural Pract* 2015; 6: 139-144.
- Amin Z, Saynti R, Kahairi A, Isiah W, Ahmad R. Head injury with temporal bone fractures: one year review of case incidence, causes, clinical features and outcome. *Med J Malaysia* 2003; 63: 373-378.
- Yetisar S, Hidir Y, Gonul E. Facial nerve problems and hearing loss in patients with temporal bone fractures: demographic data. *J Trauma* 2008; 65: 131-1320.
- Low HL, Redfren RM. Isolated chordatympanic injury following petrous temporal fracture. *J Clin Neurosci* 2008; 15: 716 - 718.
- Tiret L, Hausherr E, Thicoipe M, Garros B, Maurette P, Castel JP, et al. The epidemiology of head trauma in Aquitaine (France), 1986): a community based study of hospital admissions and deaths. *Int J Epidemiol* 1990; 19: 133 -140.
- Eid HO, Barss P, Adam SH, Torab FC, Lunsjo K, Grivna M, et al. Factors affecting anatomical region of injury, severity and mortality for road trauma in a high-income developing country: lessons for prevention. *Injury* 2009; 40: 703-707.
- Phelps PD, Stansibie JM. Glomus jugulare or tympanicum? The role of CT & MR imaging with gadolinium DTPA. *J Laryngol Otol* 1988; 102: 766-776.
- Phelps PD, Wright A. Imaging cholesteatoma. *Clin Radiol* 1990; 4: 156-162.
- Ishman SL, Friedland DR. Temporal bone fractures: Traditional classification and clinical relevance. *Laryngoscope* 2004; 114: 1734-1741.
- Lee HJ, Lum C, Means K, Chandrasekhar S, Brown L, Holoday A, et al. Temporal bone fractures and complications: Correlation between high-resolution computed tomography and audiography. *Emerg Radiol* 1998; 5: 8-12.
- Saraiya PS, Aygun N. Temporal bone fractures. *Emerg Radiol* 2009; 16: 225-265.
- Johnson F, Semaan MT, Megerian CA. Temporal bone fracture: evaluation and management in the modern era. *Otolaryngol Clin North Am* 2008; 41: 597-618.
- Hasso AN, Ledington JA. Traumatic injuries of the temporal bone. *Otolaryngol Clin North Am* 1988; 21: 295-316.
- Yadonawa M, Tamura M, Tsukahara, Ohe C. Skull fracture and intracranial complications in blunt head injury with special reference to comparison between children and adults. *Neurol Med Chir* 1984; 24: 615-621.
- Alvi A, Bereliani A. Acute intracranial complications of temporal bone trauma. *Otolaryngol Head Neck Surg* 1998; 119: 609-613.