

## CASE REPORTS

## Thyroglossal duct cyst in adult Nigerians: a report of two cases

Daniel ALIYU<sup>1</sup>Baba S AMUTTA<sup>1</sup>

Mohammed

ABDULLAHI<sup>1</sup>Caleb MANYA<sup>1</sup>Joseph SOLOMON<sup>1</sup>Kabiru ABDULLAH<sup>2</sup>

<sup>1</sup>Dept of Ear, Nose and Throat  
Usmanu Danfodiyo University  
Teaching Hospital Sokoto  
NIGERIA

<sup>2</sup>Dept of Pathology  
Usmanu Danfodiyo University  
Teaching Hospital Sokoto  
NIGERIA

**Author for Correspondence**

Daniel J ALIYU

Dept of Ear, Nose and Throat  
Usmanu Danfodiyo University  
Teaching Hospital Sokoto  
NIGERIA

E-mail: danoaliyu@yahoo.com

Phone: +234 803 597 8720

Received: July 7<sup>th</sup>, 2015Accepted: November 18<sup>th</sup>, 2015

Paper Presented at the 5th  
World Congress of IFHNOS  
and Annual Meeting of the  
AHNS held in New York City  
USA, July 26<sup>th</sup> – 30<sup>th</sup>, 2014.

Paper ID: PO705

DISCLOSURES: NONE

## INTRODUCTION

Thyroglossal duct cysts (TGDC) are the most common congenital upper neck midline

## ABSTRACT

Thyroglossal duct cyst (TGDC) is the most common paediatric midline neck lesion. It is rare in the adult population. Metaplastic change is mostly associated with the adult variant. We report the first ever cases of thyroglossal duct cyst in the adult as seen in our region, with a review of literature.

**Case Report 1.** A 42-year old man, presented with a painless anterior neck swelling of more than 3 months' duration. Neck examination revealed a midline 4cm x 6cm cyst below the hyoid bone, which moved on deglutition and on protrusion of the tongue. Thyroid function test was within normal values. Histology of the excised cyst (Sistrunk's operation) confirmed thyroglossal cyst.

**Case Report 2.** A 20-year old female student presented with a midline neck swelling of 5 years' duration. Examination showed a 3cm x 4cm cystic non-tender midline anterior neck mass that moved on deglutition and on tongue protrusion. Thyroid function test showed a slight elevation in levels of T3 and T4. A neck ultrasound scan revealed an oval hypoechoic mass on the left thyroid cartilage of the larynx. She had a modified Sistrunk's operation and histology confirmed the diagnosis of thyroglossal cyst.

**Conclusion:** Thyroglossal duct cyst commonly presents as a midline anterior neck asymptomatic swelling. Its tendency to undergo malignant degeneration in adults emphasizes the importance of meticulous clinical, radiological and histological evaluation.

**Keywords:** Adults, excision, histology, malignant degeneration, neck mass, Sistrunk

lesions in paediatric populations.<sup>1</sup> The cyst presents as a painless, gradually enlarging soft mass or lump at any level between the

foramen caecum on the posterior third of the tongue and the upper mediastinum. Majority are located at about the level of the hyoid bone. It results from failure in obliteration of the embryogenic thyroglossal duct that connects the foramen caecum of the tongue to the thyroid gland during its migration at the 6<sup>th</sup> week of gestation.<sup>2</sup>

Most cysts present in early childhood but, may not become symptomatic or clinically apparent until adulthood. Adult manifestation of thyroglossal duct cyst is quite rare. It may present with fistula, which usually occurs as a result of an infected cyst drained surgically or spontaneously.<sup>3</sup> Available statistics showed that 70% the lesion is usually recognized by the age of 5 years, and 60% are diagnosed before age 20 years, and on the whole, 7% of the general population manifests this lesion.<sup>3,4</sup> There are reported studies of male sex preponderance.<sup>4</sup>

Although diagnosis can be by clinical assessment, imaging studies of the cyst and thyroid hormone analysis are important for accurate diagnosis. The Sistrunk's operation, first described in 1920, is still the standard surgical procedure for the treatment of thyroglossal duct cyst.<sup>3,4</sup> The procedure significantly reduces the rate of recurrence, which is the most common complication.

In this study, we report two cases of thyroglossal duct cyst in two adult Nigerians, who presented for surgical management.

#### CASE REPORTS

**Case 1.** A 42-year old man, a cement company engineer, with a painless anterior neck swelling, which was first noticed by his friend, more than three months before presentation. Clinical examination of the neck revealed a midline 4cm x 6cm cyst below the hyoid bone, which moved on deglutition and on protrusion of the tongue. There was no associated cervical lymphadenopathy and vocal cord function was normal. Thyroid function test normal values tri-iodothyronine ( $T_3$  - 1.58ng/ml) and thyroxine ( $T_4$  - 4.45ng/ml). Neck ultrasonography scans showed a multi-

septate cystic anterior neck mass with separate normal thyroid gland. Other laboratory investigations were within normal limits. The patient, subsequently, had Sistrunk's operation and was discharged home on the 7<sup>th</sup> post-operative day. Histology of the excised mass confirmed a thyroglossal cyst. He has been followed up for 2 years with no evidence of recurrence.

**Case 2.** A 25-year old female university undergraduate student, presented with a midline neck swelling of 5 years' duration. No history of frequent painful episodes, voice change or symptoms of thyrotoxicosis. Clinical examination showed a 3cm x 4cm cystic non-tender midline neck mass which moved with deglutition and with tongue protrusion with no palpable cervical lymphadenopathy. Thyroid function test showed a slight elevation in the levels of tri-iodothyronine ( $T_3$  - 2.84ng/ml) and thyroxine ( $T_4$  - 15.04ng/ml). Ultrasonography revealed an oval hypo-echoic mass on the left thyroid cartilage of the larynx and separate normal thyroid gland. She, subsequently, had the cyst excised by the Sistrunk's operation, and histology confirmed the diagnosis of thyroglossal cyst. The patient was discharged home on the 8<sup>th</sup> post-operative day and has been followed-up for 18 months, with no evidence of recurrence.

#### DISCUSSION

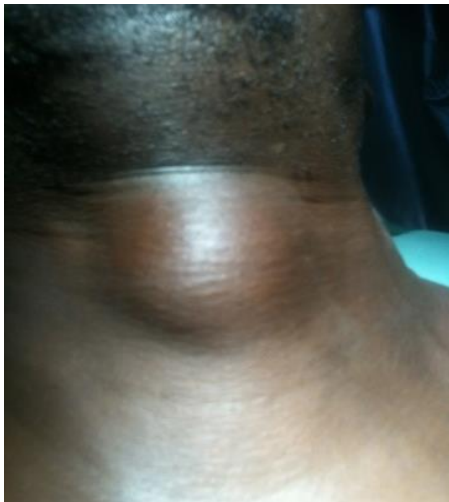Thyroglossal duct cysts (TGDC) are the most common congenital upper neck midline lesions encountered in children.<sup>1,2</sup> An incidence of approximately 7% of the population has been reported for the occurrence of TGDC.<sup>2</sup> Usually recognized during the first 5 years of life, it accounts for approximately 70% of congenital neck malformations.<sup>2</sup>

Available statistics show that in 62% of the adult variant, the cyst may contain ectopic and functional thyroid tissue, which is a risk factor in the development of thyroid-related tumours.<sup>3</sup> Failure of obliteration of ducts at the 10<sup>th</sup> week of foetal life results in the development of cystic dilatation at any time in life. They are usually sporadic, but a rare

familial variant has been documented, and identified as an autosomal dominant in pre-pubertal girls.<sup>5,6</sup>

Adult presentation is infrequent and can pose a diagnostic challenge, as the lesions are not often considered in the differential diagnosis of cervical masses in this population (Figure 1). Although anterior neck mass and infection are the most common presenting symptoms, the adult variants tended to present with a broader spectrum of symptoms including pain, dysphagia, sore throat, hoarseness and fistula formation.<sup>4</sup>This spectrum of symptoms makes the diagnosis of TGDC more difficult.

Figure 1. Anterior neck swelling in an adult, thyroglossal duct cyst



Thyroglossal duct cysts uncommonly stay for a long time and might undergo metaplastic change. Malignant transformation does occur in the adult TGDC but are rare, being seen in <1% of cases. Ewing, *et al.* studied 47 patients with tissue diagnosis of TGDC and reported malignant degeneration in 2 patients above the age of 20 years.<sup>6</sup>The most frequently reported malignancy is the papillary thyroid carcinoma.<sup>6</sup>Documented reports show a sex variation with male to female ratio of 3.1:1, in the study reported by Ahmed.<sup>8</sup>

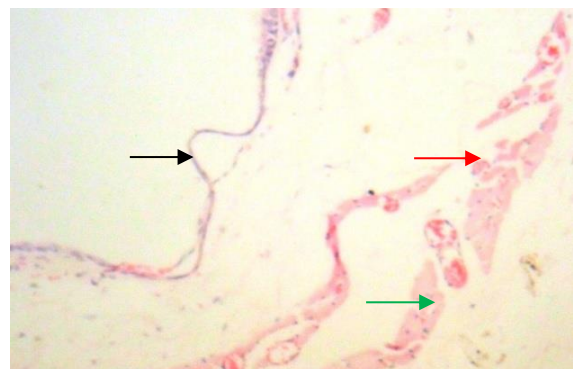
Ninety-five percent of thyroglossal duct cysts is reported to present in the midline near the level of the hyoid bone.<sup>1,2,4</sup> A study by Allard had 60% of TGDC located adjacent to the hyoid bone, 24% were between the hyoid

bone and base of the tongue, 13% between the hyoid bone and pyramidal lobe of the thyroid gland, and 3% intralingual.<sup>5</sup> In our cases, the cysts were located adjacent to hyoid bone similar to study conducted by Ahmed.

Its close proximity to the oral cavity makes the TGDC prone to infections. Previous or concurrent infections of the cyst were reported in one-third of patients, and the risk of infection is the primary reason for surgical intervention.<sup>9,10,11</sup> Common pathogens implicated are *haemophilus influenza*, *staphylococcus aureus* and *staphylococcus epidermidis*. There was no history of recurrent infection in our patients.

In patients with TGDC, pre-operative sonographic identification of a normal thyroid gland confirms a source of thyroid hormones, excludes ectopic thyroid and confirms the diagnosis. Ultrasonography and thyroid stimulating hormone analysis were employed in confirming the diagnosis in our patients. In the presence of a large cyst, suspicious of malignant transformation, or when a possibility of lingual thyroid is considered, computed tomography (CT) and magnetic resonance image (MRI) will be considered in order to accurately identify the lesion.<sup>12</sup>

Figure 2. Residual thyroid follicles are seen (green arrow) H&E x 100 magnification; wall of the cyst showing marked atrophy of the lining epithelium (black arrow) and myxoid change of the wall (red arrow)

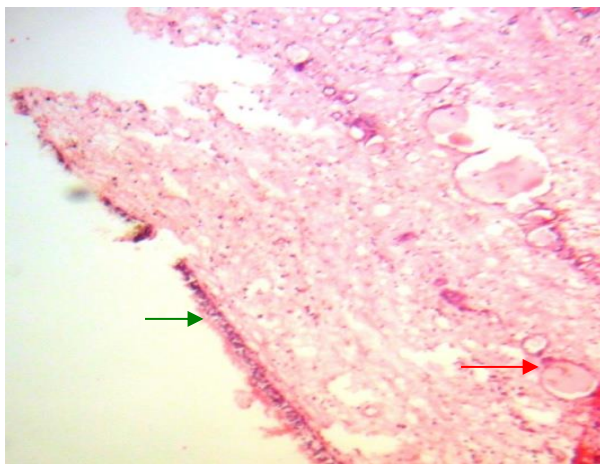


The role of fine needle aspiration in the diagnosis of thyroglossal cyst is limited. In a study by Ahmed, a combination of clinical



and radiological assessments resulted in a sensitivity of 85% in diagnosing TGDC.<sup>8</sup> The presence of residual thyroid follicles and marked atrophy of the lining pseudo-stratified columnar epithelium with myxoid changes of the cystic walls are the histopathological features in our patients (Figures 2 and 3). There were no metaplastic changes in our patients.

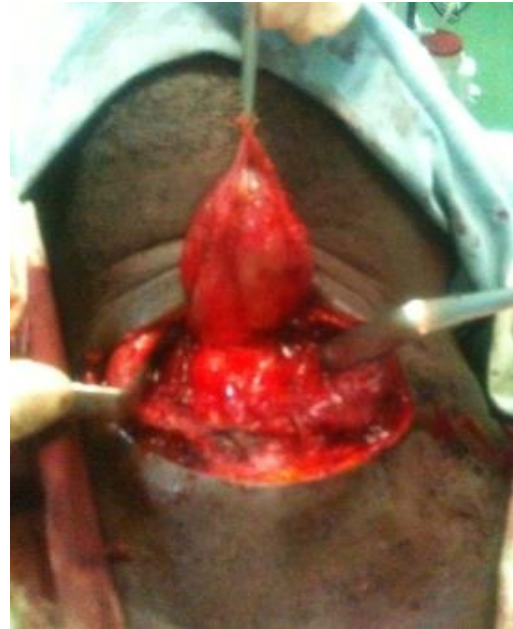Figure 3. Cyst showing pseudo-stratified columnar epithelium (green arrow) and thyroid follicles in the wall (red arrow); H & E x 100 magnification



The classical Sistrunk's operation, first described in 1920, is currently being employed as the standard surgical procedure in the treatment of TGDC.<sup>1</sup> This was the treatment modality which we employed in our cases. The operation entails removal of the mid-portion of the hyoid bone in continuity with the cyst and excision of a core of tissue between the hyoid bone and foramen caecum (Figure 4). The Sistrunk's procedure significantly reduces the rate of recurrence when compared with a simple excision or removal of the cyst alone as proposed by Shalang in 1893.<sup>13</sup>

In patients with TGDC who refuse surgery, the alternative procedure to surgical treatment is percutaneous ethanol injection.<sup>14,15</sup> Our patients were followed-up for 18 and 24 months, respectively, with no recurrence.

Figure 4. Thyroglossal duct cyst excised (Sistrunk's operation)



## CONCLUSION

This study emphasizes the need for thyroglossal duct cysts to be considered as part of the differential diagnosis of neck masses in adults as advocated by studies from other parts of the world. A combination of meticulous clinical assessment with imaging studies is imperative for the diagnosis. Despite the high rate of recurrence, Sistrunk's operation remains the standard treatment of choice.

## REFERENCES

1. Ricard S, Jean-Pierre J. Benign neck disease. In: John C Watkinson, Ralph Gilbert [eds]. In: Stell and Marans' Textbook of Head and Neck Surgery and Oncology. 5<sup>th</sup> edition, Hodder Anold 2012; 217-234.
2. Folley DS, Fallat ME. Thyroglossal duct cyst and other congenital midline cervical anomalies. *Seminars in Paediatric Surgery* 2006; 15:70-75.
3. Dedititis RA, Camargo DL, Peixoto GL, et al. Thyroglossal duct: a review of 55 cases. *J Am Coll Surg* 2002; 194:274 -277.
4. Brousseau VJ, Solares CA, Xu M, et al. Thyroglossal duct cysts: presentation and management in children versus adults. *Int J Pediatr Otorhinolaryngol* 2003; 67:1285-1290.
5. Allard RH. The thyroglossal cyst. *Head Neck Surg* 1982; 5:134-146.
6. Ewing CA, Kornblut A, Greeley C, Manz H. Presentations of thyroglossal duct cysts in adults. *Eur Arch Otorhinolaryngol* 1999; 256:136-

- 138.
7. Shahin A, Burroughs FH, Kirby JP, et al. Thyroglossal duct cyst: a cytopathologic study of 26 cases. *Diagn Cytopathol* 2005; 33:365-369.
  8. Ahmed YA, Ali IS. Management of thyroglossal duct cyst. *The Open Otorhinolaryngology Journal* 2008; 2:26-28.
  9. Shih-Tsang L, Fen-Yu T, Chuan-Jan H, Te-Huei Y, Yuh-Shyang C. Thyroglossal duct cyst: A comparison between Children and Adults. *American J ORL Head and Neck Med and Surg* 2008; 29: 83-87.
  10. Ostlie DJ, Burjonrappa SC, Synder CL. Thyroglossal ducts infection and surgical outcome. *J Pead Surg* 2004; 39(3): 396-399.
  11. Shah R, Gow K, Sobol SE. Outcome of thyroglossal duct cyst excision in independent of presenting age or symptomatology *International Journal of Paediatric ORL* 2007; 71:1731-1735.
  12. Lev S, Lev MH. Imaging of cystic lesions. *Radiologic Clinics of North America* 2000; 38:1013-1027.
  13. Patel NN, Hartley BE, Howard DJ. Management of thyroglossal tract disease after failed Sistrunk's Procedure. *J Laryngol Otol* 2003; 117(9): 710-712.
  14. Perkins JA, Inglis AF, Sie KC, Manning SC. Recurrent thyroglossal duct cysts: A 23 year experience and new method of management. *Ann. ORL* 2006; 115: 850-856.
  15. Sudhir MN, Sarika SN. An overview of 22 thyroglossal cyst managed in KVG medical college. *International Journal of Head and Neck Surg* 2011; 2(1): 5-7.