

## CASE REPORT

## Primary vaginismus: treatment with botulinum toxin

Mairo A HASSAN  
Yakubu AHMED  
Abubakar A PANTI  
Sadiya NASIR  
Karima A TUNAU  
Amina G UMAR  
Constance E SHEHU  
Aaron E UKWU

*Department of Obstetrics &  
Gynaecology, Usmanu Danfodiyo  
University Teaching Hospital  
Sokoto, NIGERIA*

Author for Correspondence

Dr Mairo A HASSAN  
*Department of Obstetrics &  
Gynaecology, Usmanu  
Danfodiyo University  
Teaching Hospital Sokoto  
Sokoto State, NIGERIA*

*Email: mayroh123@gmail.com  
Phone: +234-803-504-1729*

*Received: November 4<sup>th</sup>, 2015  
Accepted: December 5<sup>th</sup>, 2015*

DISCLOSURES: NONE

## ABSTRACT

**Background:** Vaginismus is a rare condition. It may result in unconsummated marriages with subsequent marital disharmony. The most severe forms of these spasms of the vaginal muscles are often refractory to a variety of conventional treatment.

**Case Report:** The index case was a 35-year old nulligravid, civil servant who presented to the gynaecological outpatient clinic with a complaint of inability to have coitus since she married 5 years prior to presentation. She had several counselling sessions by both gynaecologists and psychiatrists, and had used several forms of treatment with improvement in her condition. She, subsequently, had successful treatment with intra-vaginal botulinum toxin injection.

**Conclusion:** In cases of severe vaginismus, botulinum toxin injection can be considered as a first line option of treatment.

**Keywords:** Botox<sup>R</sup>, fear, penetration, spasm, vaginal

## INTRODUCTION

Vaginismus is uncontrolled painful spasm involving the muscles surrounding the vagina which can be triggered by any stimulation near the vagina or even the thought of any form of vaginal penetration such as tampon insertion, speculum examination, etc.<sup>1</sup> Fear of penetration is the over-riding emotion and often gives rise to considerable reactions.<sup>1</sup> The

cause of vaginismus is generally unknown, but numerous theories exist and in some instances specific cause of vaginismus like childhood sexual abuse, fear of getting pregnant may be identified, but for the most part the cause is unknown.<sup>2</sup>

Vaginismus is relatively rare, affecting about 1% of women.<sup>3</sup> Vaginismus is diagnosed

usually when the thought of speculum examination induces an unexpected physiological response which may start as fear and shaking and sometimes sweating, nausea and vomiting. The patient actually has no control of this response. Others may present for the first time with the inability to consummate their marriages.<sup>2,4</sup>

Vaginismus is classified as either primary or secondary vaginismus. It can also be classified according to severity using the Lamont Classification as first, second, third, fourth and fifth degree vaginismus.<sup>5</sup>

In first degree vaginismus, the muscles of the vagina are noted to be tight, but the patient is able to relax with reassurance. In second degree vaginismus the muscles are in a state of contraction and the patient is unable to relax. Patients with third degree vaginismus present with spasm of vaginal muscles and raise their buttocks to avoid being examined. Fourth degree vaginismus is a severe form of vaginismus characterized by severe spasm of the vaginal muscles combined with considerable fear. The patient elevates her buttocks, retreats and closes her thighs. In the fifth degree the retreat is so severe that the patient is ready to jump from the examination table and exhibit major physiological reaction of palpitations, hyperventilation, sweating, nausea or vomiting.

Various forms of treatment exist for treatment of vaginismus, ranging from counselling, psychotherapy, hypnotherapy, use of vaginal dilators, use of drugs, etc. However, none of these methods has withstood well controlled scientific studies.<sup>1</sup> Severe forms of vaginismus often, do not respond to these treatments rather, the women experience years of unsuccessful treatment associated with frustration and marital disharmony.<sup>6</sup>

The use of botulinum toxin (Botox<sup>®</sup>) injection intra-vaginally and progressive vaginal dilatation under anaesthesia have been shown to cure primary vaginismus within a short time.<sup>7</sup>

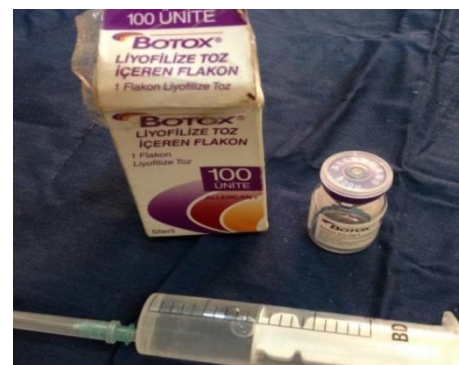A case of primary vaginismus of 8years' duration, which was successfully treated with Botox<sup>®</sup> injection, after failed treatment with routinely used methods available in our environment, is being reported.

#### CASE REPORT

A 35-year old nulligravida presented to the gynaecological outpatient clinic with a complaint of inability to have coitus since she married 5years prior to presentation. She has desire for sex and achieves arousal but experiences severe vaginal pain with attempt at penetrative sex. There was no history of any form of sexual abuse, psychiatric disorder or history suggestive of strict home values regarding sex. Systemic review and physical examination yielded no significant findings; however, the patient declined vaginal examination. She was then managed as a case of primary vaginismus (*Grade 4*).

She had several counselling sessions by both gynaecologists and psychiatrists, she had also used anxiolytics but, none of them was effective. She had been counselled on self-use of vaginal dilators but, she could not use it. The patient was lost to follow-up for a period of one year before she re-presented to us again. She stopped coming to the hospital because she was temporarily separated from her husband due to her problem. It was, then, decided to try the use of botulinum toxin (Botox<sup>®</sup>) injection (*Figure 1*), and the patient was fully counselled on the procedure and her consent obtained.

Figure 1. Botox<sup>®</sup> injection



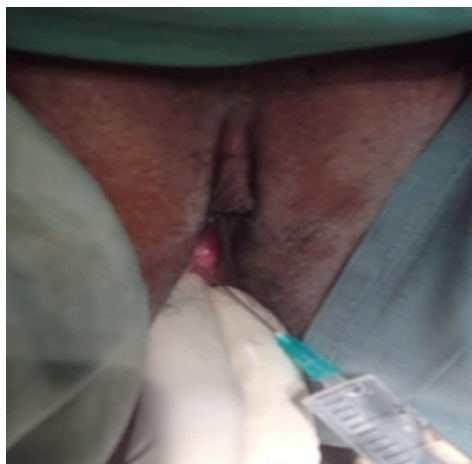
Pre-procedure investigations reported packed cell volume as 35%, normal urinalysis, normal

urea, normal electrolytes and normal creatinine values.

### Procedure

The procedure was performed in the theatre under sedation with the patient in lithotomy position. Following routine cleansing and draping, the areas of maximum spasm of the vaginal muscles were identified to determine where the Botox<sup>R</sup> should be injected. This area was manually massaged to relax the muscles. An injection of Botox<sup>R</sup> 150 units was administered intra-vaginally into the bulbocavernosus, pubococcygeus and puborectalis muscles along with the lateral walls of the vagina (Figure 2).

Figure 2. Injecting Botox<sup>R</sup> intra-vaginally into the muscles



This is followed by additional injection of a long acting local anaesthetic bupivacaine. After this the vagina was progressively dilated while the patient was under anaesthesia with dilators coated with a topical local anaesthetic (lignocaine jelly). Finally, the large size dilator was left in the vagina.

Post-operatively, the dilator was removed after 3hours. She continued to have supervised dilation and counselling for 3days. She was, subsequently, discharged home and given instructions on the proper use of the dilators and eventual transition to intercourse with the husband.

### Follow-up

She returned on follow-up one week after discharge with no complaint. She had moved

back into the husband's house after the procedure as advised. She had successfully been able to insert the biggest dilator with no difficulty. By second week after the procedure the patient reported having achieved penetrative sexual intercourse. The next time we saw her in the clinic 6weeks later, she requested for advice on how she can get pregnant very soon. She was counselled on regular coitus.

### DISCUSSION

Vaginismus is a rare gynaecological condition seen in our environment. The diagnosis may be missed due to rarity of the condition; therefore, a high index of suspicion is important in recognizing the condition. Inability to have penetrative sex is the most common symptom as seen in this case.<sup>8</sup> The diagnosis is usually clinical.

The use of Botox<sup>R</sup> as a treatment for cosmetic reasons has been well known for a long time; it relaxes the muscles in the face so that smile lines and deep wrinkles do not appear. But, it is the very action of relaxing muscle tension that has led to its success in the treatment of severe vaginismus where other treatments have failed.

Botulinum toxin is a neurotoxin produced by *clostridium botulinum*, a spore-forming anaerobic bacillus, which appears to affect only the pre-synaptic membrane of the neuromuscular junction in humans, where it prevents calcium-dependent release of acetylcholine and produces a state of denervation. Muscle inactivation persists until new fibrils grow from the nerve and form junction plates on new areas of the muscle cell walls. Botulinum toxin paralyzes muscles by the prevention of acetylcholine release. The extent of paralysis depends on the amount of toxin to which there is exposure, relative to muscle bulk.<sup>4</sup>The neuromuscular blockade is permanent, and recovery of function results from the establishment of new neuromuscular junctions by a process of terminal axonal and nodal sprouting. Botox<sup>R</sup> injection allows for a break of the muscle spasm that causes the

tightening of the vagina which causes painful intercourse.

After the procedure, the patient awakens having already achieved relaxation of the vaginal muscles which is usually the hardest first step. The topical anaesthesia that was applied, works to ensure painless, progressive dilatation of the vagina. The patient recovers from anaesthesia with the largest dilator in place and with no discomfort following this. She is, then, supervised on daily vaginal dilatation in order to become comfortable moving the dilators in and out of the vagina.

The patient presented later, having successfully inserted all the different sizes of dilators without any difficulty, after the use of Botox<sup>®</sup> injection. Botox<sup>®</sup>, when used properly, is considered to be very safe and effective.<sup>9</sup> Risk and complications are minimal. When Botox<sup>®</sup> is used in the vagina it is best to avoid areas near the urethra, bladder and rectum to prevent incontinence. For this reason the injection in this patient was administered only along the lateral walls of the vagina. She did not develop any stress or stool incontinence during the period of follow-up.

#### CONCLUSION

A high index of suspicion is needed for the diagnosis of vaginismus because it is rare in our environment. Botulinum injection for the treatment of severe vaginismus is a rapidly

growing and rewarding good first line option for patients with severe vaginismus.

#### REFERENCES

1. Brin MF, Vapnek JM. Treatment of vaginismus with botulinum toxin injections. (*Published as Erratum; appeared in Lancet 1997; 349-656*). *Lancet* 1997; 349: 252-253.
2. Borg C, Peter de Jong, Willibrord W. Vaginismus and Dyspareunia: Relationship with General and Sex-Related Moral Standards. *Journal of Sexual Medicine* 2011; 8 (1): 223-231.
3. Spector IP, Carey MP. Incidence and prevalence of the sexual dysfunctions: a critical review of the empirical literature. *Arch Sex Behav* 1990; 19:389-408.
4. Ghazizadeh S, Nikzad M. Botulinum toxin in the treatment of refractory vaginismus. *Obstet Gynecol* 2004; 104(5): 922-925.
5. Lamont JA. Vaginismus. *Am J Obstet Gynecol* 1978, Jul15; 131(6):633-636.
6. Pacik PT. Botox treatment for vaginismus. *Plastic and Reconstructive Surgery* 2009; 24455-24456.
7. Pacik PT. Review of current concept and treatment using Botox injections, Bupivacaine injection and progressive dilatation with the patient under anaesthesia. *Aesthesia Plastic Surg* 2011; Electronic copy version: 00110. 1007/s00266-011-9737-5.
8. Shafik A, Sibai O. Vaginismus. Results of treatment with botulinum toxin. *Obstet Gynecol* 2000; 20:300-302.
9. Reissing E, Yitzchak B, Samir K. Does Vaginismus Exist? A Critical Review of the Literature. *The Journal of Nervous and Mental Disease* 2013; 187(5): 261-274.