

CASE REPORT

Foreign body ingestion in children: case report and literature review

Emeka RAY-OFFOR^{1,2}

Njideka C ANEKE²

¹Department of Surgery
University of Port Harcourt
Teaching Hospital

Rivers State, NIGERIA

²Oak Endoscopy Centre
Port-Harcourt

Rivers State, NIGERIA

Author for Correspondence

Dr Emeka RAY-OFFOR

Department of Surgery
University of Port Harcourt
Teaching Hospital

PMB 6173 Port Harcourt

Rivers State, NIGERIA

Email: erayoffor@yahoo.com

Phone: +234-803-310-1168

Received: January 10th, 2015

Accepted: March 31st, 2015

DISCLOSURES: NONE

INTRODUCTION

Foreign bodies are commonly ingested in the paediatric age group. The peak age incidence is in the 6month - 6year age range.¹ Infants and children driven by a high level of curiosity place objects in their mouths. In most cases, once the objects are able to pass through the oesophagus they would exit the gastrointestinal tract, uneventfully. However, a significant percentage may require intervention, depending on the size, shape, type of FB, or underlying pathology in the patient.²

Studies have shown that coins are the most commonly ingested foreign body in children.^{3,4,5,6} Some other objects commonly ingested are toy parts, marbles, sharp objects

ABSTRACT

Foreign body (FB) ingestion is a common occurrence in children. In most cases these foreign bodies pass through the gastrointestinal tract uneventfully. The important considerations for intervention include size, shape, and composition of the FB. Also, the site of lodgement and underlying pathology in the patient with the unlikelihood of passage, are worthy of note. A 5-year old asymptomatic boy was referred to our service with a 1-week history of ingestion of a coin. A plain abdominal x-ray study done the day following the ingestion showed an oval shaped opacity in the area of the stomach. A prompt upper gastrointestinal (GI) endoscopy was performed under general anaesthesia with cuffed endotracheal intubation, following which, a two-penny British coin was retrieved from the stomach using *alligator* forceps passed through a flexible gastroscope. The patient was discharged a few hours after the procedure, in a stable condition. His 7th day post-procedure follow-up visit was uneventful. A prompt endoscopy for assessment and retrieval of foreign bodies in children reduces the risk of morbidity and duration of family anxiety.

Keywords: Anxiety, endoscopic retrieval, paediatric age group, uneventful passage

and disk batteries. In adults, the foreign body that is ingested more frequently is dental prosthesis, with the elderly, mentally impaired or patients with alcohol dependency, at greater risk.⁷ The adverse outcomes of foreign body ingestion are impaction, perforation, or obstruction, most often at the sites of acute angulation or physiologic narrowing.⁸ These sites are at the levels of the crico-pharyngeus muscle, gastro-oesophageal junction, pylorus and ileo-caecal valve.

The first step in managing such cases is accurate determination of the foreign body lodgement site. This can be done through plain radiographs, hand-held metal detectors, ultrasound scanning, computerised

tomography or magnetic resonance imaging, provided it is not a ferro-magnetic foreign object. Conservative management is advocated if the object has passed through the pylorus with serial clinical assessments including serial radiographs.⁹

There is, usually, a high level of anxiety in the parents of these children as they may not even be aware that the foreign bodies have been passed in stool. Endoscopy (rigid or flexible) is one of the several intervention techniques available for the treatment of foreign body ingestion. The flexible endoscope allows a thorough examination of the oesophagus, stomach and duodenum for mucosal integrity in addition to foreign body retrieval.

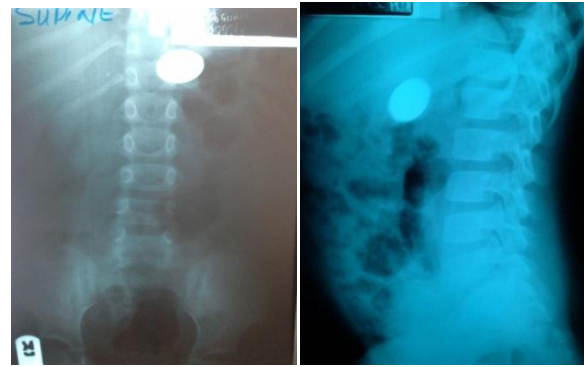
We report a case of a successful retrieval of a swallowed coin in a child using a flexible gastroscope and same-day discharge of patient from an endoscopy centre with no untoward complication. This highlights the utility in endoscopic intervention for foreign body ingestion in paediatric patients.

CASE REPORT

A 5-year old boy was referred to Oak Endoscopy Centre with a 1-week history of ingestion of a coin, for foreign body retrieval. No history of gagging, vomiting, abdominal pain, change in bowel habit or distension. A plain abdominal x-ray study done the day after the ingestion showed an oval shaped opacity in the area of the stomach. His parents delayed his presentation to hospital in the failed expectation that the coin would be passed per-rectum.

On examination, he was not in any distress, afebrile, anicteric, acyanosed, not pale and vital signs were normal. His chest was clinically clear, and abdomen was full, moved with respiration, soft, without tenderness in any region and without palpable organomegaly.

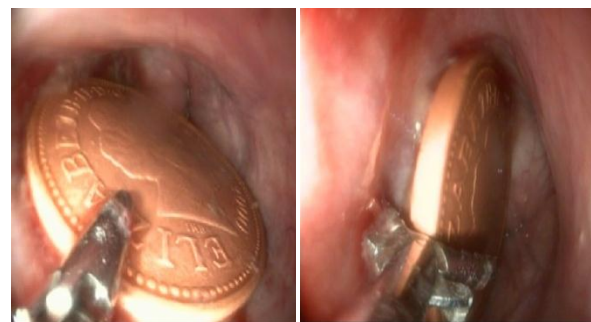Figure 1. Bi-planar radiographs before oesophagogastroduodenoscopy



A repeat bi-planar abdominal x-ray study still showed the opacity in the area of the stomach (Figure 1). The pre-endoscopy blood test results were as follows: packed cell value 37%; retroviral screening test - non-reactive; hepatitis-B surface antigen- seronegative.

A prompt upper GI endoscopy was performed on the same day under general anaesthesia with cuffed endotracheal intubation; preceded by a 5-hour of *nil per os* period. A two-penny British coin (Figure 2) was lodged in the greater curvature of the stomach covered by food debris. Using a pair of *alligator* forceps through a *Karl Storz 13801PKS* video gastroscope, the coin was grasped and carefully extracted with deflation of the endotracheal tube cuff as the coin passed through the crico-pharyngeus.

Figure 2. Flexible endoscopic retrieval of two pence coin



The patient was discharged home three hours after the procedure in a stable condition. On his follow-up visit on the 1st post-procedure day, there was a sore-throat which had resolved by the day-7 visit. There was no further complaint and parents were relieved of anxiety.

DISCUSSION

Young children accidentally ingest foreign bodies. In many instances, this goes unrecognized or unreported until the onset of symptoms, which may be remote from the time of ingestion.¹⁰ About 10–20% cases of ingested foreign body will require non-operative intervention and 1%, or less, will require surgery.¹¹ The risk of mortality is relatively very low. Accurate diagnosis and timely management are crucial to the reduction of morbidity in this condition. The prompt intervention alleviates the duration of parents' anxiety and consequent exposure to radiation from serial radiographs performed during conservative management.¹²

Broadly, the indications for intervention in foreign body (FB) ingestion in paediatrics include: FBs in the oesophagus, FBs in stomach that are sharp, pointed or toxic, blunt FBs more than 4cm in length and 2cm in diameter, presence of non-toxic blunt FBs for 2weeks in the stomach or 1week in the duodenum.¹³ The presence of fever, vomiting, or abdominal pain are indications for immediate surgical evaluation. Preceding this, bi-planar radiographs can identify most true foreign objects including free mediastinal or peritoneal air. However, for conservative management of FBs, the physician's instruction is that of a regular diet while, closely observing the patient's stool for the ingested object. In the absence of symptoms, weekly radiographs are sufficient to follow the progression of small blunt objects not observed to pass spontaneously.^{3,14}

A myriad of objects are ingested by children with specific risks of injury. Disk batteries can cause liquefaction necrosis from caustic substances released, especially, when lodged in the oesophagus; and toy parts or sharp objects risk epithelial injury or perforation. In the index case, a British two-penny coin, made of copper-plated steel, was the foreign body ingested. The potential risk of chemical injury from gastric acid reaction on a solitary coin has not been reported from our search of literature. However, copper intoxication has been reported following ingestion of multiple two-penny British coins.^{15,16}

Flexible endoscopy is useful for diagnosis, removal, and treatment of an underlying pathology. The endoscopic accessories for foreign body retrieval include: rat tooth and *alligator* forceps, polypectomy snare, polyp grasper, Dormier basket, retrieval net, over tubes of oesophageal and gastric lengths, and a foreign body protector hood.¹⁷ The choice of instrument used is influenced by availability and technical artistry of the endoscopist. We used a pair of *alligator* forceps which was able to firmly grasp and retrieve the coin safely.

An open surgical option is indicated in unsuccessful endoscopic intervention or as treatment for the complications of impaction including obstruction or perforation of a hollow viscus. Laparoscopic intervention, has also, been reported.¹⁸ However, in some cases, extraction will require an incision larger than a port site because the objects can be large and irregularly shaped.¹⁹

The practice of flexible endoscopy in children is negligible in Nigeria, partly due to few trained paediatric endoscopists, availability of special equipment for children less than 3years of age and added cost of anaesthesia.²⁰ This is in contradistinction to adult endoscopy which is commonly performed under sedation. Paediatric endoscopy is commonly performed under general anaesthesia even in countries where the service is developed.²¹ There is, therefore, a compelling need for the training in endoscopic techniques which entails basic skills of scope navigation, mucosal inspection, retroflexion, loop reduction and targeting.²² The use of simulation-based training has been advocated, because it has the potential to shorten the learning curve, allow assessment of performance and reduce the likelihood of harm caused to patients by novice endoscopists.²³

CONCLUSION

A prompt endoscopic assessment and intervention in foreign body ingestion reduces the duration of family anxiety. An interventional flexible video oesophagogastroduodenoscopy is efficacious

in the retrieval of ingested foreign body in children, and so, the training of more paediatric endoscopists is highly and urgently desirable.

REFERENCES

1. Cheng W, Tam PK. Foreign-body ingestion in children: Experience with 1265 cases. *J Pediatr Surg* 1999; 34:1472-1476.
2. Eisen GM, Baron TH, Dominitz JA, Faigel DO, Goldstein JL, Johanson JF, Mallery JS, Raddawi HM, Vargo JJ II, Waring JP, Fanelli RD, Wheeler-Harborough J. American Society for Gastrointestinal Endoscopy - Guidelines for the management of ingested foreign bodies. *Gastrointest Endosc* 2002; 55:802-806.
3. Panieri E, Bass DH. The management of ingested foreign bodies in children: a review of 663 cases. *Eur J Emerg Med* 1995; 2:83-87.
4. Lehmann CU, Elitsur Y. Keep the change, doc! Coins in the upper GI tract of children. *W V Med J* 1995; 91:13-15.
5. Kay M, Wyllie R. Pediatric foreign bodies and their management. *Curr Gastroenterol Rep* 2005; 7:212-218.
6. Uyemura MC. Foreign body ingestion in children. *Am Fam Physician* 2005; 72: 287-291.
7. Nwogbo AC, Eke N. Oesophageal foreign bodies in Port Harcourt. *Port Harcourt Medical Journal* 2012; 6:211-214.
8. Ginsberg GG. Management of ingested foreign objects and food bolus impactions. *Gastrointest Endosc* 1995; 41:33-38.
9. Bhatnagar S, Das U M, Chandan G D, Prashanth S T, Gowda L, Shiggaon N. Foreign body ingestion in dental practice. *J Indian Soc Pedod Prev Dent* 2011; 29:336-338.
10. Tsui BCH, Mossey J. Occults liver abscess following clinically unsuspected ingestion of foreign bodies. *Can J Gastroenterol* 1997; 11:445-448.
11. Misra S, Jain V, Ahmad F, Kumar R, Kishore N. Metallic sewing needle ingestion presenting as acute abdomen. *Niger J Clin Pract* 2013; 16: 540-543.
12. Antoniou D, Christopoulos-Geroulanos G. Management of foreign body ingestion and food bolus impaction in children: a retrospective analysis of 675 cases. *Turk J Pediatr* 2011; 53:381-387.
13. Seo JK. Endoscopic management of gastrointestinal foreign bodies in children. *Indian J Pediatr* 1999; 66(1 Suppl):S75-80.
14. Webb WA. Management of foreign bodies of the upper gastrointestinal tract: update. *Gastrointest Endosc* 1995; 41:39-51.
15. Hasan N, Emery D, Baithun SI, Dodd S. Chronic copper intoxication due to ingestion of coins: a report of an unusual case. *Hum Exp Toxicol* 1995; 14:500-502.
16. Yelin G, Taff ML, Sadowski GE. Copper toxicity following massive ingestion of coins. *Amer J Forensic Med Pathol* 1987; 8:78-85.
17. Nelson DB, Bosco JJ, Curtis W, Faigel DO, Kelsey PB, Leung JW, et al. Endoscopic retrieval devices. *Gastrointest Endosc* 1999; 50:932-934.
18. Shukla BK, Khullar R, Sharma A, Soni V, Baijal M, Chowbey P. Laparoscopic retrieval of an unusual foreign body. *J Minim Access Surg* 2014; 4: 210-212.
19. Friedt M, Welsch S. An update on paediatric endoscopy. *Eur J Med Res* 2013; 18:24
20. Ngim OE, Ikobah JM, Ukpabio I, Bassey GE, Ekanem EE. Pediatric Endoscopy in Calabar, an Emerging Trend - Challenges and Prospects: A Report of Two Cases. *IOSR-JDMS* 2014; 13:28-30.
21. Muhammed R, Thomson M, McGrogan P, Beattle RM, Jenkins HR. The provision of paediatric gastrointestinal endoscopy services in the United Kingdom. *Frontline Gastroenterol* 2012; 3:263-266.
22. Vassiliou MC, Dunkin BJ, Marks JM, Fried GM. FLS and FES: Comprehensive models of training and assessment. *Surg Clin North Amer* 2010; 90:535-558.
23. Blackburn SC, Griffin SJ. Role of simulation in training of next generation of endoscopists. *World J Gastrointest Endosc* 2014; 696: 234-239.