



Estimation of Cardiothoracic Ratios in Thoracic Radiographs of the West African Dwarf Goat

UKAHA, R.O..

Department of Veterinary Surgery & Theriogenology, Michael Okpara University of Agriculture, Umudike, Abia State, Nigeria.

Correspondence: ukarock1@yahoo.com +2348061530565

SUMMARY

An enlarged heart almost always indicates the presence of cardiac or pericardial disease. Radiographic assessment is an invaluable and a practical method of evaluating patients with cardiothoracic disease. Cardiac ratios of twelve clinically healthy West African Dwarf Goats (WADGs) were studied. The aim of this research was to estimate reference values for cardiothoracic ratios (CTRs) of normal goats. Cardiac and thoracic diameters were measured in dorsoventral (DV) and ventrodorsal (VD) thoracic radiographs and recorded in centimetres. Means \pm standard errors of means ($M \pm SEM$) cardiothoracic ratios, CTRs, were 0.66 ± 0.02 for DV views and 0.60 ± 0.01 for VD projections. There was significant CTR difference between DV and VD views but the difference between male and female DV CTRs was not significant. CTRs correlated highly and positively with cardiac diameter. For clinical practice, CTRs are easily and objectively applicable in the radiographic evaluation of cardiac sizes.

KEYWORDS: Radiographic measurement, Heart, Thorax, Dorsoventral, Ventrodorsal, Dwarf goats

INTRODUCTION

In veterinary radiology, various cardiac and thoracic indices have been reported for pets and a few other animals. But none of these indices is ever found faultlessly suitable for general clinical and field use as a result of differences in thoracic conformations among animal species and breeds (Lamb and Boswood, 2002; Litster and Buchanan, 2000). For this reason, determination of breed-specific reference parameters for various animals becomes very necessary. CTR is a relationship derived by adding the horizontal distances from the midline to the most lateral aspect of the left heart border and most lateral aspect of the right heart border, and dividing that sum by the maximum horizontal diameter of the thorax, measured from left pleural surface to the right pleural surface (taken at the level of the diaphragmatic apices) in a posteroanterior chest radiograph in humans and DV thoracic projection in animals. Mathematically, $CTR = (d_r + d_l) / w_T$, where d_r and d_l are respectively measured distances of the most rightward and most leftward borders of the cardiac silhouette to the spinal column, and w_T is the maximum transverse width of the thoracic cavity (Baron, 2004; Miller *et al*, 2000).

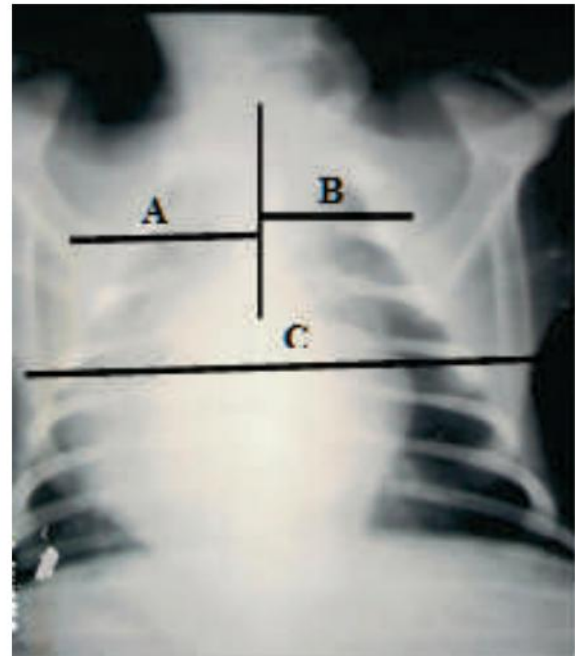
Literature does not only reveal a dearth of diagnostic imaging reports on the caprine species, but also discloses that no radiological research has been published in this field for WADGs. Therefore, the present work was

performed to estimate reference radiographic values for size of the cardiac silhouette of clinically normal WADGs for use by veterinary radiologists, veterinary surgeons, and veterinary clinicians in the imaging of cardiac and thoracic diseases of this breed of goats.

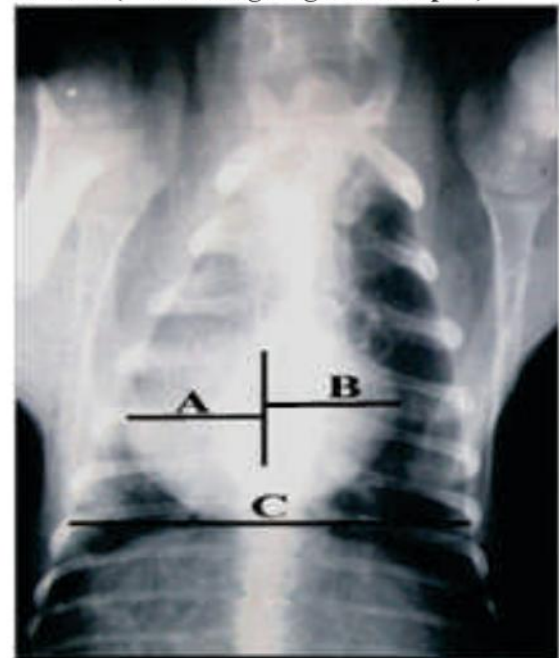
MATERIALS and METHOD

Twelve WADGs (8 females) with body weights 4.8kg to 14kg were kept together for a week to acclimatize. Physical and clinical examinations carried out at the end of the period were normal in all the goats, and so the animals were adjudged healthy and suitable for this work (Struab *et al.*, 2002). Survey DV and VD thoracic projections of each experimental animal were obtained. Cardiac and thoracic diameters were measured on the radiographs in centimeters as follows: (a) sum of the horizontal distances measured from the spine to the most rightward and most leftward cardiac borders was taken as the cardiac diameter (Baron, 2004; Miller *et al.*, 2000). (b) Horizontal width of thorax, from inner surfaces of ribs, measured at the diaphragmatic apices, was taken as the thoracic diameter (Baron, 2004; Miller *et al.*, 2000).

Results of this study were presented as means plus or minus standard error of means (M±SEM). Statistical comparisons of variables were made using Pearson's Product Moment Correlation Coefficient and Student's t-test. Probabilities less than 0.05 were considered significant.



VD View (Heart image is gourd-shaped)



DV View (Heart image is globoid)

Plate 1: Standard Method of Measuring CTR.

$CTR = (A+B)/C.$

Key: A = most rightward distance from the spine; B = most leftward distance from the spine; C = maximum transverse width of thoracic cavity.

RESULTS

Table 1: Comparison of CTRs in DV versus VD Views

S/N	DV Views			VD Views		
	CD	TD	CTR(CD/TD)	CD	TD	CTR(CD/TD)
A	7.5	12.0	0.63	7.8	13.2	0.59
B	7.2	10.9	0.66	7.9	12.8	0.62
C	7.9	11.2	0.71	8.2	12.9	0.64
D	7.4	10.4	0.71	7.6	13.0	0.59
E	7.8	11.4	0.68	6.8	12.0	0.57
F	7.8	12.1	0.65	8.1	14.2	0.57
G	5.2	8.2	0.63	4.5	9.4	0.48
H	7.8	11.5	0.68	8.3	12.6	0.66
I	4.6	8.7	0.53	4.8	7.4	0.65
J	5.5	7.8	0.71	5.4	8.8	0.61
K	10.1	7.1	0.70	7.2	11.1	0.64
L	6.6	9.7	0.68	6.8	10.9	0.62

Mean = 0.66*

Mean = 0.60*

***Difference between mean CTRs significant (P<0.05)**

Key: CD = Cardiac Diameter; TD = Thoracic Diameter

Table II: Sex Difference in DV CTRs

S/N	Females			S/N	Males		
	CD	TD	CTR(CD/TD)		CD	TD	CTR(CD/TD)
A	7.5	12.0	0.63	I	4.6	8.7	0.53
B	7.2	10.9	0.66	J	5.5	7.8	0.71
C	7.9	11.2	0.71	K	7.1	10.1	0.70
D	7.4	10.4	0.71	L	6.6	9.7	0.68
E	7.8	11.4	0.68				
F	7.8	12.1	0.65				
G	5.2	8.2	0.63				
H	7.8	11.5	0.68				

Mean = 0.69*

Mean = 0.66*

***No significant difference in sex mean CTRs (p>0.05)**

DISCUSSION

Several factors should be considered before cardiomegaly is diagnosed. For instance, cardiac silhouette may be enlarged without heart enlargement as observed commonly in obese animals where fat is deposited within the pericardium; infants have larger hearts relative to their body sizes; breed conformation causes

tremendous variation in cardiac size and shape; and dilation and hypertrophy cannot be differentiated by radiography. However, there are certain radiographic signs that seem to correlate well with specific cardiac lesions (Bonagura, 1989; Moon, 2006; Waters, 1979). In the lateral view, right atrial enlargement may cause dorsal bowing of the terminal portion of

trachea, causing the caudal trachea (over the cranial portion of the heart base) to assume a distinct hook shape. The carina remains in its normal location unless there is concomitant left atrial or left ventricular enlargement. Right ventricular enlargement causes increased cranial convexity, resulting in a more vertically directed cranial border if severe; increased sternal contact; elevation of cardiac apex (because of hypertrophy rather than dilation); and elevation of trachea cranial to its bifurcation. In most instances, right ventricular enlargement has little obvious effect on the position of structures at the heart base (Moon, 2006; Root and Bahr, 2002).

In the VD or DV view, the enlarged atrium bulges from 9 to 11 o'clock position on the right cranial border of the heart. Enlargement and rounding of right ventricle cause increased convexity to the right border forming a reversed "D", decreased distance between heart border and thoracic wall, and apex shift to the left (Moon, 2006; Root and Bahr, 2002). Right heart enlargement is usually associated with the following conditions: pulmonic stenosis, heartworm disease, tricuspid insufficiency, ventricular septal defect, cardiomyopathy, and chronic pulmonary disease (Moon, 2006).

The normal left atrium is situated immediately ventral to, and roughly between, the left and right main stem bronchi. Left atrial enlargement causes dorsal deviation of the left main stem bronchus as viewed in the lateral projection. The left ventricle is relatively thick-walled and for this reason, hypertrophy causes little distortion of its contour in the lateral view; rather it tends to elongate displacing the trachea dorsally (Suter, 1984). The dorsal displacement involves the intra-thoracic portion of the trachea, from the thoracic inlet to the carina, resulting in a decrease in the angle between the trachea and the thoracic vertebrae (Root and Bahr, 2002). Pleural effusion may cause similar tracheal displacement even in the absence of significant cardiomegaly (Snyder *et al.*, 1990). Therefore, when the cardiac silhouette is obscured by the presence of pleural effusion,

the tracheovertebral angle is probably not a reliable sign of left ventricular elongation.

In the VD or DV view, left atrial enlargement causes the left and right main stem bronchi to diverge. The normally straight cardiac border will become more convex with decreased distance to the left thoracic wall; the apex may become rounded, and may shift to the midline. Left heart enlargement may be associated with mitral insufficiency, patent ductus arteriosus, aortic stenosis, cardiomyopathy, and ventricular septal defect. (Moon, 2006; Root and Bahr, 2002)

Decreased heart size relative to thoracic volume is termed microcardia and is due to cachexia (wasting diseases), hypovolaemic states (shock, severe blood loss, dysentery, burn), asthemia, constrictive pericarditis, hypoadrenocorticism, and senile atrophy (Blood and Studdert, 1990; The Merck Veterinary Manual, 1997; Preuter, 1993; Reeder and Bradley, 1993).

Accurate heart assessment, especially in borderline and equivocal situations, can be made by the application of, or comparison with, the normal cardiothoracic indices and scales for the breed concerned (Herring and Ostrum, 2003; Lupow *et al.*, 2002; Gardner *et al.*, 2005; Struab *et al.*, 2002). Other causes of a CTR ratio greater than normal value include cardiac failure and inability to take deep breath due to obesity, pregnancy, pectus excavatum deformity, and ascites (The Merck Veterinary Manual, 1997; Herring and Ostrum, 2003).

In the dog, Schnellig (1995) reported a reference CTR range of 0.60 – 0.65. In flying fox species, Gardner *et al.* (2005) published a CTR value of 0.55. According to Herring and Ostrum (2003) and Baron (2004), normal CTR in man is ≤ 0.50 - ≤ 0.60 . Records of radiographic studies in the goat are very scanty and literature is silent on CTR report in the WADG. However, in this study, we found a significant difference ($p < 0.05$) between mean DV CTR and mean VD CTR (i.e., 0.66 ± 0.02 and 0.60 ± 0.01) but no significant sex DV CTR difference ($p > 0.05$) (Tables I and II). The

difference between DV and VD mean CTRs was due to variation in shape of the heart in DV versus VD radiographs. DV heart image was “globoid” but the VD cardiac shadow appeared the normal gourd-shape. This positional change in shape of heart silhouette may be due to the influence of sternopericardial ligament on the cardiac apex. Chibuzo and Sivachelvan (1994) reported that this ligament is short and attaches caprine heart firmly to the sternum. This means that the heart cannot be displaced downwards, by pulmonary pressure when animal is sternally recumbent, but bulges out in response to the pressure. In the dog, heart apex is connected loosely by a long ligament (phrenicopericardial ligament) to the sternal part of the diaphragm, and since the cardiac apex is free, DV positioning results in apical shift towards the diaphragm and retention of normal heart shape (Dyce *et al.*, 1987; Carlisle and Thrall, 1982; Ticer, 1975). But in the goat, the firm cardiac attachment prevents apical displacement so that the heart bulges into globoidness (without distinction between upper and lower cardiac chambers) when the animal is in DV recumbency. CTR correlated positively with cardiac diameter in both sets of radiographs (highly in DV views, but moderately in VD silhouettes).

CTRs of animals are often determined using DV projections of the patient. But in the WADG, the author recommends that VD views be used rather than DV radiographs because, in the DV/VD plane, cardiac silhouette assumes its normal gourd shape only when the animal is dorsally recumbent. In the light of case history, physical, clinical and laboratory findings, CTR is a diagnostic tool for the evaluation of cardiothoracic diseases. Application of CTR is easy and objective. Results of the present work now offer veterinarians a useful radiographic guide for the evaluation and diagnosis of cardiothoracic disease in the WADG, and for monitoring of patients' response to treatment. Determination of cardiothoracic indices and scales in other breeds of goat awaits research.

ACKNOWLEDGEMENT

The author expresses his gratitude to senior colleagues and mentors, Prof R. O. C. Kene and Dr O. E. Gbonko, both of the Department of Veterinary Surgery, University of Nigeria, Nsukka, for their technical assistance.

REFERENCE

- BARON, M.G. (2004): Radiology of the heart. Cecil Textbook of Medicine. Retrieved from <http://www.merckmedicus.com/ppodcs/us/common/cecils> on 12th December, 2006.
- BLOOD, D.C. and STUDDERT, V.P. (1990): *Bailliere's Comprehensive Veterinary Dictionary*: Bailliere Tindall, London.
- BONAGURA, J.D. (1989): Congenital heart disease. In Ettinger SJ (ed): *Textbook of Veterinary Internal Medicine Vol. 1, 3rd edn*: WB Saunders Co., Philadelphia.
- CARLISLE, C.H. and THRALL, D.E. (1982): A comparison of normal feline thoracic radiographs made in dorsal versus ventral recumbency. *Vet Radiol* **23**:3
- CHIBUZO, G.A. and SIVACHELVAN, M.N. (1994): *Ruminant Dissection Guide. A Regional Approach in the Goat*. Faculty of Veterinary Medicine Occasional Publication No. 1. University of Maiduguri, Nigeria.
- DYCE, K.M., SACK, W.O. and WENSING, C.J.G. (1987): *Textbook of Veterinary Anatomy*. WB Saunders Co., Philadelphia.
- GARDNER, A., THOMPSON, M.S., HEARD, D.J., FENTENOT, D. and GIBSON, N. (2005): Radiographic evaluation of cardiac size in flying fox species. Retrieved from <http://www.vetmed.ufl.edu> on 20th December, 2006.
- HERRING, W. and OSTRUM, B.J. (2003): The ABCs of heart disease. Retrieved from <http://www.learningradiology.com> on 5th December, 2006.
- LAMB, C.R. and BOSWOOD, A. (2002): Role of survey radiography in diagnosing canine cardiac disease. *Comp Cont Ed Pract Vet* **24**: 316 - 326.
- LITSTER, A. and BUCHANAN, J.W. (2000): Vertebral scale system to measure heart size in

- radiographs of cats. *J Am Vet Med Assoc* **216**: 210-214.
- LUPOW, J.B., SIVAK, S.L., and BOSS, D. (2002): The accuracy of the cardiothoracic ratio as a predictor of cardiac enlargement and dysfunction. Retrieved from <http://www.aemj.org> on 5th December, 2006
- MILLER, J.A., SINGER, A., HINRICHS, C., CONTRACTOR, S. and DODDASHI, S. (2000): Cardiac dimensions derived from computed tomography: Correlation with plain film radiography. *Internet Journal of Radiology ISSN: 1(1)*: 1528 – 8404. Retrieved from <http://www.ispub.com> on 21st December, 2006.
- MOON, M. (2006): Radiographic evaluation of the abnormal heart. Retrieved from <http://www.education.vetmed.vt.edu/curriculum/V M8754/moon.html> on 20th Dec., 2006.
- PREUTER, J.C. (1993): Hypoadrenocorticism (Addison's disease). Retrieved from <http://www.beaconforhealth.org/Addisons-Preuter.html> on 20th December, 2006.
- REEDER, M.M. and BRADLEY, W.G. (1993): *Reeder and Felson's Gamut in Radiology. Comprehensive Lists of Roentgen Differential Diagnoses (3rd edn)*. Spring-Verlag New York Inc., NY.
- ROOT, C.K. and BAHR R.J. (2002): The Heart and Great Vessels: In Thrall DE (ed): *Textbook of Veterinary Diagnostic Radiology, 4th edn*, WB Saunders Co., Philadelphia.
- SCHNELLING, C.G. (1995): Radiology of the Heart. In Miller MS and Tilley LP (eds): *Manual of Canine and Feline Cardiology, 2nd edn*, WB Saunders Co., Philadelphia.
- SNYDER, P.S., SATO, T., and ATKIN, C.E. (1990): The utility of thoracic radiographic measurement for the detection of cardiomegaly in cats with pleural effusion. *Vet Radiol* **31**: 89.
- STRAUB, J., PEES, M. and KRAUTWALD-JUNGHANNS, M.E. (2002): Measurement of the cardiac silhouette in psittacines. *J Am Vet Assoc Jul 1* **221(1)**:76-79.
- SUTER, P.F. (1984): Lesions of the Thoracic Wall, Extra-pleural Diseases. In *Thoracic Radiography, A Text Atlas of Thoracic Disease of the Dog and Cat*. Peter F Suter, Switzerland.
- THE MERCK VETERINARY MANUAL (1997): Abnormalities of cardiovascular system. (8th edn). Merck & Co Inc., NJ, USA.
- THE MERCK VETERINARY MANUAL (1997): Hypoadrenocorticism (Addison's disease). (8th edn). Merck & Co Inc., NJ, USA.
- TICER, JW. (1975): *Radiographic Technique in Small Animal Practice*. WB Saunders Co., Philadelphia.
- WATERS, J.W. (1979): Radiographic signs of pulmonary infiltration. *Comp Cont Ed Pract Vet* **1**:704.