



## Heterotopic Ossification on the Right Atrial Wall of an 11 year old Alsatian - A Case Report

EZEASOR, C.K.<sup>3</sup>, EMIKPE, B.O.<sup>1</sup>, ANTIA, R.E.<sup>1</sup>, TIJANI, M.O.<sup>1</sup>, JAGUN, T.Y.<sup>1</sup>, FARAMADE, I.K.<sup>1</sup> and ADEBIYI, T.<sup>2</sup>

<sup>1</sup>Department of Veterinary Pathology, University of Ibadan, Ibadan. <sup>2</sup>Veterinary Teaching Hospital, University of Ibadan, Ibadan. <sup>3</sup>Department of Veterinary Pathology and Microbiology, University of Nigeria, Nsukka.  
\*Corresponding author: chukwunonso.ezeasor@gmail.com

### INTRODUCTION

Heterotopic ossification (HO) is the formation of mature histologically indistinguishable lamella bone in soft tissues which normally exhibits no properties of ossification. HO does not grow out of bone, is not connected to periosteum and is not formed intra-articularly (Maheswarappa et al., 2004). We report here, the occurrence of a heterotopic bone in the right atrial wall in suspected case of canine leptospirosis.

### Case report

An 11 year old male Alsatian dog was presented to the Veterinary Teaching Hospital of the University of Ibadan (VTH-UI) with a history of anorexia, weakness and exercise intolerance of 5 days duration. On clinical examination, the rectal temperature was normal and lung auscultation revealed a clear lung. Electrocardiographic examination showed a low voltage QRS complex similar to previous electrocardiograms earlier carried out in 2009 and 2010. There was mild pedal oedema of the fore limbs and a few ticks; *Amblyoma species* were present on the body and interdigital spaces. Laboratory results revealed mild hypoproteinaemia (8.5 g/dl), leukocytosis with band neutrophils (85%) and monocytosis (6%). Urinalysis revealed mild proteinuria, isosthenuria and mild phosphate crystalluria. The patient was placed on Furosemide, digoxin and multivitamin therapy. On the third day after presentation, the patient became recumbent and

anorexic and showed a slight increase in rectal temperature (39.5°C). On the fourth day post presentation, the patient was found dead in its kernel. At necropsy, the dog was mildly icteric, dehydrated and showed mild pedal oedema. The lungs were moderately congested. The heart was globose. There were glistening smooth, opaque, red, nodular thickenings on the leaflets of the left atrio-ventricular (mitral) valve. There was a wedge shaped cavitated bony structure (2 cm X 1.5 cm X 1 cm) attached to the right atrial wall, about 0.5 cm to the junction between the cranial vena cava and the right atrium (figure 1.0). The cortical surfaces of the kidneys were rough and the left kidney showed multiple irregularly shaped, coalescing, well demarcated, pale and soft areas of varying sizes containing thick yellow fluid. The cut surface of the left kidney showed multiple ecchymotic haemorrhages involving both the cortex and the medulla. The urinary bladder was distended with turbid yellow urine and its mucosa showed multiple petechial haemorrhages.

Tissue samples were collected, fixed in 10% formalin, routinely processed and stained with hematoxylin and eosin. Microscopically, the bony structure attached to the right atrial wall showed features of a mature bone with osteocytes in lacunae, osteoblasts, bone marrow and abundant unmineralized and calcified osteoid (figure 2.0 and 3.0). The kidneys showed a diffuse tubular degeneration and coagulative necrosis, cortical interstitial

fibrosis, mineralization of tubules, vascular thrombi, multifocal bacteria colonies, multiple abscesses and widespread interstitial purulolymphoplasmacytic cellular infiltration.

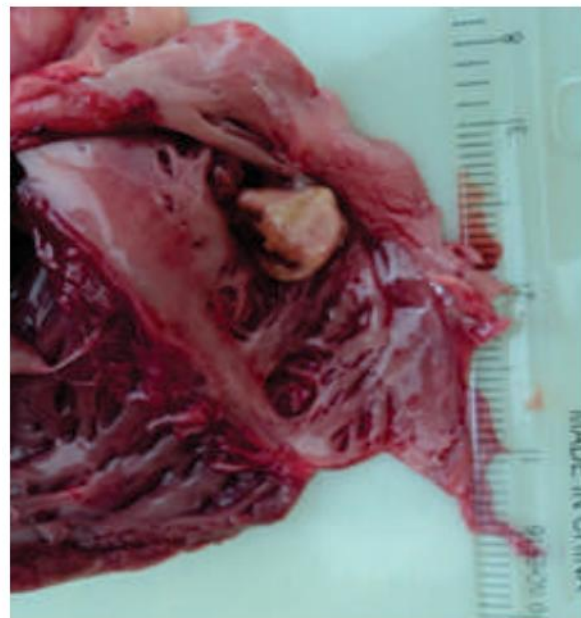
## DISCUSSION

Heterotopic ossification (HO) is the formation of marrow-containing bone outside of the normal skeleton, in soft tissues such as the subcutaneous tissue, skeletal muscle or fibrous tissues (Pape et al., 2004; Kan and Kessler, 2011). Human reports of HO are fairly common but it is rarely reported in domestic animals. In humans, HO following traumatic events, such as total joint replacements (TJR), spinal cord injury (SCI), traumatic brain injury (TBI), fracture, muscular trauma, or war-wounded patients, and in neoplastic conditions have been reported (Kan and Kessler, 2011). Though tissue calcification in the heart has been commonly reported in domestic animals, bone formation is a rare phenomenon. HO with haematopoietic bone marrow in the left atrio-ventricular valves, with systemic circulatory disturbance, has been reported in a 4-year-old crossbred heavy horse (Matsuda et al., 2010). This might be the first report of heterotopic ossification in dogs.

Numerous explanations of the pathogenesis of HO have been proposed by various scientists. The exact trigger mechanism for the formation of HO is unknown but local, systemic, neural, neoplastic and humoral causes have been suggested. A migration of distant mesenchymal cells to the area involved, with subsequent transformation of these cells into osteoblasts, or a transformation of the local mesenchymal cells directly into osteoblasts has been suggested (Buring, 1975). Again, due to the common occurrence of HO in tumours that produce abundant mucin, speculations that mucinous malignant tumours may secrete a substance that stimulates bone formation and that the tumour necrosis may provide a nidus for metaplasia have been made (Ansari et al., 1992; Alper et al., 2000; Naik et al., 2005). Another school of thought suggests that HO originates from

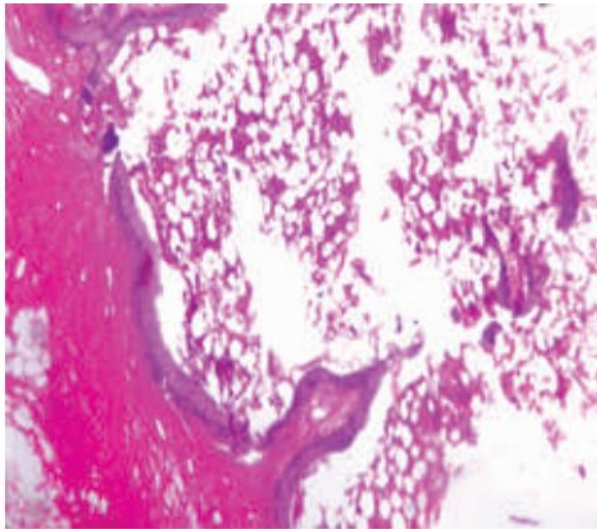
embryonic cells that persist in tissues during development and maturation.

A tentative post mortem disease diagnosis of canine leptospirosis was made in this case. This is based on the results obtained from the clinical pathology and the histopathology, both of which are highly suggestive of canine leptospirosis (Birnbau et al., 1998; Chandrasekaran et al., 2011) which is an endemic canine disease in this environment based on necropsy records in the Department of Veterinary Pathology University of Ibadan. The HO observed in this suspected case of leptospirosis could probably be due to muscle trauma due to turbulence of blood flow or it might have originated from primitive cell which might have persisted in the cardiac muscle of this dog during development.

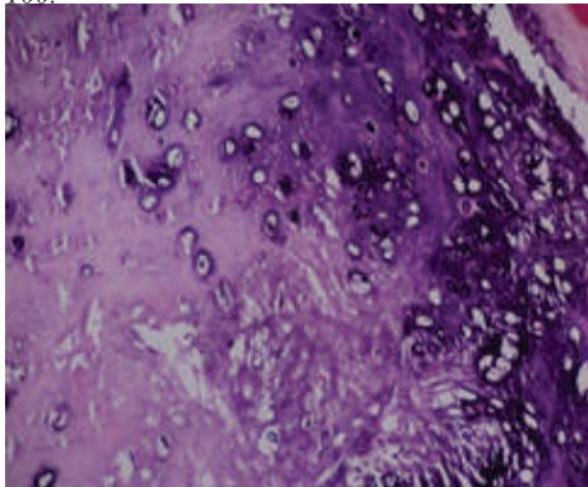


**Figure 1.0:** Gross picture of the heart, showing bony, wedge- shaped structure on the right atrial wall (arrow)

However, heterotopic ossification is a rare occurrence in domestic animals and its significance and pathogenesis especially as observed in the suspected case of leptospirosis needs further investigation.



**Figure 2.0:** Histology of the heterotopic bone, showing its attachment to the myocardium (black arrow) and the bone marrow (white arrow). H & E x 100.



**Figure 3.0:** Histology of the lamellar bone showing numerous lacunae, many of which contain osteocytes and abundant osteoid. H&E x 400

## REFERENCES

- ALPER, M., AKYUREK, N., PATIROGLU, T.E., YUKSEL, O. and BELENLI, O. (2000): Heterotopic bone formation in two cases of colon carcinoma. *Scandinavian Journal of Gastroenterology*; **35**: 556-558.
- ANSARI, M.Q., SACHS, I.L., MAX, E. and ALPERT, L.C. (1992): Heterotopic bone formation in rectal carcinoma. Case report and literature review. *Digestive Diseases and Science* **37**: 1627-1629.
- BIRNBAU, M.N., BARR, S.C., CENTER, S.A., SCHERMERHORN, J., RANDOLPH, J.F. and SIMPSON, K.W. (1998): Naturally acquired leptospirosis in 36 dogs: Serologic and clinicopathological features. *Journal of Small Animal Practice*; **39**: 231.
- BURING, K. (1975): On the origin of cells in heterotopic bone formation. *Clinical Orthopaedics and related Research*. Jul-Aug. **110**: 293-301.
- CHANDRASEKARAN, D., PRATHABAN, S., DHANABALAN, P., BALACHANDRAN, C., MURALI, MANOHAR, B. and VENKATARAMAN, K.S. (2011): Pathological changes in canine leptospirosis. *Tamilnadu Journal of Veterinary & Animal Sciences* **7** (3) 180-183.
- KAN, L. and KESSLER, J.A. (2011): Animal Models of Typical Heterotopic Ossification. *Hindawi Publishing Corporation Journal of Biomedicine and Biotechnology* doi:10.1155/2011/309287
- MATSUDA, K., TABATA, S., KAWAMURA, Y., KUROSAWA, T., YOSHIE N. and TANIYAMA, H. (2010). Ectopic ossification with haematopoietic bone marrow in the heart valves of a crossbred heavy horse. *Journal of Comparative Pathology*. **143**(2-3): 213-7.
- MAHESWARAPPA, B.M., NAIR, K.P.S., TALY, A.B., SHANTHI, S. and MURALI, T. (2004): Heterotopic Ossification at Unusual Site in Traumatic Brain Injury. *Indian Journal of Physical Medicine and Rehabilitation* **15**; 34-37.
- NAIK, V.R., JAAFAR, H. and MUTUM, S.S. (2005): Heterotopic ossification in skeletal

muscle metastasis from colonic adenocarcinoma – a case report. *Malaysian Journal of Pathology*. **27**: 119–121.

PAPE, H.C, MARSH, S., MORLEY, J.R., KRETTEK, C. and GIANNOUDIS, P.V.(2004): “Current concepts in the development of heterotopic ossification,” *Journal of Bone and Joint Surgery B*, **86**, no. 783–787.