



## Corneal Histomorphology of the Adult Squirrel (*Epixerus ebii*)

NLEBEDUM, U.C.\*, IKPEGBU, E., NNADOZIE, O. and AGBAKWURU, I.O.

Department of Veterinary Anatomy, College of Veterinary Medicine, Michael Okpara University of Agriculture, Umudike.

\*Corresponding Author: nlebedum.uchenna@mouau.edu.ng, Tel: 08035477424.

### SUMMARY

The cornea is the transparent anterior portion of the fibrous tunic of the globe. It is the most important structure of the ocular surface for the maintenance of vision. The histomorphology of the Squirrel (*E.ebii*) cornea was investigated in this study. The Squirrel cornea consisted of five layers – Anterior epithelium, anterior limiting membrane (Bowman's membrane), substantia propria (stroma), posterior limiting membrane (Descemet's membrane) and posterior epithelium (endothelium). The anterior epithelium was of the non-keratinized stratified squamous type sitting on a vaguely defined PAS positive anterior limiting membrane. The stroma was made up of regularly arranged collagen fibers with fibrocytes found between the lamella. The posterior limiting membrane was present and was PAS positive. The posterior epithelium consisted of a single layer of large squamous cells.

### INTRODUCTION

The cornea is the transparent anterior part of the outer fibrous coat of the globe. The cornea performs three main functions: protection, transmittance of light and refraction of light (James, 2004). It is the most important refractive structure of the ocular surface for the maintenance of vision providing 70-75 % of the refractive power of the eye (Maurice, 1985, Erich and Nadja, 2005; Elnasharty *et al.*, 2009). For protection, the cornea is profusely supplied with exquisitely sensitive nerve fibers (Klyce and Beuerman, 1988). The mammalian cornea is one of the most innervated organs in the body (Marfurt *et al.*, 1989). Whereas there is information on the histology of the cornea of some rodents like rat, mouse and guinea pig (Elnasharty *et al.*, 2009), there is dearth of data from available literature on the histology of this important ocular structure from this species of rodents hence this study. *Epixerus ebii* (Ebian's palm squirrel), found in West and Central Africa in the tropical or subtropical moist lowland forests, is threatened by habitat loss (Thorington and Hoffman, 2005, Grubb, 2008). The information obtained from this study will be of importance to zoologists, wild life conservationists and wild life veterinarians.

### MATERIALS and METHODS

Animals were captured alive in cage-type traps baited with grains and palm fruits. The animals

were from the rainforest in eastern Nigeria. The animals were euthanized with chloroform, the eyes were enucleated and the corneas dissected out immediately. The corneas were fixed in Davidson's fixative for at least 8 hours (Mary, 2002). The corneal samples were passed through graded ethanol, cleared in xylene, impregnated and embedded in paraffin wax. Sections 5 - 6 $\mu$ m thick were obtained with Leitz microtome model 1512. They were stained with haematoxylin and eosin for light microscopic examination (Bancroft and Stevens, 1977). In addition, the PAS technique was employed (Bancroft and Stevens 1977) obtained with Leitz microtome model 1512. They were stained with haematoxylin and eosin for light microscopic examination (Bancroft and Stevens, 1977). Photomicrographs were taken with Motican 2001 camera (Motican UK) attached to Olympus microscope.

## RESULT

The cornea was composed of five layers; the corneal epithelium, the basement membrane of the corneal epithelium (Bowman's membrane), the stroma, the posterior limiting membrane (Descemet's membrane) and the endothelium (Fig1). The corneal epithelium was of the non-keratinized stratified squamous type. It contained 6-8 layers of cells; the basal cells were columnar cells with a flattened base, domed apex and apically located nuclei. Polygonal shaped cells were seen on top of the basal cells. They were 2-3 layers deep. Superficially, flat cells were observed on top of the polygonal cells. These cells were 2 layers deep. The basal cells stained lightly eosinophilic with H&E unlike the polygonal cells and superficial cells that were more strongly stained. The corneal epithelium was PAS positive (Fig. 2). The corneal epithelium was sitting on a slightly PAS positive basement membrane (Bowman's membrane) (Fig2). Underlying the epithelium was a thick stroma made up of collagenous fibers which stained eosinophilic with H&E. The fibers were

arranged in regular layers parallel to each other with fibroblasts (keratocytes) located between the collagen layers (Fig. 3). The collagenous lamellae easily separated during processing, separated during processing (Fig. 1). The stroma made up the bulk of the thickness of the cornea.

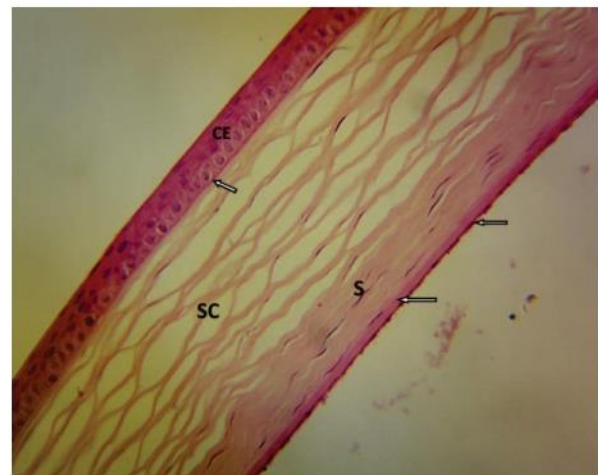
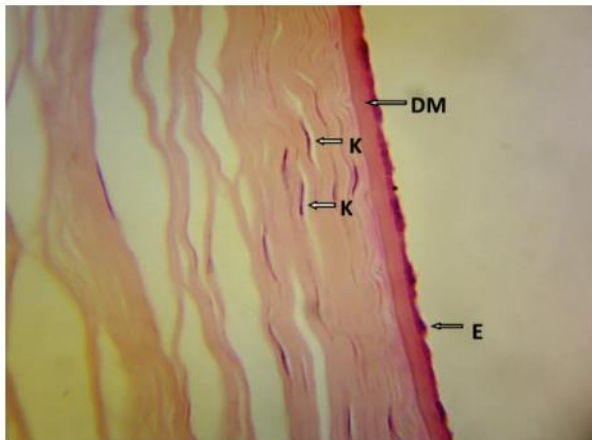


Fig. 1: Photomicrograph of the Cornea showing corneal epithelium CE, Bowman's membrane (white arrow), Stroma S, Descemet's membrane DM and Endothelium E. Note the separation of the collagen lamella in the corneal stroma SC. X400 H&E.

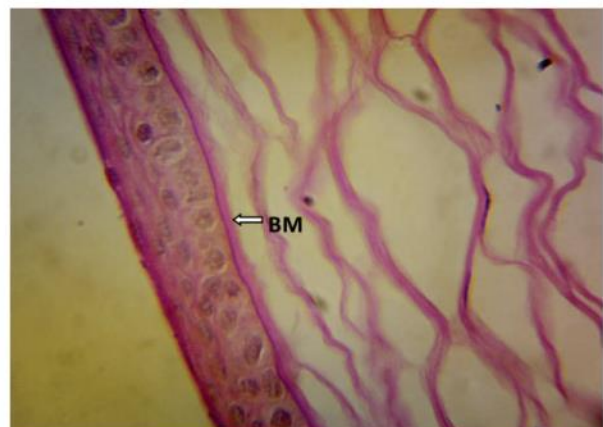

Fig. 2: Photomicrograph of the Cornea showing the PAS positive Bowman's membrane BM. Note the PAS positive reaction of the corneal epithelium. X1000 PAS (counterstained with Harris haematoxylin)





**Fig. 3: Photomicrograph of Cornea showing Keratocytes K, Descemet's membrane DM, Endothelium E. X1000 H&E**

The internal limiting membrane (Descemet's membrane) was PAS positive. It also appeared as a thick amorphous layer when stained with H&E. (Fig. 3)

The innermost layer (the corneal endothelium) was made up of a single layer of flattened to low cuboidal cells with nuclei lying parallel to the internal limiting membrane (Fig. 3). These cells were eosinophilic. These cells were in direct contact with the aqueous humour of the anterior chamber.

## DISCUSSION

In the current study, the corneal epithelium was composed of 6-8 cell layers. This was in agreement with the result reported for another rodent, guinea pig (Elnasharty *et al.*, 2009). Jester *et al.*, (1992) also reported that the rabbit corneal epithelium composed of 6-8 layers. The avascular nature of the cornea is necessary for optimum transparency (David, 2008). The presence of glycogen, demonstrated by the PAS positive granules, in the corneal epithelium is in agreement with previous studies on a large number of animals (Ehlers, 1970). Beurman and Pedroza (1996) also observed same in human corneas. The presence

of glycogen and the avascular nature of the cornea suggests the anaerobic mode of metabolism and energy production through glycolysis (Burkitt *et al.*, 1994). The glycogen metabolism produces water which may be an additional source of fluid to the corneal superficial cells to overcome dryness as this is important for the maintenance of vision (Derbalah, 2001). The epithelial basement membrane was observed in this study. This was concordant with studies on other rodents (Elnasharty *et al.*, 2009). The presence of the basement membrane suggests good regenerative power (basal cell turnover) of the epithelial cells because the removal of the basal lamina have been demonstrated to prolong the reestablishment time of the epithelium, also the epithelium can easily be separated from the stroma until the basement membrane has been completely reformed (Khodadoust *et al.*, 1968; Gellat and Samuelson, 1982).

The stroma consisted of transparent lamellae of fibrous tissue. Between the lamella were fibrocytes, which are called keratocytes. These keratocytes contribute to the formation and maintenance of the stromal lamellae. The precise organization of the corneal stroma permits light to pass through the cornea without scattering (Samuelson, 1999).

The posterior limiting membrane (Descemet's membrane) is PAS positive. It is produced by the posterior endothelium throughout life (Samuelson 1999; David, 2008). The continuous formation of this membrane suggests that with age, its thickness may interfere with vision since it is composed of collagen fibrils.

The corneal endothelium produces the Descemet's membrane and also pumps ions from the stroma into the aqueous humour. This ensures that the stroma remains relatively dehydrated (David, 2008). Its change from low cuboidal to flattened cells with age may suggest that these cells have a limited capacity to replicate. It has been reported that endothelial cells are lost with advancing age

and surrounding cells compensate for the loss of cells (David, 2008). This suggests that with continuous loss of cells, the surrounding cells, with time, may not be able to compensate any longer. This may explain, along with other age related ophthalmic changes, the gradual loss of clarity of vision with advancing age.

In conclusion, this study presents for the first time in available literature, the normal corneal histology of the *Epixerus ebii*. It will fill the knowledge gap and provide baseline data for further investigative research like serving as model for ophthalmic research on effect of aging on vision. This information will also help wild life biologists and veterinarians in recognising ophthalmic pathology in this species.

## REFERENCES

- BANCROFT, J.D. and STEVENS, A. (1977): Theory and practice of histological techniques Churchill Livingstone, New York U.S.A.
- BEUERMAN, R.W and PEDROZA, L. (1996): The Eye In: Textbook of Histology 12<sup>th</sup> edn. W.B Saunders C., Philadelphia 872-882.
- BURKITT, A., YOUNG, B. and HEATH, W. (1994): Special Sense Organs. In Wheatear's Functional Histology (Text atlas) 4<sup>th</sup> edn. Churchill living stone, Longman Group UK. 380-405.
- DAVID, J.M. (2008): Cornea and Sclera. In Slatter's fundamentals of Veterinary Ophthalmology 4<sup>th</sup> edn. 175-2002
- DERBALAH, A.E.M. (2001): Light and electron microscopical studies on the eye of one humped camel (*Camelus Driomedariou*). Thesis for master degree, Fac. Vet. Med., Alexandria Univ.
- EHLERS, N. (1970): Morphology and histochemistry of the corneal epithelium of mammals. Acta Anat. **75**: 161-198
- ELNASHARTY, M., MAREI, H., ABD EL – MOHDY, F. MANSOUR, A. and KIMURA, H. (2009): Histological and immunohistochemical studies of the cornea of some animals species; I. Reappraisal of Cholinergic innervations. Kafrelsheikh, Vet. Med. J., 3<sup>rd</sup> Sci. Congress. 178-204.
- ERICH, K. and NADJA, K. (2005): The role of eye-associated lymphoid tissue in corneal immune protection. J. Anat. **206**: 271–285.
- GELLAT, K.N. and SAMUELSON, D.A. (1982): Recurrent Corneal erosions and epithelial dystrophy in Boxer dog J. AM. Anim. Hosp. Assoc. **18**: 453–460
- GRUBB, P. (2008): *Epixerus ebii*. In: IUCN 2008 IUCN Red list of threatened species.
- JAMES, D.Z. (2004): Corneal development associated with eyelid opening. Int. J. Dev. Biol. **48**:903-911
- JESTER, J.V., PETROLL, W.M., GARANA, R.M.R., LEMP, M.A. and CAVANAGH, H.D. (1992): Comparison of in vivo and ex vivo cellular structure in rabbit eyes detected by tandem microscopy. J Micros. **165**: 169-181.
- KHODADOUST, A.A., SILVERSTEIN, A.M., KENYON, D.R. and DOWLING, J.E. (1968): Adhesion of regeneration corneal epithelium: The role of basement membrane. AM J. Ophthalmol. **65**: 339-348
- KLYCE, S.D. and BEUERMAN, R.W. (1988): Structure and function of Cornea. In: The Cornea (H. E Kaufman, B. A. Barron, M. B. McDonald and S. R Waltman, eds). Churchill livingstone, Newyork 3-54.
- MARFURT, C.F., KINGSLEY, R.E. and ECHTENKAMP, S.E. (1989): Sensory and sympathetic innervation of the mammalian cornea. Invest. Ophthalmol. Vis. Sci., **30**: 461-472.
- MARY, G. (2002): Concept in the routine preparation of eye specimens. Histologic Vol. XXXV **2**: 34-36.
- MAURICE, D.M. (1985): The cornea and the sclera. London Academic Press.
- SAMUELSON, D.A. (1999): Ophthalmic anatomy: In veterinary Ophthalmology 3<sup>rd</sup> edn edited by Kirk N. Gellat 31-150.
- THORINGTON, R.W. JR and HOFFMAN, R.S. (2005): Family Scuridae. In Wilson, D. E; Reeder, D. M. Mammal species of the world: a taxonomic and geographic reference 3<sup>rd</sup> ed. The Johns Hopkins University Press 754-818.