



Clinical Tetanus in Pigs in a Pig Farming Complex, Lagos, Nigeria.

MESEKO, C.A.¹ and OLUWAYELU, D.O.²

¹Viral Research Department, National Veterinary Research Institute, Vom; ²Department of Veterinary Microbiology and Parasitology, University of Ibadan, Ibadan, Nigeria.

*Corresponding Author: +234-803-9183988

SUMMARY

Tetanus is a state of muscular contractions caused by infection of wounds with the bacterium, *Clostridium tetani*. This bacterium produces toxins that affect the nervous system of both humans and animals. Although tetanus is rare in swine, in this report, we examine two clinical cases of tetanus in a pig farming complex in Lagos, Nigeria. The diagnosis of tetanus in pigs was based on the combination of observed clinical signs, history of castration under non-sterile conditions and presence of animal dung in the environment. To prevent future occurrences of tetanus in pigs, we recommend that there should be improved biosecurity measures on pig farms and farmers should employ the services of veterinarians for health-related issues affecting their pigs, especially in handling cases that require surgical intervention.

KEY WORDS: Tetanus, pigs, castration, Nigeria

INTRODUCTION

Tetanus is a state of muscular contraction caused by toxins produced by *Clostridium tetani*, a gram positive, anaerobic, rod-shaped bacterium that affect the nervous system of animals and humans (Wells and Wilkins, 1996). This spore-forming bacterium, first isolated in Germany in 1899 by Kitasato (Davis, 2012), is also found in the large intestine and faeces of many mammals as normal flora from where it is excreted in the soil (Emeribe and Akah, 2011). It enters the body through dirty abrasions or a cut on the body and after an incubation period of 1 to 10 weeks it releases a powerful neurotoxin (CDC, 2011). In suckling pigs, the most common sources of infection are through castration and umbilical wounds. Since tetanus spores are found in the soil and excreta, it poses a major challenge to livestock and public health particularly in poor sanitary conditions (Colosio et al., 2010). In this report, we present two clinical cases of tetanus in a pig farming complex in Lagos, Nigeria.

CASE HISTORY

In April 2011, clinical cases of tetanic convulsion were observed in a pig herd. The piggery had a total of 96 pigs comprising 10 sows, 2 boars, 60 growers and 24 piglets in an intensive production system. The pen is part of a large pig farm complex in an urban area where, due to the intensive system of production, tons of fecal materials are often

generated without adequate means of disposal. Two grower pigs, aged 10 to 12 weeks, showed clinical signs of seizures, generalized spasm of skeletal muscles and knee jerk. One of them adopted a dog-sitting position while the other, at an advanced stage was recumbent with locked jaw, paddling movement of the limbs, and later started stretching to the point of producing bone-breaking sounds. Closer observation of the animals revealed dirty and putrid open wounds on the scrotal sac (Figure 1). On cross-examination, the farmer revealed that the pigs were recently castrated by an itinerant animal health technician using razor blade with little or no pre- and post-operative care. The pen and immediate environment of the piggery were littered with pig dung and biosecurity measures were poor.

DIAGNOSIS

Differential diagnoses of tetanus include food poisoning, chemical or plant toxicosis, gas gangrene, pseudo-membranous colitis, eclampsia and botulism (Blood et al., 1983; Colosio et al., 2010). In this report, tetanus was tentatively diagnosed based on the combination of clinical signs, history of castration done under non-sterile conditions and unhygienic environment. Though soil/dung sample was collected for laboratory diagnosis, isolation and identification of *Clostridium tetani* could not be done as the receiving laboratory did not have the needed reagents and facilities to culture the organism.

MANAGEMENT

The two affected pigs were removed to a cleaner pen with better ventilation and diazepam at a dosage of 10mg/kg body

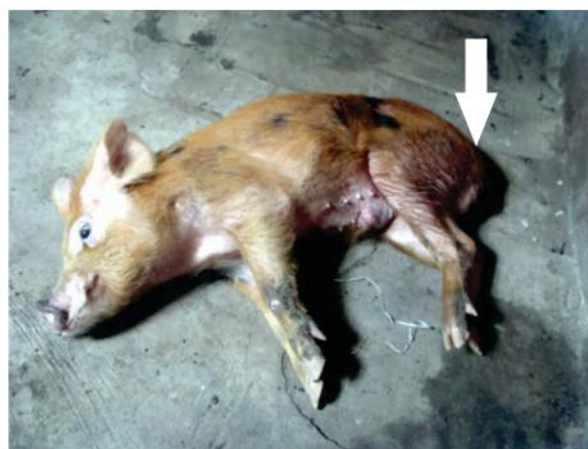


Figure 1: Recumbent pig
(Arrow points to castration wound)

weight was administered intramuscularly for muscle relaxation. The castration wounds were cleaned with 70% alcohol and flushed with hydrogen peroxide to remove bacterial contamination and foreign debris while procaine penicillin was administered intramuscularly as bactericidal agent at a dosage of 300,000 units/kg (Blood et al., 1983). Tetanus antitoxin which could have been administered to neutralize the toxin was unavailable; the farmers were however advised to consult veterinarians in future who are likely to administer tetanus toxoid after castration. Supportive treatment given included increased ventilation to improve breathing of the animals and reduction in noise and other stimuli to reduce hypersensitivity.

DISCUSSION

Although tetanus is reported worldwide, it remains a major health problem in developing countries with higher rates in Africa especially in neonates, and is associated with wounds and poor hygiene (Ashley and Bell, 1969). Tetanus occurs when a wound becomes contaminated with bacteria spores and is activated as vegetative forms which multiply and produce a very powerful toxin affecting the nerves and muscles (CDC, 2011). Since tetanus spores can survive in the environment particularly in soil, dust and animal wastes for a long period (Colosio et al., 2010), the large amount of improperly disposed animal wastes generated

in the pig farm complex in this report is a veritable source of *Clostridium tetani*. This risk of tetanus infection is further heightened by regular unhygienic castration of pigs by itinerant animal health technicians in the farm complex. Piglets may be castrated by farmers when they are about 1-3 weeks of age to control breeding (FVE, 2001). In these cases, the two pigs involved were castrated at 10-12 weeks which makes healing less effective thereby exposing the animals to *Clostridium* organism through open wounds in a dirty environment.

Tetanus diagnosis was made by observing the clinical presentations in combination with history of recent injury to the skin (Blood et al., 1983). Full-blown tetanus can seldom be confused with other diseases because of its distinct clinical signs. Other



Figure 2: Pig in dog-sitting position with arched back

indicators of tetanus include no or incomplete tetanus immunizations, fever, progressive muscle spasms that occur at or near a recent skin injury that is contaminated with dirt (Afshar et al., 2011). Almost all of these signs were observed in the two cases presented. Laboratory tests for *Clostridium* identification which could not be carried out in this case are rarely used for tetanus diagnosis although some reference laboratories can determine if the animal has serum antitoxin levels that are protective, and thus a positive antitoxin test

suggests that the diagnosis of tetanus is unlikely (Colosio et al., 2010). Moreover, Hagan et al. (1988) noted that the signs of tetanus are so characteristic that laboratory examination of specimens is rarely performed. Therefore, the classical clinical signs of stiff-legged gait, opisthotonus, “dog-sitting” posture, exhibition of seizure-like activity and paddling of all four limbs (Figures 1 and 2) in combination with the presence of castration wound was sufficient to tentatively diagnose these cases as tetanus (Blood et al., 1983). The observed muscle spasms were so vigorous to the extent that they caused joint dislocation and bone-breaking sounds captured in real-time.

Among domestic animals, horses are the most susceptible to tetanus (Blood et al., 1983). Although reports of tetanus in pigs are few (Emeribe and Akah, 2011), high incidence may occur in young pigs following castration (Ponsuksili et al., 2008). This underlines the importance of reporting these cases so as to guide veterinarians and pig farmers on what to anticipate in intensive production systems as was encountered in this farming complex. In this report, the two pigs died by the third day despite the treatment given because the cases had advanced beyond remedy. However, in order to prevent future occurrence of tetanus, farmers were advised to secure the services of veterinarians on health-related issues affecting their pigs especially when castration and other surgical interventions are required. This is because, according to the EU Directive 63/630/EEC (FVE, 2001), in pigs older than 3 weeks, surgical castration should only be carried out under anaesthesia and hence by or under the supervision of a veterinary surgeon. There is an urgent need to enact and enforce similar regulation in Nigeria to reduce incidences of tetanus in animals and promote better animal care and welfare.

REFERENCES

- AFSHAR, M., RAJU, M., ANSELL, D. and BLECK, T.P. (2011). Narrative review: tetanus - a health threat after natural disasters in developing countries. *Ann Intern Med.*, 154 (5): 329-335.
- ASHLEY, M.J. and BELL, J.S. (1969). Tetanus in Ontario: a review of the epidemiological and clinical features of 102 cases occurring in the 10-year period 1958-1967. *Canad. Med. Ass. J.*, 100: 798-806.
- BLOOD, D.C., RADOSTITS, O.M. and HENDERSON, J.A. (1983). *Veterinary Medicine: a textbook of the Diseases of Cattle, Sheep, Pigs, Goats and Horses*. 6th edition 1983. Baillere Tindall, East Sussex, United Kingdom. pp. 243,379,536 and 813.
- CENTERS FOR DISEASE CONTROL AND PREVENTION. Tetanus surveillance - United States, 2001-2008. (2011). *Morb. Mortal. Wkly. Rep.* 60 (12): 365-369.
- COLOSIO, C., SOMARUGA, C., VELLERE, F., NERI, L., RABOZZI, G., ROMANÓ, L., TABIBI, R., BRAMBILLA, G., BACCALINI, R., D'ERIL, G.V., ZANETTI, A. and COLOMBI, A. (2010). Biological risk prevention in agriculture and animal breeding: immunization strategies. *G Ital Med Lav Ergon.* 32 (4): 302-305.
- DAVIS, C.P. (2012). Tetanus overview. *E-medicinehealth*. http://www.emedicinehealth.com/tetanus/article_em.htm (accessed 24 November, 2012).
- EMERIBE, V.C. and AKAH, L.U. (2011). Neonatal tetanus in African children: causes, symptoms, predisposing factors, prevention and control. *Arts Social Sciences J.* 23: 1-4 <http://astonjournals.com/assj1>.
- FEDERATION OF VETERINARIANS OF EUROPE (2001). EU Directive 91/630/EEC: Laying down minimum standards for the protection of pigs. Report 01/083 Rue Defacqz, 1 B – 1000 Brussels - www.fve.org (accessed 29 August, 2011).
- HAGAN, W.A., BRUNER, D.W. and TIMONEY, J.F. (1988). Hagan and Bruner's. *Microbiology and Infectious Diseases of Domestic Animals*. 8th Ed. Cornell University Press, pp. 951.
- PONSUKSILI, S., MURANI, E. and WIMMERS, K. (2008). Porcine genome-wide gene expression in response to tetanus toxoid vaccine. *Dev. Biol.* 132: 185-195.
- WELLS, C.L. and WILKINS, T.D. (1996). *Clostridia: Spore-forming Anaerobic Bacilli*. In: *Medical Microbiology*. 4th Ed., Baron, S. (ed). University of Texas Medical Branch, Galveston, Texas. Chapter 18.