



## Fixation of Antero-dorsal Coxofemoral Luxation Using Intra-articular Kirschner Wire Pinning in a Cruciate Fashion and Joint Capsulorhaphy: Review of Three Cases

AJADI, R. A.<sup>1</sup>, OJBLENU, F. E.<sup>2</sup>, MAKINDE, A. F. M.<sup>3</sup>, ADEBAYO, O. O.<sup>3</sup> and AKINTUNDE, O. G.

<sup>1</sup>Department of Veterinary Medicine and Surgery, Federal University of Agriculture, Abeokuta, Ogun State; <sup>2</sup>Department of Orthopaedic and Trauma Surgery, Federal Medical Centre, Abeokuta, Ogun State; <sup>3</sup>Veterinary Teaching Hospital, Federal University of Agriculture, Abeokuta, Ogun State. Corresponding Author: ade\_vsr@hotmail.com

### INTRODUCTION

Although the hip is a typical ball-and-socket joint, it is not well protected against luxation. There are no collateral ligaments and the major stabilizing structures of the joint are the joint capsule, the round ligament, the muscles attached to the proximal end of the femur and the hydrostatic force exerted by the viscosity of the synovial fluid (Piermattei *et al.*, 2006). Stability of the hip joint is further increased by the muscles that attach the proximal femur to the pelvis.

The coxo-femoral joint is the most commonly luxated joint in the dog comprising of 90 percent of all joint luxation (Whitelock, 2010). It is generally the result of blunt external trauma with the resultant tearing of the joint capsule and the rupture of the round ligament of the femoral head (Adamiak, 2012). Most cases of coxo-femoral luxations occur in the cranio-dorsal direction due to the strong pull of the gluteal and iliopsoas muscles (Holsworth and DeCamp, 2003). Cranio-dorsal luxations occur when the hind quarters are driven ventrally towards the ground with the leg extended and the foot weight bearing (Budsberg, 1999). The pelvis is forced ventrally and the knee and hip flexed. At some stage, before the pelvis hits the ground, the knee makes contact with the ground and as the pelvis moves

ventrally the hip begins to rotate externally. If the force is of sufficient magnitude the teres ligament and the joint capsule rupture and the tension in the gluteal muscles results in luxation of the femoral head in a cranio-dorsal direction (Trostel *et al.*, 2000). Cranio-dorsal luxation accounts for about 78 percent of all cases of coxo-femoral luxations in dogs (Trostel *et al.*, 2000).

Treatment of coxo-femoral luxation is aimed at restoring joint alignment and stability, allows articular cartilage surfaces to heal and supports the joint soft tissue structure while healing process is on (Bruce *et al.*, 2002; Schwartz, 2008). Traditional treatment options involved open or closed reduction, joint immobilization, and exercise restriction for a minimum of two week (Whitelock, 2010). Surgical methods for the management of coxo-femoral luxation in dogs include prosthetic capsule repair, joint capsule imbrication, transposition of greater trochanter, prosthetic of *ligamentum teres*, trans-articular external skeletal fixation, De-Vita pinning, femoral head osteotomy, triple pelvic osteotomy and total hip replacement (Haburjak *et al.*, 2001; Cetinkaya and Olcay, 2010; Venturini *et al.*, 2010; Liska, 2010). Most of the techniques are associated with complications such as pin breakage or

migrations, sciatic nerve or rectum injury, necrosis of the femoral head and neck, fistula formation and damage of the joint articular cartilage (Adamiak, 2012). This report presents three cases of coxo-femoral luxations in dogs managed with a combination of Kirschner wire and joint capsulorhaphy.

**KEY WORDS:** Coxo-femoral luxation, intra-articular pinning, Kirschner wire, Capsulorhaphy, Dogs.

### **CASE HISTORIES**

#### **Case one:**

An eight week old female bull mastiff puppy from a litter of four was presented with complaint of inability to bear weight on the left hind limb and hyperextension of the same limb. The owner reported that the puppy was first observed with the condition about three weeks prior to presentation. However, there was no clear evidence of the puppy having any accident but was suspected to have been slept over by the mother. Clinical examination revealed hyperextension of the left hind limb with failure of flexure of the left stifle and hock joint. The left thigh muscles appeared atrophied and contracted. Extended antero-posterior radiograph of the hip showed cranio-dorsal luxation of the femoral head with moderate rotation of the femoral head (Plate 1). The acetabulum appeared shallow; however there was no evidence of dystrophic changes. Also, there was no evidence of degenerative joint disease in the left stifle.

#### **Case two:**

A six-month-old male Caucasian was presented to the Veterinary Teaching Hospital, Federal University of Agriculture, Abeokuta following one month of inability to bear weight on the right hind limb. Physical examination

revealed asymmetry of the hind limbs with slight shortening of the right leg on full flexion. In addition, there was severe pain on palpation of the right thigh. Radiographic examination revealed antero-dorsal luxation of the right femoral head with possible rupture of the round ligament (Plate 2). However, there were no radiographic signs of dysplastic or osteoarthritic changes on the right and left coxo-femoral joints.

#### **Case three:**

A four month old female Alsatian puppy was presented to the Veterinary Teaching Hospital, Federal University of Agriculture, Abeokuta following automobile accident. Physical examination revealed that the dog was unable to bear weight on the left hind limb with pain on palpation of the left thigh. In addition, the spleen of the dog was moderately enlarged while, paracentesis did not yield any aspirate. Antero-posterior radiograph of the hip revealed transverse fracture of the left femoral head with antero-dorsal luxation of the femur (Plate 3).

#### **Management:**

The dogs were first premedicated with intramuscular injection of either tramadol hydrochloride (3mg/kg) or pentazocine hydrochloride (2mg/kg) followed 30 minutes later with intramuscular injections of atropine sulphate injection (0.03mg/kg) and 2% xylazine hydrochloride (1mg/kg). Thereafter, anaesthesia was induced with intravenous injections of diazepam (0.2mg/kg) and ketamine (10mg/kg) and later maintained with intravenous injection of combination of pentobarbitone (7.5mg/kg) and diazepam (0.1mg/kg). Following premedication, venous access was secured with a size 21 gauge scalp vein needle and the cardiovascular system supported with lactated ringers solution at a rate of

10ml/kg/hr. A skin incision measuring about 10cm was made on the lateral aspect of the hip extending from the pelvic brim to a point 2cm caudal to the major trochanter (cranio-lateral approach). Thereafter, the tensor fascia lata was bluntly dissected to locate the joint capsule. The joint capsule was then incised and the coxo-femoral joint explored. In cases one and two, the femoral head was repositioned and two size 2mm Kirschner wires were drilled from the trochanter through the femoral head into the acetabulum to hold the femoral head in place. Thereafter, the joint was irrigated with saline and all clots or debris removed. The lax joint capsule was reconstructed to make it more tightened and the joint capsule sutured with size 2 chromic catgut using a simple interrupted suture pattern. Thereafter, the muscles were closed in layers using simple continuous suture pattern, while the skin was closed with a simple interrupted suture pattern of size 1 nylon. In case two, a second surgery aimed at relieving the muscle contracture was performed by releasing the tensor fascia lata muscle. In case three, mineralized joint soft tissue were removed with a periosteal elevator and the fractured end cleared of all soft tissues. Thereafter, the femoral fracture was reduced and two Kirschner wires were drilled from the trochanter through the fracture into the acetabulum in a cruciate fashion to fix both the fracture and the luxated femur. The joint capsule was then sutured with size 0 chromic catgut and the muscle layer closed as previously described above.

Intramuscular injections of tramadol hydrochloride (4mg/kg) was administered for five days for pain relief while, Penicillin/Streptomycin injection was administered for seven days. Post reduction radiographs were obtained the day after surgery to check for appropriate reduction and intramedullary pin

placement (Plate 4 and 5). The dogs were placed on exercise restriction for four weeks, while skin sutures were removed after 10 days and the Kirschner wire removed after 6 weeks. The dog in case two slipped again four weeks following surgery resulting in breakage of one of the Kirschner wire and subsequent migration of the of the distal portion of the pin into the pelvic cavity (Plate 6) thus necessitating a second surgery to retrieve the Kirschner wire and repair the joint capsule. In all the cases outcome of the surgery was good.

### **DISCUSSION**

Significant complication occurred only in one dog where the Kirschner wire broke four weeks following surgery with the intra-pelvic portion migrating cranially into the abdominal cavity, thus requiring another surgery. However, this complication was not entirely due to pin failure as the handler reported the possibility of a second fall two days before re-presentation. During the second surgery, the joint capsule was reconstructed following unsuccessful attempt at pin retrieval and the dog was placed in cage rest. Localized tissue swelling and discharge over the pin was noted in two dogs. There was sufficient reduction of the hip joint in all the dogs. The overall outcome was excellent in two cases but considered poor in one dog that had pin breakage. The pin that broke was of sufficient diameter for the size of the dog and further trauma was probably responsible for it. Intermittent stiffness or lameness up to three times a week was present in the three dogs from six months postoperatively indicating a significant degree of post-traumatic osteoarthritis but not as high an incidence of postoperative stiffness/lameness as occurred in a study of traumatic elbow luxation in dogs, in which 80 per cent of cases had some

stiffness/lameness postoperatively (McCartney *et al.*, 2010).

Coxo-femoral joint is the most commonly luxated joint in dogs and cats, accounting for up to 50 percent of all joint luxations. It most commonly occurs in adult dogs, although skeletally immatured animals may be affected (Demko *et al.*, 2006). The three dogs in this report were skeletally immatured with the age ranging from two months to six months. Vehicular trauma has been reported to account for 70-90 percent of cases of coxo-femoral luxations in dogs, while injury from fall accounts for about 20 percent of the cases (McCartney *et al.*, 2011). In this report, coxo-femoral luxation was associated with automobile accident in only one of the dogs while the exact cause was not known in the other two dogs but was suspected to be related to fall in one case and the bitch suspected to have slept on the other dog.

There are several surgical approaches to the coxo-femoral joint in dogs and cats. The cranial approach was first described by Smith-Petersen and utilizes the inter-nervous plane that is present between the Sartorius (femoral nerve) and tensor fascia lata (superior gluteal nerve) superficially and also between the rectus femoris (femoral nerve) and gluteus medius (superior gluteal nerve) more deeply (Kelmanovich *et al.*, 2003). This approach allows good access to the hip joint, although femoral exposure is not as good as in other approaches. The cranio-lateral approach was first described by Watson-Jones and provides good exposure to the hip without trochanteric osteotomy (Off and Matis, 2010; McCartney *et al.*, 2011). The approach utilizes the intermuscular plane between the tensor fascia lata and the gluteus medius. Others include direct lateral or trans-gluteal, lateral trans-trochanteric and caudo-lateral approaches

(Kelmanovich *et al.*, 2003). A cranio-lateral approach was used for the three cases because it is less painful and allows for good access to the hip joint. In addition, bleeding was minimal with this approach.

Open reduction of coxo-femoral luxation is indicated when luxation had occurred for more than 72 hours before repair or when fracture of the articular bone is involved. One of the dogs had fracture of the femoral head in addition to the femoral luxation, while the excessive weight of one of the dogs made us to prefer an open approach for the management. The third dog had a chronic luxation complicated with contracture of the stifle joint. The open method allowed for application of Kirschner wire and the repair of the torn joint capsule.

Luxated coxo-femoral joint is often immobilized using intra-articular techniques such as toggle pin variations (Demko *et al.*, 2006) or trans-articular pinning (McCartney *et al.*, 2011), whereas the extra-articular techniques include de Vita pinning (Venturini *et al.*, 2010). A modified trans-articular pinning was used in the three dogs involving use of two Kirschner wires to provide adequate rigidity and prevent pin breakage. Kirschner wire was preferred over Steinman's pin because it is more flexible with less risk of complications such as osteonecrosis and osteoarthritis in the skeletally immatured dogs. A capsulorrhaphy was performed to provide further support and immobilization for the reduced hip joint and thus improve the outcome.

Finally, the number of cases that we have used this technique for is small to accurately evaluate the effectiveness of the technique or compare it with other techniques. To the authors' observation,

this technique appeared to improve overall limb functions compared with excision arthroplasty which is commonly done. The only major complication observed with this technique as reported in other works is breakage of the Kirschner wire with consequent migration. This however, can be eliminated by correct selection of Kirschner wire size and increased period of cage rest for the animal. More cases in which this method was used will be needed to allow for proper evaluation of this technique. In addition comparison between the efficacy and complications of this technique and commonly used excision arthroplasty will be required to see if this technique has any advantage over the

Plate 1: Antero-posterior radiograph of the hip of an eight-week-old bull mastiff puppy with antero-dorsal luxation of left coxo-femoral joint

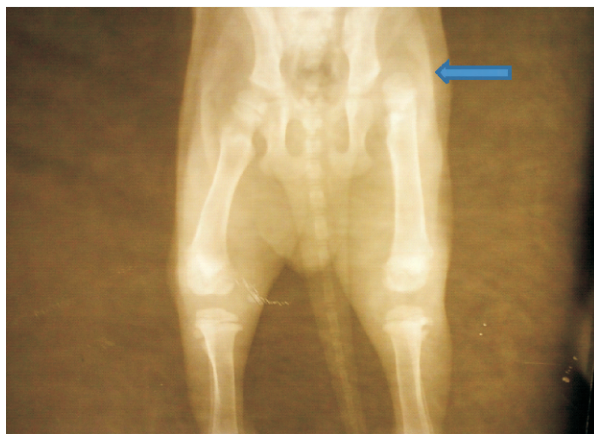

Plate 2: Antero-posterior radiograph of the hip of a six-month-old Caucasian with antero-dorsal luxation of the right femur

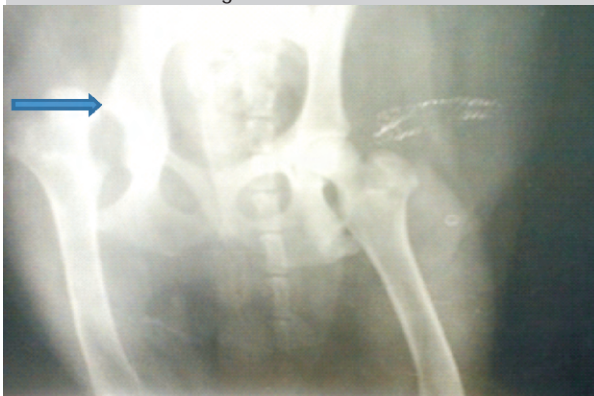

Plate 3: Antero-posterior radiograph of the hip of a four-month-old Alsatian with capital physeal fracture of the femoral head and moderate coxofemoral luxation

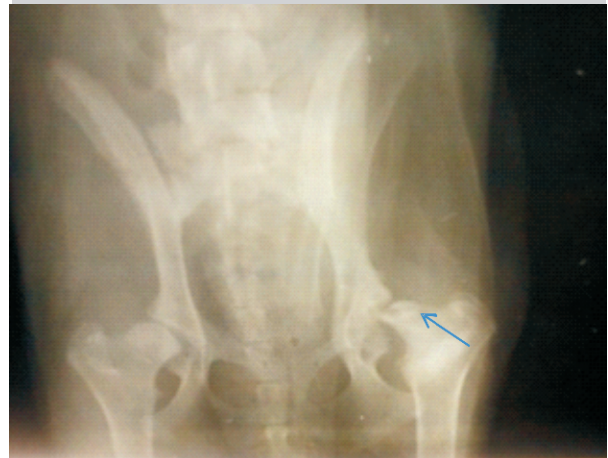


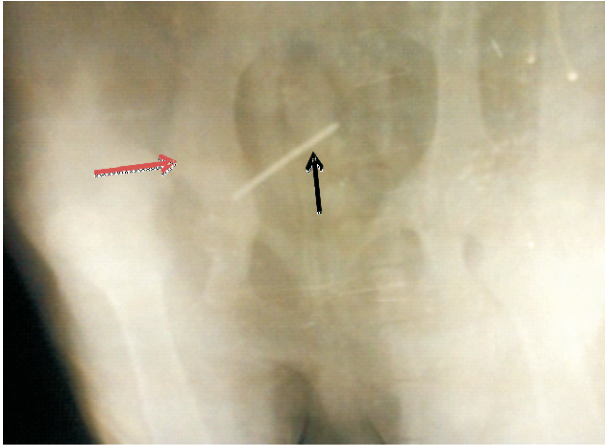
Plate 4: Post-reduction radiograph of an eight-week-old bull mastiff showing adequate reduction of the femoral head. Note the two Kirschner wire applied.

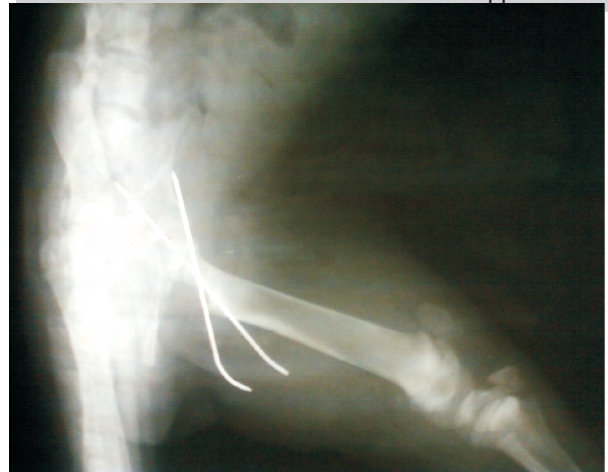

Plate 4: Post-reduction radiograph of an eight-week-old bull mastiff showing adequate reduction of the femoral head. Note the two Kirschner wire applied.

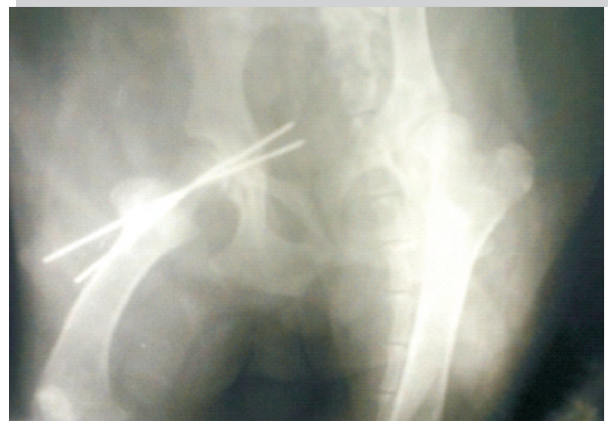

Plate 6: Radiograph of a six month old Caucasian with a broken intra-articular Kirschner wire with pin migration (Black arrow) into the pelvic cavity. Note the sub-luxation of the coxofemoral joint (Red arrow)



## REFERENCES

- ADAMIAK, Z. (2012). Treatment of bilateral hip luxation in dogs with the Shani-Johnston-Shahar technique: Case report. *Revue. Med. Vet.*, 163(2): 76-78.
- BRUCE, W. J., FRAME, K., BURBRIDGE, H. M., THOMPSON, K. G. and FIRTH, E. C. (2002). A comparison of the effects of joint immobilization, twice daily passive motion, and voluntary motion on articular cartilage healing in sheep. *Vet. Comp. Orthop. Traumatol.* 15: 23-29.
- BUDSBERG, S. C. (1999). Joint luxations: Principles of treatment. Proceedings of the 9<sup>th</sup> Annual American College of Veterinary Surgeon Symposium, USA. 302-305.
- CETINKAYA, M. A. and OLCAY, B. (2010). Modified Knowles toggle pin technique with nylon monofilament suture material for treatment of two caudo-ventral hip luxation cases. *Vet. Comp. Ortho. Traumatol.*, 23: 114-118.
- DEMKO, J. L., SIDAWAY, B. K., THIEMAN, K. M., FOX, D. B., BOYLE, C. R. and MCLAUGHLIN, R. M. (2006) Toggle rod stabilization for treatment of hip joint luxation in dogs: 62 cases (2000-2005). *J. Am. Vet. Med. Assoc.* 229, 984-989.
- HABURJAK, J. J., LENEHAN, T. M., HARARI, J., GUREVITCH, R., RIVERS B., TARVIN, G.B. and CONSTABLE, P. D. (2001). Treatment of traumatic coxo-femoral luxation with triple pelvic osteotomy in 19 dogs (1987- 1999). *Vet. Comp. Ortho. Traumatol.*, 14: 69-77.
- HOLSWORTH, I. G. and DECAMP, C. E. (2003). Coxofemoral luxation. In Slatter DH, ed., *Textbook of Small Animal Surgery*. 3<sup>rd</sup> ed. Philadelphia: WB Saunders: 2002-2008.
- KELMANOVICH, D., PARKS, L. M., SINHA, R. and MACAULY, W. (2003). Surgical Approaches to total hip arthroplasty. *J. Sth. Ortho. Assoc.* 12(2):90-94.
- LISKA, W. D. (2010). Micro total hip replacement for dogs and cats: surgical techniques and outcomes. *Vet. Surg.*, 39: 797-810.
- MCCARTNEY, W. T., KISS, K. and MCGOVERN, F. (2010). Surgical stabilization as the primary treatment for traumatic luxation of the elbow joint in 10 dogs. *Int.J. Appl. Res. Vet. Med.* 8: 97-100.
- MC CARTNEY, W. T., KISS, K. and MCGOVERN, F. (2011). Treatment of 70 dogs with traumatic hip luxation using a modified trans-articular pinning technique. *Vet. Rec.*, 168: 355-357.
- OFF, W., MATIS, U. (2010). Excision arthroplasty of the hip joint in dogs and cats: Clinical, radiographic, and gait analysis findings from the Department of Surgery, Veterinary Faculty of the Ludwig-Maximilians-University of Munich, Germany. *Vet. Comp. Orthop. Traumatol.*, 23: 297-

- 305.
- PIERMATTEI, D. L., FLO, G. L. and DECAMP, C. E. (2006). The hip joint. In: Brinker, Piermattei and Flo's Handbook of Small Animal Orthopaedics and Fracture Repair. 4<sup>th</sup> ed. St. Louis: Saunders Elsevier: 461-511.
- SCHWARTZ, Z. (2008). Non-rigid external fixation of the elbow, coxo-femoral, and tarsal joints in dogs. *Compendium*: 648-653.
- TROSTEL, C. D, PECK, J. N. and DEHAAN, J. J. (2000). Spontaneous coxo-femoral luxation in four dogs. *J. Am. Anim. Hosp. Assoc.*, 36(3): 268-276.
- VENTURINI, A., PINNA, S. and TAMBURRO, R. (2010). Stabilization of traumatic luxation with extra-capsular suture from the greater trochanter to the origin of the rectus femoris. *Vet. Comp. Ortho. Traumatol.*, 23: 182- 185.
- WHITELOCK, R. (2010). Traumatic luxation in the dog. Proceedings of the 3<sup>rd</sup> World Veterinary Orthopaedic Congress, ESVOT-VOS, Italy: 186-187.