



'Managing a Necrotic Limb of African Dwarf Crocodile (*OSTEOLAEMUS TETRASPIS*) in Ibadan Zoological Garden: A Case Report'

EYAREFE, O. D.¹, OGUNTOYE, C. O. *¹ and OMOBOWALE, T. O.²

¹Department of Veterinary Surgery and Reproduction, University of Ibadan, Ibadan, Nigeria. ²Department of Veterinary Medicine, University of Ibadan, Ibadan, Nigeria. *Correspondence: wumcel06@gmail.com, Tel: +2348055063671.

INTRODUCTION

Crocodylian species, are the largest, longest living reptiles with longevity ranging between 50 to over 100 years (Loser, 2000; Buffetaut and Upton, 1997; Evans, 1996). Fewer than 25 extant crocodile species are in existence worldwide with conservation status ranging from threatened to critically endangered (Lloyd, 1999). African Dwarf Crocodile (ADC) is one of the endangered crocodile species distributed over 20 African countries and is the smallest of the species with an average length of 6 feet at adulthood. It occupies fresh water ecosystem (Lloyd, 1999).

The gradual extinction of crocodile species is associated with infectious and non-infectious diseases as well as aggressive hunting (Boyer, 1998; Buffetaut and Upton, 1997). A number of crocodile diseases, including neoplasia (Done, 1996), viral (Buffetaut and Upton, 1997; Jacopson, 1989), bacterial (Foggin, 1987) mycotic (Jacopson, 1989) and parasitic (Laddds, 1993) have been reported in literature.

Crocodiles, especially those on free range, may sustain injuries arising from trauma or infections that require aggressive medical and surgical interventions. Foot diseases such as pododermatitis (bumble foot), chronic proliferative lesions and acute inter-digital subcutaneous emphysema often require aggressive medical and surgical interventions (Foggin

et al., 1989; Jacopson, 1989). Traumatic limbs infected with *staphylococcus aureus*, *streptococcus species* including mycotic agents present a fatal sequele.

Crocodiles are very important reptile commanding educational attraction in free range and in captivity. Besides, their conservation status as endangered species demands every effort at management of their surgical conditions. This paper presents a report of a surgical management of a traumatized necrotic hind limb of a captive African dwarf crocodile in the University of Ibadan zoological garden, which to the best of the authors' knowledge is the first report from Nigeria. The need to harness our Veterinary skill at protecting endangered wildlife species, and also expand the Veterinary Medicine curriculum in Nigeria to accommodate the medical and surgical disease conditions of wild life species form the objectives of this report.

KEY WORDS: Crocodile, Trauma, Surgical, Management.

CASE REPORT

A 6.5 kg, female African dwarf crocodile with estimated age of 15 years (age estimation by skeletochronology as described by Leclair, Jr and Castanet,

1987), donated to the University of Ibadan zoological garden, was presented on Friday 30, September, 2011 with a severely traumatized and necrotic right lower limb, just distal to the stifle joint, which prevented the animal from activity. An etiology of hunter's trap was speculated since the crocodile had sustained the injury before it was donated to the zoological garden. The skin and muscles around the tibio-fibula bones of the affected limb had sloughed off, and the tarso-phalangeal bones were disarticulated from the limb (plate 1). Radiograph of the affected limb showed evidence of a healthy stifle and a possibility of amputation at this joint to salvage the thigh (plate 2). Following clinical evaluation the option of amputation was considered.

Surgical procedure: The crocodile was sedated with 5% ketamine (Laborate-India) at a dose rate of 20mg /kg (Lloyd, 1999), and a ring block to desensitize associated nerves at the level of stifle accomplished with lignocaine (Vital Health Care PC Ltd, India) at a dose rate of 3ml/6kg body weight. The wound was debrided and the whole thigh was prepared for aseptic surgery (plate 3). An incision was made at the lateral aspect of the stifle joint and extended proximally and distally to expose the joint. The tibio- fibula bones were disarticulated from the distal femoral condyle at the joint capsule. The wound was thoroughly irrigated with normal saline (Dana pharmaceuticals) and the residual tissues (muscles, fascia and skin) wrapped neatly over the distal femoral condyles and sutured with 2-0 chromic catgut (Agary Pharmaceutical Ltd). The skin was closed with everting suture pattern using size 1 nylon (Agary Pharmaceutical Ltd) and dressed with honey incorporated bandage (plate 4). Enrofloxacin (Concept Pharmaceuticals, Mumbai, India) was administered at a dose

rate of 5mg/kg and given three times 48 hourly as recommended (Lloyd, 2003).

DISCUSSION

Although crocodiles have strong immune system they can still come down with life threatening infections (Lloyd, 1999). Foot injuries are sustained from territorial fights or hunters traps and may be complicated with bacterial and mycotic infections (Jacopson, 1989, Lloyd, 1999) as speculated for this case. The level of limb damage in this case was so severe that conservative treatment was not advisable (plate 1). The choice of mild sedation with ketamine and ring block with lignocaine hydrochloride was necessary in order to forestall anaesthetic complications, since the animal's history of nutrition, etiology and duration of injury was uncertain. The dosage of ketamine used for sedation was within the recommended dosage range for this purpose in crocodiles (Lloyd, 2003). Lignocaine ring block achieved desensitisation of muscular branches of the sciatic nerve, lateral cutaneous sural nerve, common peroneal and tibial nerves (Ellenport, 1977). The everting suture pattern used for skin closure was as suggested by Lloyd (1999), since crocodilian skin naturally inverts causing skin in folding that delay or impedes wound healing. However healing was not as rapid as expected due to anorexia associated malnutrition (Hedlund, 2002) because the zoo handlers were initially unfamiliar with the nutrition of this crocodile since it had just being captured from the wild. It was fed with red meat that it refused until the diet was changed to fresh fish. The crocodile was able to ambulate with the remaining three limbs. Medical and surgical management of wild life poses a challenge to many veterinarians. Management of wild life both captive and free range is gaining

importance globally and veterinarians are often called to attend to such conditions. Unfortunately, the basic anatomy, physiology, medicine and surgery of these species are not emphasized at the Doctor of Veterinary Medicine (DVM) level. Consultancies by the veterinarian do not only end with treatment of disease but also extends to other aspects of wild life management such as housing, breeding and nutrition. Wild life management is a multidisciplinary branch of science and several advancement has taken place in this area in recent years. Veterinary students should be familiarized with the basics of wild life management, medicine and surgery as a means of meeting the global challenge of wild life conservation.



Plate 1: showing the extent and severity of limb injury.

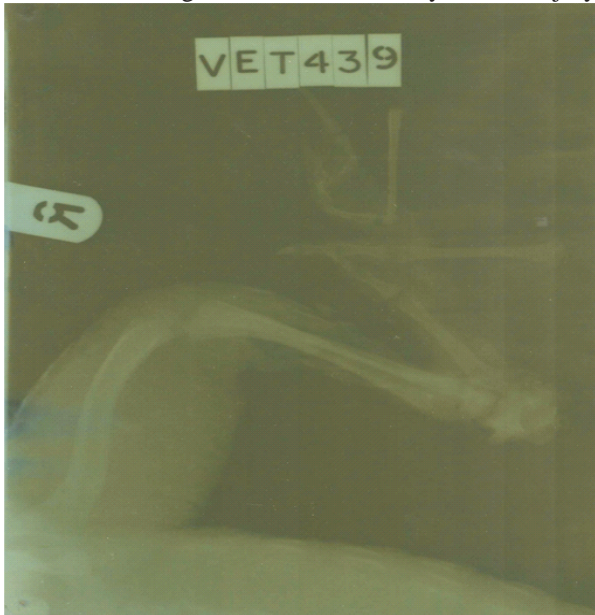

Plate 2: showing radiograph of the affected limb.

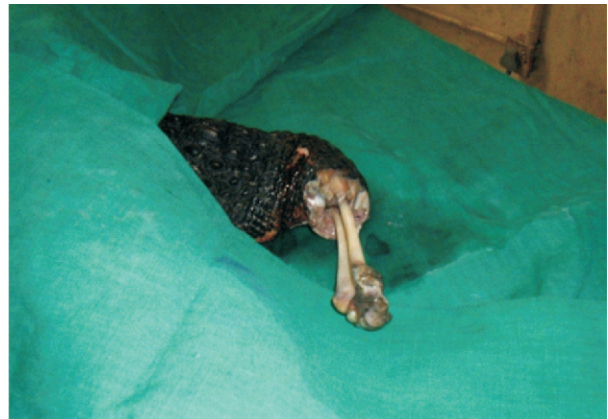


Plate 3: showing aseptic preparation of limb for surgery.

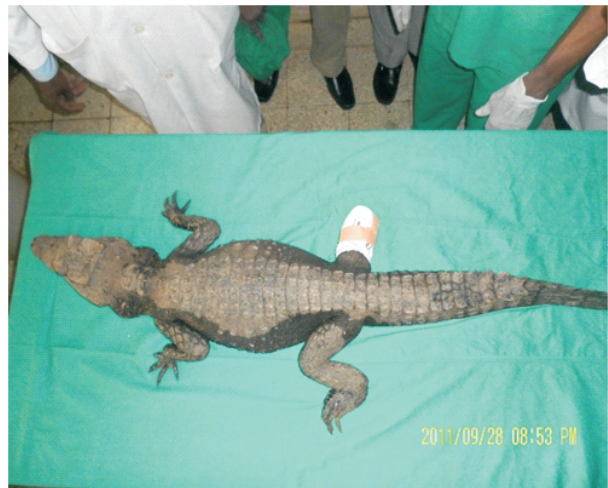

Plate 4: showing crocodile after surgery.

REFERENCES

- BOYER, T. H. (1998): Essentials of Reptiles: A Guide for Practitioners. Lakewood, Colo, AAHA Press, 151-162.
- BUFFETAUT, S. M. and UPTON, S. J. (1979): The evolution of the crocodylians. *Scientific American*, 241: 130-144.
- DONE, L. B. (1996): Neoplasia. Reptile Medicine and Surgery. WB Saunders, Philadelphia: 125-140.
- ELLENPORT, C. R. (1977): The Anatomy of the Domestic Animals. Sissons and Grossman: Getty. Ed. Iowa, WB Saunders, Philadelphia.
- EVANS, H. E. (1996): Reptiles. Introduction and anatomy. Zoo and

- Wild Life Medicine. 2nd Ed W B Saunders, Philadelphia: 109-132.
- FOGGIN, C. M., HUTTON, J., and ROGERS, J. (1989): The effects of temperature on growth and disease in farm Nile crocodile on control farms in Zimbabwe. *A proceeding of the ninth working meeting of the Crocodile Specialist Group* Lae, Papua, New Guinea.
- FOWLER, M. E. and MILLER, R. E. (2003): Zoo and Wild Animal Medicine. 5th Ed. W B Saunders, Philadelphia: 64.
- HEDLUND, C. S. (2002): Surgery of the integumentary system. *Small animal Surgery*. 2nd Ed. Mosby Inc, St Louis, Missouri: 134-137.
- JACOPSON, E. R. (1989): Disease of crocodilian: a review. *A proceeding of the American Association of Zoo Veterinarian*. Greenboro, N.C.: 143-146.
- LADDDDS, P. W. (1987): Parasites and husbandry: some problems and some solutions. *Proceeding of 2nd regional meeting of the crocodile Specialist Group of the species survival commission of IUCN*, Darwin, Northern territory, Australia, Surry Beatty and Sons, 169-176.
- LECLAIR Jr., R and CASTANET, J. A (1987): Skeletochronological assessment of age and growth in the frog *Rana pipiens* Schreber (Amphibia, Anura) from Southwestern Quebec. *Copeia*, 2:361-369.
- LLOYD, M. L. (2003): Crocodilia (Crocodiles, Alligators, Gavials, and Caimans). *Zoo and Wild Animal Medicine: Current Therapy*. 5th Ed. W B Saunders, Philadelphia: 64-66.
- LLOYD, M. L. (1999): Crocodilian Anesthesia. *Zoo and Wild Animal Medicine: Current Therapy*. 4th Ed. W B Saunders, Philadelphia: 205-216.
- LOSER, J. (2000): Krankheiten der Krokodile: Eine literaturstidie. *Inaugural - Dissertation zur Erlangung der tiemedizinischen Doktorwurde der Tierarztlichen Fakultat der Ludwig- Maximilians-Universitat, Munchen, Germany*.