



CASE REPORT

Trichobezoar as Cause of Anorexia in A West African Dwarf Goat.

MUHAMMAD, M.*, BANYIGYI, S. A., TAFARKI, E. A., IGHODALO, E. T., BENSHEK, J., ASALA, O., RIMFA, A., IBU, J. O. and EHIZOBOLO, D.

National Veterinary Research Institute Vom, Plateau State, Nigeria.*Correspondence: E-mail: lawal54@yahoo.com or maryam.muhammad@nvri.gov.ng

INTRODUCTION

Trichobezoars have been reported in man, rabbits, cats, large and small ruminants. The word bezoar is derived from Arabic meaning an antidote for poisons and those found in the goat were considered to have healing properties and were therefore much sought after for medicinal purposes. Goats were first connected with the term bezoar in the 12th century BC after stone-like concretions were found in the stomach of a Syrian goat. Although trichobezoars appear to be an unusual occurrence in the goat with only few cases being reported. In one of such cases in Scotland three angora goats were presented with anorexia and weight loss and a diagnosis of hair balls was made when these were found in the rumen (Baillie and Anzuino, 2006). In another case reported in India the hair balls turned out to be made of human hair as the goat grazed around a shrine where devotees shaved their hair (William *et al.*, 2000).

Trichobezoars can collect or lodge in the rumen and are sometimes a sequela to the habit of bucket fed calves which suckle on each other to satisfy their nursing instinct (Jones *et al.*, 1997). Phytobezoars result from an excess of indigestible roughage (McGavin *et al.*, 2001). Trichobezoars can be quite hazardous since hair cannot be digested. While a number of ailments can produce similar symptoms, the symptoms

produced by bezoars may include distended and tender stomach, pain, bloating, vomiting, weakness and weight loss (Sanders, 2004). Animals predisposed to bezoars include those that have had previous gastric surgery, slowed gastric motility, fasted or animals deprived of food and those with cystic fibrosis (Sanders, 2004). Cats and rabbits are especially prone to hairball formation since they groom themselves by licking their fur, and thereby ingest it. Hairballs are especially dangerous for rabbits because they cannot regurgitate them (Theus *et al.*, 2008). In cats they may be associated with vomiting while phytobezoars and trichophytobezoar are occasionally observed in lambs and calves. In cattle that accumulate hairballs, since they do not vomit, the hair balls are found usually after death and can be found to be quite large. Although uncommon in humans, some hairballs have been reported, often in young girls as a result of trichophagia and pica.

CASE REPORT

The carcass of a male West African Dwarf (WAD) goat was submitted for post mortem with a history that prior to death; the animal had been weak and anorexic. The goat with an adult female was an experimental control confined alone in a pen and had been off-feed and was losing

weight. Grossly at post-mortem, the carcass was found to be severely emaciated and had a left unilateral corneal opacity; the turbinates were congested with diffuse haemorrhages. Both heart chambers were filled with currant jelly blood clot. The rumen was found to contain nine small round solitary masses which on close inspection were found to be hair balls of different sizes ranging from 2-6cm in diameter and covered with a mixture of dark watery sandy fluid (Figures 1 and 2). The abomasum was congested and had the same sandy fluid contents. There was slight enlargement and paleness of the liver and a distension of the gall bladder. The meningeal blood vessels were also congested.

At histopathology the most striking lesions were found in the liver which showed severe hepatic lipidosis in one tissue and severe vascular congestion with few vacuolated and necrotic hepatocytes (Figure 3). The brain, lungs and turbinates were also congested.

DISCUSSION

Post mortem revealed that the rumen was filled with hair balls leaving very little room for food, which could explain the anorexia. The goat was off-feed for few days prior to death. This was not reported until the goat died suddenly. The animal's coat showed no signs of alopecia or any skin irritation. A bezoar is a foreign mass found trapped in the gastro intestinal system. It is a concretion of indigestible plant and/or animal material that remains in the gastrointestinal tract of animals. Over time, they associate with mucous and form masses. They are usually found in the stomach but can be found anywhere between the esophagus and the rectum. There are several varieties of bezoar, made up of organic and inorganic material. They can be classified based on

what they are made of e.g. pharmacobezoars are mostly tablets or semi-liquid masses of drugs. Phytobezoars are composed of non digestible plant material e.g. cellulose and are frequently reported in patients with impaired digestion and decreased gastric motility.

Bezoars have been reported in ruminants but their incidence is lower in goats than in sheep due to the goats feeding habit (Baillie and Anzuino, 2006). The commonest findings of foreign material in Nigeria in both sheep and goat are usually pieces of garbage made of plastic (Igbokwe *et al.*, 2003; Remi-Adewunmi *et al.*, 2004).

In the current case the bezoar was made up of the goat's own hair and as in most cases in other species, probably formed as a result of excessive grooming. Excessive grooming may have had a behavioural cause such as a depraved appetite. A possible reason for depraved appetite could be rabies but histopathology conducted on the brain tissue revealed no signs of this. Depraved appetite or pica has also been associated with phosphorus deficiency (Fraser and Bloom, 1990). Anorexia can also occur due to a range of diseases such as nutritional diseases, gastro intestinal parasites and infectious disease (Fraser and Bloom, 1990). More recently other reasons for the occurrence of trichobezoars have been proposed. These include decreased gastro intestinal motility due to stress factors such as malnutrition, lack of free movement and lack of exercise (Theus *et al.*, 2008). These are all assumed to lead to anorexia, dehydration and the accumulation of hair and ingesta in the stomach. As a result, the stomach contents become aggregated, which prevents adequate gastric emptying (Theus *et al.*, 2008). The animal in the present case had been consigned alone to pen for a prolonged period of time while the experiment lasted and may have experienced stress. A behavioural cause of

over grooming was therefore considered a likely cause of the problem. Although no blood biochemical parameters were assayed in the present case, haematological parameters of sheep with rumen impaction were reported to be within normal range (Abdullahi *et al.*, 1984).

TREATMENT

Bezoars may often be treated with medical therapy, by dissolving the bezoar with enzymes especially in cases of phytobezoars. Traditional remedies include the use of liquid paraffin and the use of enzymes papain and bromelain. The enzymes cannot break down hair so any

success with these is more likely to be from hydration as in the case of pineapple juice, speeding gut motility than breaking down the proteins in the hair ball. However, in severe cases or with very large bezoars, surgery may be required.

CONTROL

Animals should always be supplied with good quality hay and fresh water at all times (Altinli *et al.*, 2004; Malhorta *et al.*, 2008). In cats, grooming of the cat to get rid of loose hair will help keep the cat from swallowing any loose fur.

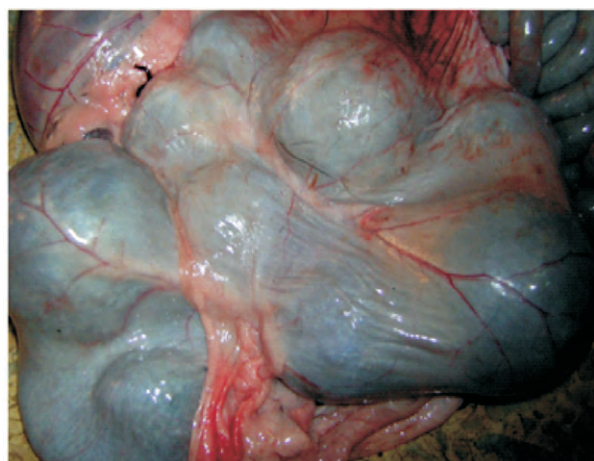


Fig 1. Rumen appearing nodular before incision



Figure 2. Nine hair balls (2-6cm in diameter) *in situ* immediately after incising the rumen

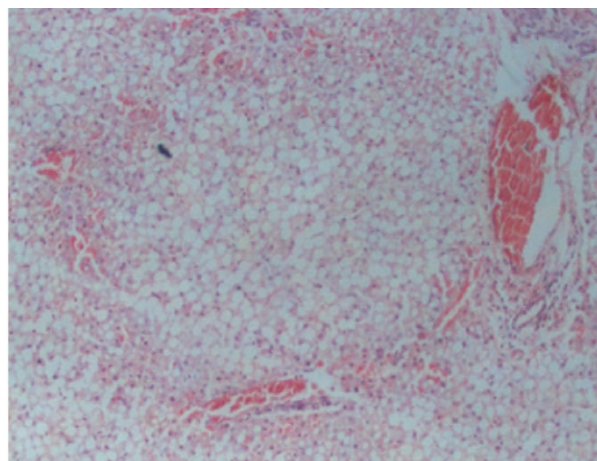


Figure 3: Liver from goat shows severe vacuolations of hepatocytes with displacement of nucleus to the periphery. Tissue section stained with H & E. plate at x100 magnification

REFERENCES

- ABDULLAHI, U. S., USMAN, G. S. H. and MSHELIA T. A. (1984): Impaction of rumen with indigestible garbage in cattle and sheep reared within urban and suburban environment. *Nig. Vet. Jol.* **13** 89-95.
- ALTINLI, E., SARIBEYOGLU, K. and URAS, C. (2004): Laparoscopic extirpation of a large gastric diospyrobezoar. Case Report, *Clin Pract Rev.* **5**: 503–505.

- BAILLIE, S. and ANZUINO, K. (2006): Hair balls as a cause of Anorexia in Angora Goats. *Goat.Vet. Soc. Jol.* **22**: 53-55.
- FRASER, A. F. and BROOM, D. M. (1990): Farm Animal Behaviour and Welfare, 3rd Edition *ELBS Baillier Tindall*, London, pp 318-322.
- IGBOKWE, I. O., KOLO, M. Y. and EGWU, G. O. (2003): Rumen impaction in sheep with indigestible foreign bodies in the semi-arid region of Nigeria. *Small Rumin. Res.* **49**: 141-146.
- JONES, T. C., HUNT, R. D. and KING, N. W. (1997): Foreign bodies. In: *Veterinary Pathology 6th Edition Williams and Wilkins Baltimore Maryland U.S.A*: pp 1066.
- MALHOTRA, A., JONES, L. and DRUGAS, G. (2008): Simultaneous gastric and small intestinal trichobezoars. *Ped. Emerg. Care* **24**: **11**: 774-6.
- MCGAVIN, M. D., CALTON, W. W. and ZACHARY, J. F. (2001): Foreign bodies. In: *Thompson's Special Veterinary Pathology. Molsby Inc. USA 3rd Edition* 18 pp.
- REMI-ADEWUNMI, B. D., GYANG, E. O. and OSINOWO, A. O. (2004): Abattoir survey of foreign body rumen impaction in small ruminants. *Nigerian Veterinary Journal* **25**: 32-38.
- SANDERS, M. K. (2004): Bezoars: From mystical charms to medical and nutritional management. *Pract. Gastroenterology*, January: 37-50.
- THEUS, M., BITTERLI, F. and FOLDENAUER, U. (2008): Successful treatment of gastric trichobezoars in a peruvian guinea pig (*Cavia aperea porcellus*). *Journal of Exotic Pet Medicine*. **17**: **2**: 148-151.
- WILLIAM, B. J., RAO, G. D. J., GEORGE, R. S., JAYAPRAKASH, R., AMEERJAN, K. DHARMACEELAN, S. and DAVID, W. P. A. (2000): Rumenotomy and abomasotomy to remove an unusual number of trichobezoars in a goat. *Indian Vet. Jol.* **77**: **4**: 332-333.