

CASE REPORT

ACTINOMYCOSIS IN A WEST AFRICAN DWARF GOAT IN NIGERIA.

OYEKUNLE¹, M.A., TALABI^{2*}, A.O, AGBAJE¹, M., ONI², O.O, ADEBAYO³, A.O.,
OLUDE³, M.A., OYEWUSI², I.K. and AKINDUTI¹, P.A.

¹Department of Veterinary Microbiology and Parasitology, ²Department of Veterinary Medicine and Surgery, ³Department of Veterinary Anatomy, College of Veterinary Medicine, University of Agriculture, Abeokuta, Nigeria.

*Corresponding Author: E-mail: deletalabi@yahoo.co.uk Tel.: +234-8023234495

INTRODUCTION

Actinomyces, also called Lumpy jaw is a chronic, progressive, indurated, granulomatous, suppurative abscess that most frequently involves the mandible, the maxillae or other bony tissues in the head. It is a sporadic but common disease in cattle, occasional in pigs and horses and rarely in goats (Radostits *et al.*, 2007). Members of the genus *Actinomyces* are Gram positive, non-acid fast, non-spore forming rods (Songer and Post, 2005) that form a mycelium of branching filaments that fragment into irregular-sized rods (Blood *et al.*, 2007). The species that commonly cause disease in domestic animals include *A. bovis*, *A. hordeovulneris*, *A. hyovaginalis*, *A. israelii*, *A. naeslundii*, *A. suis*, *A. viscosus* and *Arcanobacterium pyogenes* (Songer and Post, 2005). *Actinomyces bovis* is a common inhabitant of the bovine mouth and infection is presumed to occur through wounds to the buccal mucosa caused by sharp pieces of feed or foreign material. Infection may also occur through dental alveoli, and may account for the more common occurrence of the disease in young cattle when the teeth are erupting (Radostits *et al.*, 2007).

Actinomyces viscosus causes periodontal disease and subgingival plaques in hamsters fed a high carbohydrate diet, and also abscessation in dogs (Timoney *et al.*, 1988) in which it is an opportunistic infection (Blood *et al.*, 2007). The present report describes a case of actinomyces due to *A. viscosus* involving a doe in a herd of 42 West African Dwarf (WAD) goats kept intensively at the Teaching and Research Farm, University of Agriculture, Abeokuta, Nigeria.

Key words: isolation, *Actinomyces viscosus*, goat, Nigeria

MATERIALS AND METHODS

Case history

On the 16th of April, 2007, a 3-year old WAD doe was presented at the Teaching

and Research Farm, University of Agriculture, Abeokuta, Nigeria with an abscess at the right lower angle of the ramus of the mandible (Figure 1). History indicated a gradually advancing, painless,

hard and immovable swelling which later became painful to the touch.

The Teaching and Research Farm, University of Agriculture, Abeokuta, Nigeria is situated at Latitude 7° 9 ' 39"N and Longitude 3° 20 ' 54 "E (Wikipedia, 2010), 76m above sea level in the rain forest vegetation zone. The area has a humid climate with mean annual rainfall and temperature of 1037 mm and 34.7°C respectively and average relative humidity of 82% (Dipeolu *et al.*, 2005).

Clinical examination and management

Rectal temperature was 38.5°C; pulse and heart rate were within normal range, (Blood *et al.*, 2007) while the adjacent lymph node was normal. The animal had a soft and painful swelling at the ramus of the mandible. The abscess was allowed to mature after which the area over it was shaved, disinfected and lanced. Thick, brownish, mucopurulent exudate was aseptically collected from the animal using a sterile cotton swab stick (Evepon sterile swab stick®) and bacteriologically examined. The abscess was then drained and irrigated; while intramuscular injection of 20% long acting oxytetracycline (Kepro Oxytet 20% LA®, Kepro BV, Holland) at 20mg/kg live body weight was given twice at three days interval. The wound created was treated as an open wound with Oxytetracycline spray (Pederipra spray®, containing gentian violet, Oxytetracycline and lidocaine HCl, Hipra, Spain).

Bacteriological examination and characterization of the isolate

The purulent exudate from the diseased goat was seeded on a sterile 7% sheep blood agar plate which was incubated at 37°C for 48 hours under 5-10% carbon dioxide atmosphere obtained by a burning candle inside an anaerobic jar (Oxoid).

Staining: Films from the colonies on the sheep blood agar (Oxoid CM3) were stained by Gram's and Ziehl-Neelsen's (ZN) methods (Cowan and Steel, 1993) and examined under oil emersion objective (x100).

Motility: The isolate was examined for motility by observing a hanging drop preparation of a 24 hour nutrient broth culture of the organism under x40 objective of a binocular microscope (Olympus, Germany).

Catalase activity: This was demonstrated by transferring a speck of the colony from a 24 hour culture of the isolate on nutrient agar plate with a platinum wire loop to a drop of 3% hydrogen peroxide on a glass slide. This was observed for effervescence immediately.

Urease Production: This was tested by inoculating a 24 hour culture of the isolate from a nutrient agar plate onto a slope of Christensen's urea medium prepared according to the method described by Cowan and Steel (1993). The inoculated slope was incubated at 37°C and examined daily for colour change for up to 5 days.

Other tests: Tests for starch hydrolysis, indole production, gelatin liquefaction and hydrogen sulphide production from triple sugar iron agar (TSI) were done according to the procedures described by Cowan and Steel (1993).

Aerobic acid production from sugars:

For this test, peptone water (Oxoid) was used as the basal medium to which 1% Andrade's indicator was added. The medium was prepared and tested as described by Anonymous (1982). The following sugars were tested: arabinose,

mannitol, rhamnose, xylose and raffinose. The sugars were filter-sterilised (Sterile Syringe filter Corning, Germany) and each added aseptically to give a concentration of 1% (w/v) in the basal medium (Cowan and Steel, 1993). After inoculating the indicator sugar-peptone water medium with the isolate, utilization of each sugar was determined by change of colour from colourless to pink during incubation at 37°C for 1-7 days.

Haemolytic activity: Haemolytic activity of the isolate was demonstrated by agar plate method using 7% sheep blood-enriched nutrient agar (Cowan and Steel, 1993).

Antimicrobial sensitivity test: The isolate identified as *Actinomyces viscosus* was tested for its antimicrobial sensitivity by disc-diffusion method described by Barry and Thornberry (1991) using diagnostic sensitivity test (DST) agar (Oxoid) and Oxoid discs containing the antimicrobials shown on Table II.

RESULTS

White rough colonies of about 2-3 mm in diameter (Figure 2) were observed after 48 hours incubation. The colonies adhered to the medium. Stained smears of the colonies revealed Gram positive, diphtheroidal rods with slightly branched filaments and some showing beaded appearance (Figure 3) which were ZN negative (non acid fast). The biochemical characteristics of the isolate are presented in Table I. The sensitivity or resistance of the isolate to the tested antimicrobials (Table II) was based on reference zonal diameter interpretative standards (Anonymous, 2005). Healing was complete within 10 days post intervention.



FIGURE 1. The WAD goat at the time of presentation

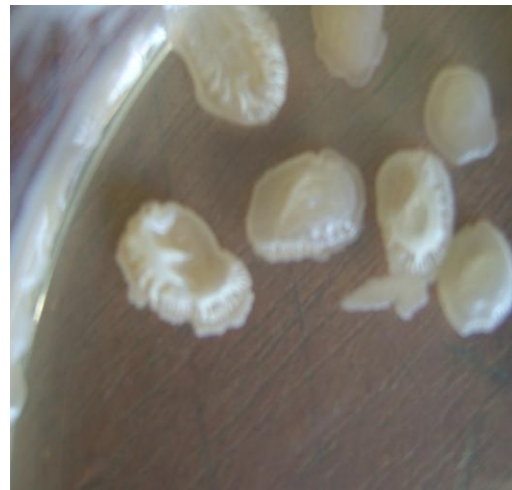

FIGURE 2. Colonies of *Actinomyces viscosus* on nutrient agar. 72h incubation at 37°C (x6)

TABLE I. Biochemical and physiological characteristics of the bacterial isolate from goat abscess

Tests	Results
Gram staining	Gram positive
Ziehl-Neelsen's staining	Non-acid fast
Catalase activity	Positive
Urease production	Positive
Motility	Non-motile
Haemolysis	Non-haemolytic
Acid production from:	
Arabinose	Positive
Mannitol	Positive
Rhamnose	Positive
Xylose	Positive
Raffinose	Positive
Starch hydrolysis	Positive
Gelatin liquefaction	Negative
Indole production	Negative
H ₂ S production from TSI	Negative

TABLE II. Antimicrobial sensitivity of *Actinomyces viscosus* isolated from goat abscess

S/N	Antimicrobial agent (µg)	Zone of inhibition (mm)	Remark
1	Enrofloxacin (10)	21	Sensitive
2	Methoprim (5)	28	Sensitive
3	Oxytetracycline (30)	20	Sensitive
4	Norfloxacin (10)	20	Sensitive
5	Ciprofloxacin (10)	18	Resistant
6	Gentamycin (10)	16	Resistant
7	Penicillin G (10)	21	Resistant
8	Amoxycillin (10)	11	Resistant
9	Sulphamethaxazole (25)	0	Resistant

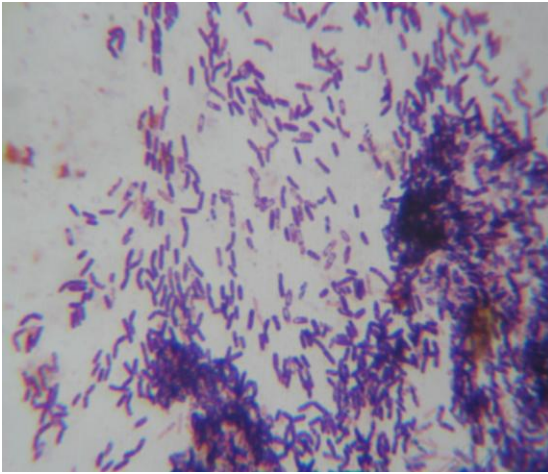


FIGURE 3. Gram stain of *A. viscosus* Showing diphtheroidal rods with slightly branched filaments (x1000)

DISCUSSION

The colonial and cell morphology of the isolate was consistent with that of the genus *Actinomyces* (Songer and Post, 2005). Although *Actinomyces* species are Gram positive, non spore forming rods or filaments, they often stain irregularly, giving rise to a beaded appearance (Holt *et al.*, 1994; Biberstein and Hirsh, 2004) as observed in this study (Figure 3). Holt *et al.*, (1994) observed that *Actinomyces viscosus* show swollen or clubbed heads; this characteristic is consistent with the organism isolated in this case as shown in Figure 3. The isolate was therefore identified as *Actinomyces viscosus* on the basis of its biochemical and physiological characteristics (Table I) according to Songer and Post (2005). It is to be noted however, that differentiation of species of the genus *Actinomyces* on the basis of biochemical tests may be difficult because of variable test reaction (Dent and Williams, 1986; Johnson *et al.*, 1990). Actinomycosis (Lumpy jaw) is rare in goats; the condition which is caused by *Actinomyces bovis* is common in cattle

(Seifi *et al.*, 2003). The organism isolated in this case, *Actinomyces viscosus* is one of the important flora in periodontal disease of dogs, where it causes chronic pneumonia, pyothorax and localised subcutaneous abscesses after a traumatic injury such as a bite wound (Kahn, 2005). This is the first report of *Actinomyces viscosus* in Nigerian goat.

There has been a general understanding that typical *Actinomyces* species, *A. israelii*, *A. naeslundii*, and *A. viscosus* associated with human actinomycotic infection, are members of the normal flora or are commensals in the oral cavity (Grange, 2002; Brooks *et al.*, 2004). Also, the causative agent of Lumpy jaw in cattle, *Actinomyces bovis* is part of the normal flora of the oral cavity of the animal species in which it causes disease (Seifi *et al.*, 2003). The organisms gain access to deeper tissues of the jaw by way of the dental alveoli or paralveoli, or through mucosae damaged by rough feed or foreign bodies (Songer and Post, 2005). The route of entry of the causative bacteria was not found in this goat. The habitat of *A. viscosus* is probably the oropharynx and digestive tract, where the organism is an obligate parasite. Most infections are seen in large hunting dogs and there is a consistent history of trauma to the infected sites (Timoney *et al.*, 1988).

The complete recovery of the doe within 10 days post intervention suggests effectiveness of the therapy. The choice of chemotherapeutic agents for the management of the condition was based on the result of the antimicrobial sensitivity test (Table II). Poor prognosis could be expected when therapy is delayed (Welker, 1999) and when there is chronic osteomyelitis in which there is diminished blood supply to the affected area (Altmaier *et al.*, 1994; Radostits *et al.*, 2007) and subsequent prevention of

effective antimicrobial level at the infected site (Altimaiier *et al.*, 1994).

Dictionary, 3rd ed., Saunders Elsevier. London. 23.

REFERENCES

- ANONYMOUS (1982): Culture media, ingredients and other laboratory services, 5th ed., Oxoid Ltd., London. 245.
- ANONYMOUS (2005): National committee for Clinical Laboratory Standards. Performance standards for antimicrobial disc susceptibility tests. Approved standard document M2-A8 wayne (P.A.)
- ALTIMAIER, K. R., SHERMAN, D. M., SCHELLING, S. H., FISTER, R. D. and LAMB, C. R. (1994): Osteomyelitis and disseminated infection caused by *Corynebacterium renale* in goat. *J. Am. Vet. Med. Assoc.* **204**, 934-937.
- BARRY, A. L. and THORNBERRY, C. (1991): Susceptibility Tests: Diffusion test procedures. In: Manual of Clinical Microbiology. (Ballows, A. H., W. J. J. Hausla, K. L. Herrman, H. D. Isenberg, H. J. Shadowny, Eds.), 5th ed., American Society for Microbiology. Washington DC. 1117-1125.
- BIBERSTEIN, E. L. and HIRSH, D. C. (2004): Filamentous Bacteria: Actinomyces, Nocardia, Dermatophilus and Streptobacillus. In: Veterinary Microbiology (Hirsh, D. C., N. J. MacLachlan, R. L. Walker, Eds.), 2nd ed., Blackwell Publishing. 215.
- BLOOD, D. C., STUDDERT, V. P. and GAY, C. C. (2007): Saunders Comprehensive Veterinary Dictionary, 3rd ed., Saunders Elsevier. London. 23.
- BROOKS, G. F., BUTEL, J. S. and MORSE, S. A. (2004): Non-spore-forming gram Positive Bacilli. *Corynebacterium*, *Propionibacterium*, *Listeria*, *Erysipelothrix*, *Actinomycetes* and Related Pathogens. In: Jawetz, Melnick and Aldeiberg Medical Microbiology, 23rd ed. McGraw Hill, New York. 212-222.
- COWAN, S. T. and STEEL, K. J. (1993): Manual for the Identification of Medical Bacteria (Barrow, G. I., R. K. A. Felthan, Eds.). 3rd ed., Cambridge University press. UK. 213-218.
- DENT, V. E. and WILLIAMS, R. A. D. (1986): *Actinomyces slackii* sp. nov. from dental plaque of dairy cattle. *Int. J. Syst. Bacteriol.* **36**, 392-395.
- DIPEOLU, M. A., ERUVBETINE, D., OGUNTONA, E. B., BANKOLE, O. O. and SOWUNMI, K. S. (2005): Comparison of effects of antibiotics and enzyme inclusion in diets of laying birds. *Arch. Zootec.* **54**, 3-11.
- GRANGE, J. M. (2002): Actinomyces, Nocardia and Tropheryma (Actinomycosis, Nocardiosis, Whipple's disease). In: Medical Microbiology, A guide to microbial infections: Pathogenesis, Immunity, Laboratory diagnosis and Control. (Greenwood, D, Slack, R.C.B. and Pentherer J.F., Eds.). 16th ed., Churchill Livingstone, London. 221-224.
- HOLT, J. G., KRIEG, N. R., SNEATH, P. H. A., STALEY, J. T. and WILLIAMS, S. T. (1994):

- Irregularly Non-sporing Gram Positive Reds. In: Bergey's Manual of Determinative Bacteriology, 9th ed., Williams and Wilkins, Baltimore Md. 571.
- JOHNSON, J. L., MOORE, L. V. H., KANEKO, C. B. and MOORE, W. E. C. (1990): *Actinomyces georgiae* sp. nov., *Actinomyces gerensceriae* sp. nov.: Designation of two genospecies of *Actinomyces haeslundii*, and inclusion of *A. haeslundii* serotypes 1 and 2 and *Actinomyces viscosus* serotype 2 and *Actinomyces haeslundii* genospecies 2. *Int. J. Syst. Bacteriol.* **40**, 273-286.
- KAHN, C. M. (2005): The Merck Veterinary Manual, 9th ed., Merck & Co., Inc. Rahway, U.S.A. pp 477-478.
- RADOSTITS, O. M., GAY, C. C., HINCHCLIFF, K. W. and CONSTABLE, P. D. (2007): Veterinary Medicine: A Textbook of the Diseases of Cattle, Sheep, Pigs, Goats and Horses. 10th ed., Saunders Elsevier, Spain. 1045-1046.
- FARROKHI, F. (2003): Mandibular pyogranulomatous osteomyelitis in a sannen goat. *J. Vet. Med. A.* **50**, 219-221.
- SONGER, J. G. and POST, K. W. (2005): Veterinary Microbiology, Bacterial and Fungal agents of Animal Diseases. Elsevier Saunders, USA. 54-58.
- TIMONEY, J. F., GILLESPIE, J. H., SCOTT, F. W. and BARLOUGH, J. E. (1988): Hagan and Bruner's Microbiology and Infectious diseases of domestic animals, 8th ed., Cornell University Press, USA. 259-266.
- WELKER, B. (1999): Osteomyelitis. In: Current Veterinary Therapy – Food Animal Practice (Howard, J.L. R.A. Smith SEIFI, H. A., SAIFZADEH, S., FARSHID, A. A., RAD, M. Eds.). 4th ed., W.B. Saunders, Philadelphia. 692-693.
- WIKIPEDIA (2010): Wikipedia, The Free Encyclopedia
<http://en.wikipedia.org/wiki/Abeokuta>