Nigerian Veterinary Journal Vol. 28(3) 2007:64-65

Case Report

INTESTINAL FOREIGN BODY WITH CONCURRENT CANINE PARVOVIRUS ENTERITIS IN A DOG: A CASE REPORT

JAHUN[1]*, B. M., HASSAN[2], A. Z. and REMI-ADEWUMI[2], B. D.

[1]*Veterinary Teaching Hospital,* [2]*Department of Veterinary Surgery and Medicine, Ahmadu Bello University, Zaria- Nigeria.*

INTRODUCTION

Dogs eat all sorts of objects ranging from rocks, nails, grass, paper, bones and faeces. This condition of ingestion of nonfood material is referred to as Pica (Overall, 2005). Occasionally, objects that the dog would only chew onto or hold in its mouth are inadvertently swallowed. Fortunately, most objects that make it to the stomach are either digested or simply passed out with the stool or regurgitated. Wooden foreign bodies have been identified in the stomach and abdominal cavity of dogs (Penninck and Mitchell, 2003 and Hunt *et al.*, 2003). Pneumothorax resulting from perforation of the stomach and diaphragm sequel to ingestion of foreign body has also been reported (Hunt *et al.*, 2003). Horstman *et al* (2003) diagnosed gastric foreign body from survey abdominal radiograph of a dog where a large aggregate of solidified wood glue was surgically removed. The development of anuric renal failure associated with zinc intoxication was also detected in a dog following ingestion of an ornamental brass knob from a toilet paper holder (Volmer *et al.*, 2004). These show that ingestion of foreign body may pose a severe consequence in dogs.

KEYWORDS: Diarrhoea, Foreign body, Metal rods

CASE REPORT

A four month old male Alsatian puppy weighing 6 kg was presented to the Small Animal Unit of the Veterinary Teaching Hospital, Ahmadu Bello University, Zaria-Nigeria with complaint of diarrhea and anorexia. In the course of taking history, it was gathered that the owner of the puppy is an artist with particular interest in sculptures, and the puppy sometimes plays around the art studio.

On physical examination, the dog was dull and lethargic. Temperature (38.7° C), Pulse (98 beats /min.), and Respiratory rates (28 cycles/min.) were within normal range. The puppy was slightly dehydrated (7%) and few ticks were present on its body. While it was being examined on the table, it passed haemorrhagic faeces with characteristic offensive odor attributable to Canine Parvovirus Enteritis (CPE) and containing four small metal objects (Plate 1). Two of the metal objects were iron rods measuring 4 cm while the other two were screws measuring 2 cm in length.

Ventro- medial (VD) and lateral X-ray views of the abdomen radiographic were taken to check for possible presence of more foreign materials. Blood sample was obtained from the puppy for complete blood count and protozoological screening. Faecal samples were also obtained for helminthological and heamagglutination inhibition (HI) tests.

The puppy was treated for CPE with Gentamycin sulfate, (Gentalek® Lek Pharmaceuticals) 24 mg intramuscularly (i/m) for five days; Darrow's solution (Dana Pharmaceuticals, Minna-Nigeria) 360 ml intravenously (i/v) for replacement and 240 ml for maintenance 24hrs X 3/7; Vitamin B complex (Becomax® Maxheal Pharmaceuticals, India) 1 ml i/m for five days were administered. Resting of the gastrointestinal tract by restricting feed while the dog was on the therapy was advised.

Results of investigations conducted were:
Feces- no parasites or ova seen,
Blood- no parasites for protozoology,
haematology showed
PCV- 54%
Hb- 18.0g/dl
WBC- 7.5x 109/l
Neutrophils- 71%
Lymphocytes- 23%
Monocytes- 3%
Eosinophils- 3%
Total protein- 5.4g/dl
Radiograph of the abdomen revealed additional metal objects (Plate 2) within the abdominal region of the puppy.

The therapy for CPE was continued until the dog recovered enough to withstand surgical removal of the remaining metal objects in its stomach. The diarrhea stopped three days post commencement of treatment and the puppy started lapping water by the fourth day. Seven days later, the appetite of the dog had resumed and another radiograph of the abdomen was taken but it showed no foreign objects. The client was then advised to check the puppy's feces at home for the foreign objects. He came back later to show a number of iron rods and screws he found in the puppy's feces (Plate 3).

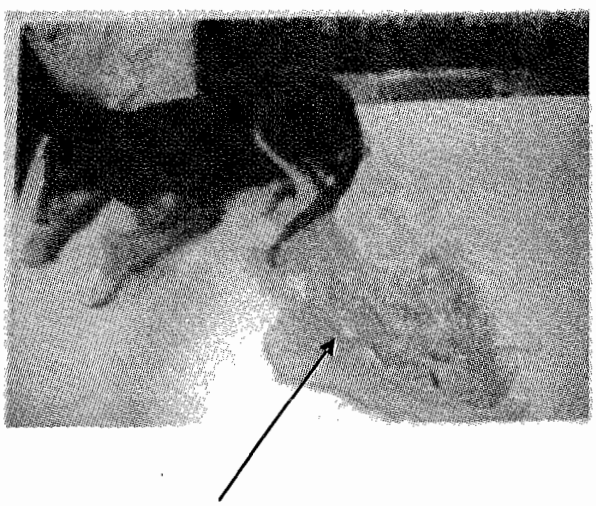

PLATE 1: Dog passing out bloody diarrhoea containing foreign bodies on the examination table

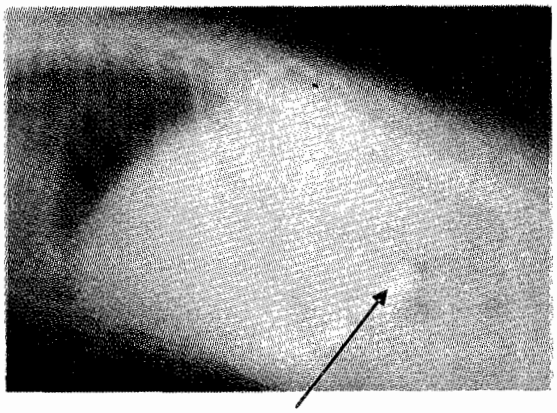

PLATE 2: Radiograph showing foreign bodies (screws) in the stomach of the puppy



PLATE 3: More foreign materials found in the feces of the affected dog at home

DISCUSSION

Puppies are known to pick foreign materials such as hair balls and in this part of the world polythene bags are seen frequently in feces of both puppies and adult dogs (Dada and Bellino 1980). While playing or simply because of avidity, dogs may ingest a variety of foreign bodies (Capak *et al.*, 2001). Some of the materials may be toxic to the dog (Volmer *et el.*, 2004 and Horstman *et al.*, 1981) and the patient may show clinical signs ranging from slight discomfort to clinical intoxication. In this case the puppy was presented to the clinic with a different complain from that of foreign body and the finding was incidental. Some dogs are able to expel the ingested materials without having to go to the hospital which would have been the case with the dog reported, if not for the CPE infection. Surgery was planned in our case because the materials in the feces were metal rods screws (Plate 1) because it was thought that the pointed ends of these metals may be stuck in the intestinal epithelium

probably causing perforations of the intestine. The fact that the puppy had CPE contributed to the removal of the materials because of increased peristalsis, but this could also have contributed to the materials getting stuck in the mucosa. It is not very clear why the puppy kept on ingesting the metal objects after the first attempt since the objects were neither tasty nor having an attractive odor. The condition of the puppy also suggested a well fed puppy. It may be possible that what the artist was using to glue the metals together may be enticing to the puppy.

In our environment, ingestion of foreign materials is mostly seen in mongrels because exotic dogs are normally kept in clean and well kept environment with good and nutritious diets. However, even well kept dogs sometimes consume certain things especially when the owners are not present or when bored. The hemorrhagic gastroenteritis seen is not related to the foreign bodies seen but as a result of CPE but they may worsen the enteritis because of irritation of the intestinal epithelium by their presence causes. Ingested foreign bodies, which are not trapped in the mouth or esophagus, pass into the stomach. Once a foreign body has passed through the pylorus, the jejunum and the ileum are said to be the most common sites of the small intestine obstruction (Capak *et al.,* 2001). In this case, it was concluded that the presence of metal objects in the gastrointestinal tract of dogs may not require surgical removal unless there is an emergency such as in perforations as many cases like the one presented can resolve by expulsion of the objects in faeces.

REFERENCES

CAPAK, D., SIMPRAGA, M., MATICIC, D., BALI, R. and JANOSKA, B.(2001): Incidence of foreign-bodyinduced ileus in dogs. *Berl Munch Tierarztl Wochenschr,* **114**(7-8):290-296.

DADA, B.J.O. and BELINO, E.D. (1980): Prevalence and public health significance of helminth ova in dog's faeces deposited on the streets of Zaria, Nigeria. *Ann. Trop. Med. and Parasitol.,* **75**: 495-498.

HAMMOND, G.M., LOEWEN, M.E. and BLAKLEY, B.R. (2004): Diagnosis and treatment of zinc poisoning in a dog. *Ve.t Hum. Toxicol.,* **46**(5):272-5.

HORSTMAN, C.L., EUBIG, P.A., CORNELL, K.K., KHAN, S.A. and SELCER, B.A. (2003): Gastric outflow obstruction after ingestion of wood glue in a dog. *J. Am. Anim. Hosp. Assoc.,* **39**(1):47-51.

HUNT, G.B., WORTH, A. and MARCHEVSKY, A. (2004): Migration of wooden skewer foreign bodies from the gastrointestinal tract in eight dogs. *J. Small. Anim. Pract.,* **45**(7):362-7.

KING, N.B. (1981): Ingestion of a foreign body by a dog. *Aust. Ve.t J.,* .**57**(10):483.

OVERALL, K. I. (2005): Behavioural Medicine Introduction, Normal Social Behaviour and Behavioural Problems of Domestic Animals. In: The Merck Veterinary Manual. 9th Ed. and 50th Anniversary Edition. C. M. Kahn, Ed. Merck and Co.,INC. Whitehouse Station, NJ., USA in educational partnership with Merial, Ltd, A Merck and Aventis Company;132.

PENNINCK, D. and MITCHELL, S.L. (2003): Ultrasonographic detection of ingested and perforating wooden foreign bodies in four dogs. *J. Am. Vet. Med. Assoc.,* **223**(2):206-9, 196.

RAO, R.L. (1979): Foreign body movement in the alimentary tract of a dog *Indian Vet. J.,* **56**(4):331-2.

STOWATER, J.L. (1980): Gastric foreign body in a dog: case report and discussion of radiographic principles. *Vet. Med. Small. Anim. Clin.,* **75**(7):1143-8.

VOLMER, P.A., ROBERTS, J. and MEERDINK, G.L. (2004): Anuric renal failure associated
with zinc toxicosis in a dog. *Vet. Hum. Toxicol.,* **46**(5):276-8.