

## Short Communications

### INFERTILITY ASSOCIATED WITH SEVERE VULVAL DERMATOPHILOSIS IN A BUNAJI COW IN A SETTLED CATTLE HERD IN ZARIA, NORTHERN NIGERIA

ATE<sup>1\*</sup>, I. U., REKWOT<sup>2</sup>, P. I., NOK<sup>3</sup>, A. J. and TEKDEK<sup>1</sup>, L. B.

<sup>1</sup>Department of Veterinary Surgery and Medicine, <sup>2</sup>Artificial Insemination Unit, National Animal Production Research Institute, <sup>3</sup>Department of Biochemistry, Ahmadu Bello University, Zaria

\*Correspondence: E-mail: [utimphd@yahoo.com](mailto:utimphd@yahoo.com), Tel: +234 806 560 9268

#### SUMMARY

This case report is of a severe vulval dermatophilosis (infection with *Dematophilus congolensis*) in a Bunaji cow in a settled cattle herd in Zaria, (latitude 11° 08'N), Northern Nigeria. The infection was associated with infertility due to physical obstruction to penile intromission, due to the vulval scab lesions, thereby adding another dimension to the economic losses of the disease especially in the female. The intractable nature of the disease, and the fact that the cow could not conceive, resulted in the eventual culling of the cow by the owner. The poor physical condition of the cow led to a very poor culling market value. The role of vulval dermatophilosis in cycling females that may permit service by the bulls in the transmission of the disease to serving bulls is considered to present a research challenge.

**KEY WORDS:** infertility, vulva, dermatophilosis, Bunaji, cow

#### INTRODUCTION

Bovine dermatophilosis (bovine cutaneous streptotrichosis, 'kirchi' in Hausa language, Nigeria) is a superficial bacterial dermatitis (Evans, 1996) caused by *Dematophilus congolensis*, a pleomorphic, Gram positive actinomycete (Oduye, 1975; Seifert, 1996); and is characterized by exudation and crust formation (Evans, 1996) or scab formation (Oduye, 1975; Oppong, 1976). The disease has a world wide distribution. It is a typical enzootic of the hot humid tropics (Seifert, 1996). It is of most economic significance in tropical Africa (Oduye, 1975; Seifert, 1996). The disease is of most importance for its role in causing economic loss through damage of hides and skins, reduced milk yield, marked debility in severely affected animals with dehydration and death, in cattle (Oduye, 1975).

In Nigeria, it is a common dermatologic condition in cattle especially during the rainy season (Ogwu et al., 1981); and is particularly devastating in exotic and crossbreed cattle (Sekoni, 1983). The disease also occurs in

humans (Thomsett, 1992). Though the mode of transmission of the disease is remains unclear, tick infestation, skin damage, and demodectic mange, are considered epidemiological factors that play a role in the occurrence of the disease (Kahn, 2005) of dermatophilosis on the reproductive system of cattle has been reported in Nigeria (Ogwu et al., 1981; Sekoni, 1983). Ogwu et al. (1981) reported ovarian atrophy, anestrus, and decline in pregnancy and calving rates in moderately to severely affected female cattle while Sekoni (1983) reported a terminal sterility associated with stoppage of spermatogenesis in a Friesian bull naturally infected with chronic scrotal cutaneous streptotrichosis. This case report is to further document the fertility disorder associated with this intractable disease and its associated economic impact through culling in a Bunaji cow.

#### CASE HISTORY

This case involved a Bunaji cow (weighing 200 kg) aged about 4 years, belonging to a settled cattle herd in Zaria, Northern Nigeria. The herd is one of the nine herds in the area investigated for

## **ATE et al: Infertility associated with vulval dermatophilosis in Bunaji cow**

reproductive disorders, particularly puerperal disorders, during a four - year period (2001 to 2005), and this case was handled during the rainy season between June to September, 2004. The herd had consisted of 14 cows, 14 heifers, 7 bulls and 6 calves, making a total of 41 animals of Bunaji breed. The affected cow had been treated unsuccessfully previously by a team of veterinary surgeons of the Ahmadu Bello University Teaching Hospital, Zaria Nigeria. The cow was unable to mate for a long time due to the genital lesion and consequently could not conceive. It had successfully calved once prior to this severe infection.

### **Clinical examination and diagnosis**


A thorough physical examination of the affected cow revealed the followings: Vital parameters (temperature, pulse and respiratory rates) were not adversely affected. The entire vulva and the area around the base of the tail were covered by dermatophilus lesions (Plates 1 and 2). Other parts of the body were also covered with the lesions. The cow was severely emaciated, weak and preferred to be on sternal recumbency. Rectal palpation, which was rather difficult due to presence of the lesions, indicated that the ovaries were non functional, containing no functional structures.

The dermatophilus lesions were also found on the thighs, abdomen and tail.

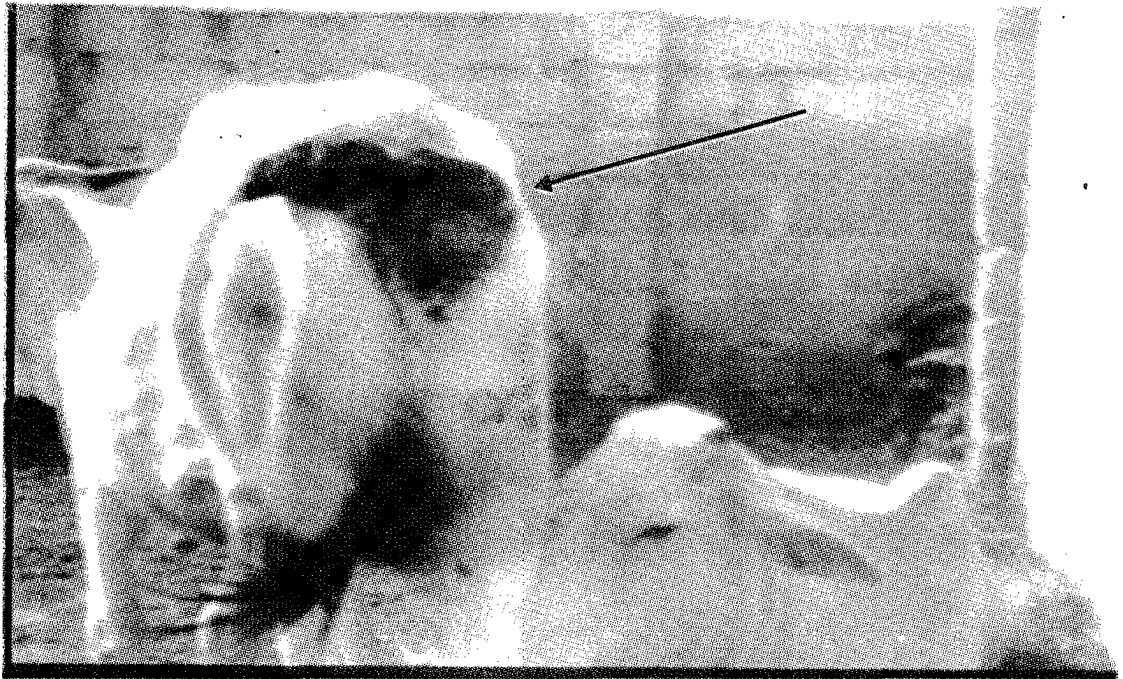A clinical diagnosis of severe vulval dermatophilosis was made on the basis of the appearance of the characteristic skin lesions (scabs on the vulva and perineal areas) that are almost pathognomonic, and the demonstration of the causative agent, *Dermatophilus congolensis* (Berg, 1981) from the skin sample.

## **RESULTS AND DISCUSSION**

Plates 1 and 2 show the severe vulval and perineal dermatophilus scab lesions in the affected cow. In plate 2, the tail has been pushed laterally to fully expose the entire vulva that was covered by the lesions. The vulval lesions (scabs) completely occluded the vulval opening such that penile intromission could not have been effected even if this cow was in estrus (heat). The scabs, therefore, constituted physical obstruction to coitus, thus resulting in infertility. The absence of cyclicity in this cow was probably due to the poor physical body condition of the cow due to the debilitating nature of the disease.



**PLATE 1: Severe vulval dermatophilosis in a Bunaji cow (arrow).**



**PLATE 2: Severe vulval dermatophilosis in a Bunaji cow, with tail pushed aside.**

Ogwu et al. (1981) reported ovarian atrophy in moderately to severely affected female cattle with dermatophilosis. Dermatophilosis lesions mostly appear on the ventral areas of the body such as axilla, brisket, and inguinal areas, and in cattle, it occurs mostly on the scrotum or udder (Evans, 1996). Vulval lesions as seen in this case are not a common occurrence. The infertility associated with physical obstruction to penile intromission due to these lesions adds another dimension to the economic losses of the disease especially in the female. The intractable nature of the disease and the fact that the cow could not conceive resulted in the culling of the cow by the owner.

The poor physical condition of the cow led to a poor market value. At the estimated weight of 200 kg, this cow could have sold at a prevailing market price of about eighty thousand naira (N80, 000.00), but due to the poor physical condition and aesthetic implications of the lesions, this cow was sold for only a paltry sum of thirty five thousand naira (N35, 000.00), thus resulting in a colossal loss to the owner to the tune of over forty thousand naira (N40, 000.00). Indeed, if not for the disease condition, this cow

would have weighed even more and could possibly have sold for a higher market price. Thus, if this is taken into consideration, the owner actually lost more than the stated figure.

The losses associated with this disease therefore, could be estimated from several perspectives which are: failure of production of calves by the cow for the owner, loss of market value due to the poor body condition (over forty thousand naira as estimated), loss associated with the feeding of an infertile cow for a long time and the cost of prolonged, unsuccessful chemotherapy with oxytetracycline (Terramycin long acting). The non response of the vulval lesions to oxytetracycline therapy may have been due to drug resistance as tetracycline had been reported to be effective against dermatophilosis (Ogwu et al., 1981) and possibly the nature of the location (vulva).

This case, just like others, calls for more and sustained efforts at controlling this important disease in Nigeria. At present, there is a decline in research efforts directed towards confronting this malaise. The role of vulval dermatophilosis in cycling females in the possible transmission of

the disease to serving bulls is considered to present a new research challenge to veterinary practitioners.

#### **ACKNOWLEDGEMENT**

The authors wish to acknowledge the role of the consulting veterinary surgeons to the farm, Drs. A. K. Sackey, S. T. Fadason, and J. S. Rwuaan, of the Ahmadu Bello University Veterinary Teaching Hospital, Zaria, Nigeria, for facilitating access to the farm to undertake the study; the herd owner for giving consent for the study and Mallam Chindo, the herdsman, who was always willing to assist in handling and restraint of the animals and Ahmadu Bello University for sponsoring the study.

#### **REFERENCES**

- BERG, J. N. (1981). Dermatophilosis. In: Current Veterinary Therapy. Food Animal Practice. Howard, J. L. (Ed.). First Edition. W. B. Saunders, Philadelphia; 748-49.
- EVANS, A. G. (1996). Dermatophilosis (Bacterial Diseases). In: Large Animal Internal Medicine. Second Edition. Mosby Publishers; 1411-412.
- KAHN, C. M. (2005). Dermatophilosis. In: The Merck Veterinary Manual. 9th Ed; 690-692.
- ODUYE, O. O. (1975). Bovine cutaneous streptotrichosis in Nigeria. *Wld. Anim Review.*, 16: 13-7.
- OGWU, D., ALHAJI, I., and OSORI, D. I. K. (1984). Effectiveness of long acting Teramycin injectable solution in the treatment of streptotrichosis in cattle. *Brit. Vet. J.*, 17, 358-89.
- OPPONG, E. N. (1976). Epizootiology of dermatophilus infection in the Accra plains of Ghana. In: Lloyd, D. H. and Sellers, K. C. (Eds). *Dermatophilus infection of Animals and Man.* Academic Press, London; 17-32.
- SEIFERT, H. S. H. (1996). *Tropical Animal Health.* Kluwer Academic Publishers; 352-355.
- SEKONI, V. O. (1983). Terminal sterility in a Friesian bull naturally infected with chronic scrotal streptotrichosis (Kirchi). *Therio.*, 20(1): 27-37.
- THOMSETT, L. R. (1992). Skin Conditions. In: *Bovine Medicine. Diseases and Husbandry of Cattle.* Andrews, A. H., Blowey, R. W, Boyd, H. and Eddy, R. G. (Eds). First Edition. Blackwell Scientific Publications, London. 677-690.
- SEKONI, V. O. (1983b). Effects of severe chronic scrotal *Dermatophilus congolensis* (Kirchi) infection on semen characteristics in Zebu /Friesian crossbred bulls and effect of long acting Terramycin chemotherapy. *Therio.*, 40: 211 223.