

**ANYA ET AL: Cervico-vaginal and rectal prolapse in two (WAD) Goats in Nsukka, Nigeria**

**CERVICO-VAGINAL AND RECTAL PROLAPSE IN TWO WEST AFRICAN DWARF (WAD) GOATS IN NSUKKA, NIGERIA: A CASE REPORT**

**ANYA<sup>1</sup>, K.O., NNAJI<sup>2</sup>, T.O. and UDEGBUNAM<sup>2</sup>, S.O.**

**<sup>1</sup>Department of Veterinary Obstetrics and Reproductive Diseases, Nsukka <sup>2</sup> Department of Veterinary Surgery, University of Nigeria, Nsukka, Nigeria.**

**\* Correspondence: Tel +234-805-882-0561; +234-808-313-7158**

**SUMMARY**

**A report is presented of two cases of cervico-vaginal and rectal prolapse involving a nulliparous, primigravid and an older pluriparous WAD goat raised semi-intensively. The cases were presented at the veterinary teaching hospital (VTH), University of Nigeria Nsukka (UNN) within one week of each other. One of the goats died while the other had uncomplicated kidding two weeks after successful prolapse reduction. The predisposing factors and the technique of prolapse reduction adopted are discussed.**

**KEYWORDS: Prolapse, Cervico-vaginal, Rectal, Improvised prolapse retainer**

## INTRODUCTION

Cervico-vaginal prolapse (CVP) is a disorder of ruminants in late gestation (Claus, 1997). It may occasionally be seen after parturition and rarely unconnected with pregnancy and parturition. The disorder has been reported in other domestic animals. In the sheep and cow the incidence is affected by breed (Edgar, 1952; Bosse et al, 1989). The exact cause of the disorder has not been ascertained but the predisposing factors have been described (Noakes, 1999). The ease of occurrence of CVP depends on both the compliance of the vaginal wall and the size of the vaginal lumen (Ayen et al; 1998. Ayen and Noakes, 1998). In the goat, the causes of CVP are similar to those of sheep and cattle (Franklin, 1986). The complicating rectal prolapse is due to tenesmus and expulsive straining effort (Colins and Gary, 1989). The economic importance of CVP is seen in increased maternal mortality, abortion, stillbirth and neonatal mortality rates, increased culling rate, increased

dystocia rate and reduced fertility (Hosie, 1989).

In Nigeria the incidence and economic importance of cervico-vaginal and rectal prolapse, especially in indigenous livestock, have not been determined. This report presents two cases of Cervico-vaginal and rectal prolapse in the WAD goat resulting in the death of one of them. It is hoped that this report will stimulate interest in the evaluation of the incidence and economic importance of the conditions in indigenous livestock in Nigeria. The report also describes our new technique of management of rectal prolapse in WAD goat.

## CASE REPORT

A gravid pluriparous and another 11 month old primigravid WAD goat were presented at the VTH, U.N.N. with a severe (Cox, 1987) or stage III (Bosse et al, 1989) CVP complicated by rectal prolapse as shown in Plate I.

The primigravid goat started straining about a week to the date of presentation at the VTH, U.N.N. and was already recumbent with weak intermittent straining. The everted organs were In Nigeria the incidence and economic importance of cervico-vaginal and rectal prolapse, especially in indigenous livestock, have not been determined. This report presents two cases of Cervico-vaginal and rectal prolapse in the WAD goat resulting in the death of one of them. It is hoped that this report will stimulate interest in the evaluation of the incidence and economic importance of the conditions in indigenous livestock in Nigeria. The report also describes our new technique of management of rectal prolapse in WAD goat.

Pregnancy was confirmed by abdominal ballottement and radiography and each was carrying twin pregnancies. The everted organs were washed with clean water and a warm hypertonic solution of 50% dextrose used to reduce the edema by vascular constriction and osmosis (Johnson, D.E, 1985). Pain, discomfort and straining were minimized by epidural anaesthesia (Jessica, 1986). Prolapse reduction was facilitated by elevation of the hindquarters of the patients and lubrication of the everted

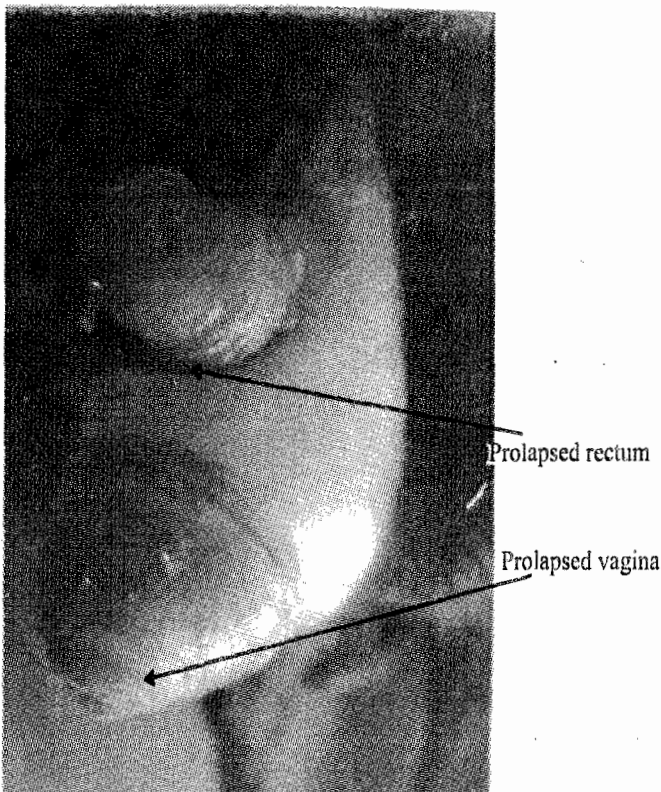


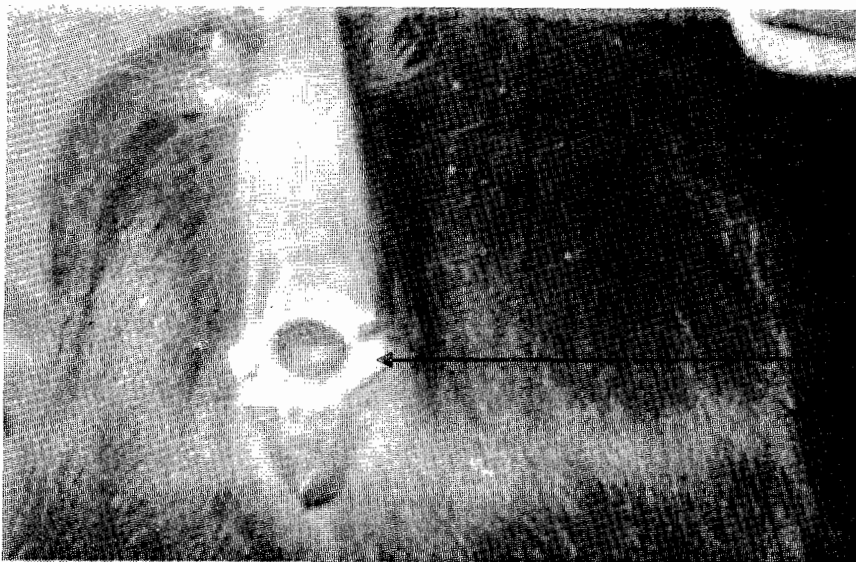
Plate I: Prolapsed rectum and vagina

organs with paraffin oil. A purse string suture using silk (size 2/0) was placed on the vulvar lips. The rectal prolapse was similarly reduced and retained in-situ with an improvised prolapse retainer devised for that purpose as shown in Plate II.

The technique involved the use of a 10ml syringe whose plunger has been removed and the needle end cut to ensure wider diameter. The cut end was smoothed to prevent trauma and irritation of the rectal mucosa. Two holes were bored at the other free end of the tube, which was then lubricated with K-Y jelly and inserted

into the rectum of the goats. Two stay sutures were then placed at the ano-cutaneous junction through the holes bored to hold the improvised prolapse retainer in place.

The nulliparous primigravid goat died a day after prolapse reduction. The prolapse retainer and vulvar sutures were removed a week later in the surviving pluriparous goat. Post operatively, the patient was placed on procaine penicillin (10,000 IU/kg) and streptomycin (10mg/kg) intramuscularly for seven days.



The improvised prolapse retainer in situ

**Plate II: Showing the animal after reduction of the Rectal prolapse with the retainer**

The goat had an uncomplicated kidding two weeks after the successful operation.

### **DISCUSSION**

CVP is not as common in the goat as in the pregnant sheep but occasionally, it occurs during the last 5 weeks of caprine pregnancy (Baker, 1980). Rectal prolapse is usually sequel to lesions of the pelvic musculature or the anal sphincter (Amoud, 1974) but may follow persistent and severe tenesmus (Colins and Gary 1989). In the sheep, CVP is more frequently encountered in the plurigravid ewe (Ayen et al; 1998) and in ewes carrying more than one lamb (Clarkson and Faull, 1990). In this report, CVP

occurred in the last 3 weeks of gestation and this agrees with Baker (1980). The occurrence of CVP in the pluriparous goat carrying twin pregnancy is also in agreement with the report by others (Ayen et al; 1998; Clarkson and Faull, 1990).

The associated rectal prolapse in these cases of CVP is due to expulsive straining effort as infection of the everted vagina causes irritation to the animal (Colins & Gary, 1989). Although the compliance of the vaginal wall is greater in plurigravid than primigravid animals (Ayen et al; 1998), factors such as large fetal load, husbandry, dietary supplementation and possibly heredity may have brought about the occurrence of CVP


in the primigravid WAD goat in this report (Noakes, 1999). It is thought that the death of the primigravid goat in this report may be sequel to shock, exhaustion and septicemia resulting from infection of the everted organs.

The improvised rectal prolapse retainer is one that should recommend itself to our local practice environment where everything is in short supply or non-existent. It has the advantages of holding the reduced organ in place while also allowing unhindered defecation by the patient.

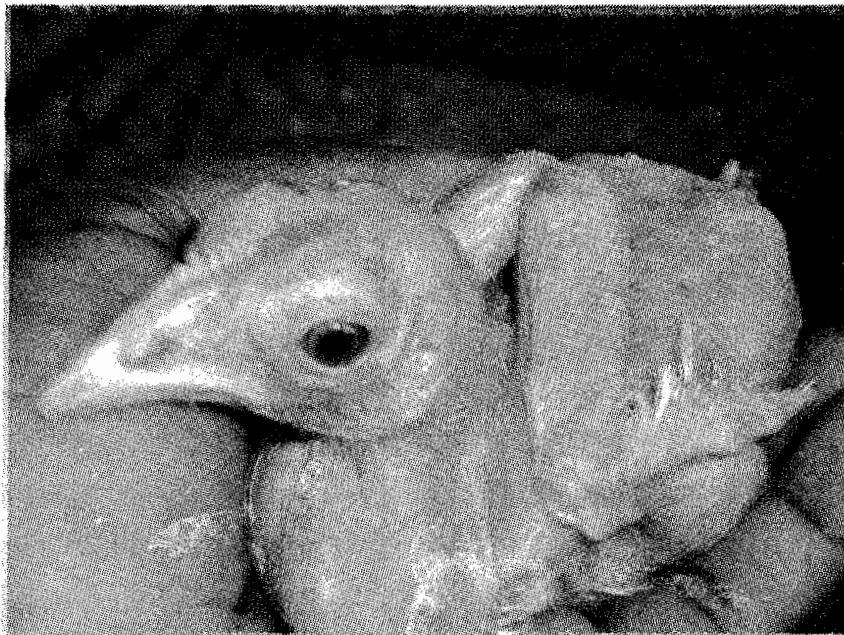### REFERENCES

- AMOUD, W.B. (1974). Non-neurogenic disorders of the anus and rectum. *Vet. Clin. of North America* 4: 535.
- AYEN, E. AND NOAKES, D.E. (1998). Displacement of the tubular genital tract of the ewe during pregnancy. *The veterinary Record*, 141 (20), 509-512.
- AYEN, E., NOAKES, D.E. AND BAKER, S.J. (1998). Changes in the capacity of the vagina and the compliance of the vaginal wall in ovariectomized, normal cyclical and pregnant ewes, before and after treatment with exogenous estradiol progesterone. *Vet. J.* 156: 133.
- BAKER, J.S. (1980). Vaginal prolapse correction during cesarean section in the ewe. *Bovine pract.* 1: 43.
- BOSSE, P., GRIMARD, B., MIALOT, J.P. (1989) *Recueil de Medicine Veterinaire*, 165: 355.
- CLARKSON, M.J. AND FAULL, W.B. (1990) Some Gynaecological Problems near Parturition. A handbook for sheep clinicians. 4<sup>th</sup> edn. Liverpool University press. pp 61.
- CLAUS, D.B. (1997) Diseases of the female Reproductive tract. In: Color Atlas of the Reproductive Pathology of Domestic Animals. Mosby. p. 134.
- COLINS, F.B. AND GARY, V.E. (1989) Recto-anal Diseases. In Textbook of Veterinary Internal Medicine. 3<sup>rd</sup> edn. W.B. Saunders p 1563.
- COX, J.E. (1987) In: Surgery of the Reproductive tract of large animals. 3<sup>rd</sup> edn. Liverpool University Press. pp 129-132.
- EDGAR, D.G. (1952). Vaginal eversion in the pregnant ewe *Vet. Rec.* 64: 852.
- FRANKLIN, J.S. (1986). Vaginal Prolapse. In: Current Therapy in Theriogenology Marrow(Ed). 2<sup>nd</sup> (edn), p.59.

**VET SNAP SHOTS**



**A 10 weeks old featherless local chicken (Cross between a local hen and a white leghorn cock); loved and protected by the whole family.**



**Alert and comfortable**

**Courtesy: Dr. Muhammad Modu Bukar,  
Department of Vet. Surgery and Reproduction  
Faculty of Veterinary Medicine  
University of Maiduguri**