

IBRAHIM et al: Notomelia in a monorchid bull.

MULTIPLE CONGENITAL DEFECTS IN A BUNAJI BULL

IBRAHIM^{1*}, N.D.G., ADAMU¹, S., USEH¹, N.M., SALAMI, S.O², FATIHU¹, M.Y., SAMBO¹, S.J., MOHAMMED¹, B., OJO², S.A. and ESIEVO¹, K.A.N.

¹Department of Veterinary Pathology and Microbiology ²Department of Veterinary Anatomy,
Faculty of Veterinary Medicine, Ahmadu Bello University, Zaria, Nigeria

* Correspondence: Tel +234 806 958 9888

SUMMARY

A congenitally malformed two- and-half year-old bull was acquired from Zaria abattoir for clinical and laboratory investigations. Clinical observations revealed that the bull had kyphoscoliosis and notomelia, with the two extra hind limbs attached to the right lumbosacral aspect, and a common hypoplastic pelvic bone for the extra hindlimbs. The bull had a hypoplastic scrotal sac in-between the extra hindlimbs, with no testicles. There was a fully developed scrotum containing a single testicle (monorchid) between the normal hindlimbs. It had two penises; one fully developed and the other hypoplastic. Each of the penises was within a separate and patent prepuce. There was a fully developed patent anus and an additional atresic anus. It also had double rectum one of which was fully developed, and in continuation with the gastrointestinal tract, while the other was hypoplastic and connected to the atresic anus. There was a single hypertrophied kidney and an abnormal, dorsally attached intrapelvic urinary bladder. In addition, the bull had traumatic reticulitis. The haematological results indicated anaemia and leucocytosis. Serum chemistry analysis revealed normal values of total plasma protein (52.0g/L), alkaline phosphatase (37.0 IU/L), aspartate aminotransferase (29.0 IU/L) and increased levels of blood urea nitrogen (11.8mmol/L) and creatinine(309.4mmol/L); low sodium(118.0mmol/L) and slightly high potassium(5.2mmol/L). It was concluded that these marked abnormalities were relatively incompatible with life and could render the bull unfit for reproduction and breeding.

KEY WORDS: Bull, Notomelia, Kyphoscoliosis, Monorchidism.

INTRODUCTION

Notomelia is a congenital malformation that is characterized by the presence of additional limb(s) attached to the back. According to the manifestations, notomelia can be classified into two groups. One group is characterized by symmetric or asymmetric double malformations (twin malformations) - a partial or total doubling of the axial skeleton. The second group is characterized by limb duplications or multiplication of limbs (Schonfelder et al., 2003; 2004).

Information on the definitive aetiology of duplications is scarce. It is not clear whether these congenital defects are caused by genetic or environmental factors or ageing of ova (Dennis, 1975). However, it is known that the ingestion of teratogenic factors in plants (Keeler, 1972; Jubb et al., 1985), dietary deficiency of manganese and overdose of parabendazole (Jubb and Kennedy, 1970); among others could cause various congenital abnormalities in animals. Causes of notomelia, though not clear, seem to be multifactorial (Schonfelder et al., 2003; 2004).

Limb abnormalities could have a high occurrence rate; up to 29% of calves in a herd had forelimb abnormalities in Australia (Jubb et al., 1985). Here in Zaria, Nigeria, though some cases have been reported (Ojo, 1975; Ibrahim et al., 1987; Ibrahim et al., 1990) several forms of congenital abnormalities still pass unnoticed or are unreported. In this paper we report a rare case of notomelia with multiple congenital defects in a two- and-half year-old Bunaji bull.

CASE HISTORY

The congenitally malformed two-and-half year-old Bunaji bull was purchased from a local market in Anchau, Kaduna State of northern Nigeria by a butcher and was intended for slaughter at Zaria abattoir. On getting to the abattoir, the manager drew our attention to the amazing creature that had become the spectacle of the public. In consideration of the rare nature of the case, we procured this bull for detailed clinical and laboratory investigations. Effort to

get the history of the herd from which the bull came in relation to the occurrence of such abnormality was of little success. This is because the bull had gone through many hands and the original owner could not be traced. It was however gathered that the dam of the malformed bull was disposed off long ago since it gave birth to him at first calving, obviously for superstitious reasons.

On arrival of the bull at the Faculty of Veterinary Medicine, Ahmadu Bello University, Zaria, a detailed physical examination was carried out. Blood samples were collected for haematological and parasitological examinations, and serum chemistry analysis using methods described by Margi (1995). The bull was intended to be used for postgraduate research. Unfortunately few weeks after his arrival, he began to emaciate in spite of adequate feeding until he eventually became completely anorexic. Attempts to diagnose the cause of anorexia and emaciation were unsuccessful as parasitological and microbiological examinations of blood and faeces were negative for any organism. After running an illness that lasted five days, the bull eventually died. A detailed postmortem examination was carried out on the carcass.

RESULTS

On physical examination, the bull had notomelia characterized by presence of two additional; albeit hypostatic, hindlimbs attached to the right lumbosacral region. There were fully developed normal fore and hind limbs (two in each case). The bull was a monorchid with a hypoplastic scrotal sac devoid of palpable testicle located at a point between the extra hindlimbs and a second fully developed scrotum that contained the fully developed testicle. The bull had two prepuces, which were adjacent to each other, and each had a patent prepuccial orifice (Plates 1 and 2).

The bull had a fully developed penis that was protruding and retracting through the left prepuccial orifice, while the second penis on the right side was hypoplastic and palpable in the right prepuce. There was a well-developed but deviated tail that extended from the sacral bone at the point of attachment of the extra hindlimbs to the level of the hock joint. The bull also had a

IBRAHIM et al: Notomelia in a monorchid bull.

well-developed patent anus at the posterior lateral region of the right hindlimb. An extra rudimentary atresic anus was found between the extra hindlimbs. Each of the two additional hindlimbs had femur, tibia, patella, tarsal and metatarsal bones, hooves and the associated joints of the hindlimbs (Plates 1, 2 and 3).

Postmortem examination revealed that the bull had kyphosis from the 1st to the 9th thoracic vertebrae and scoliosis that involved the lumbar vertebrae. The tuber coxae of the bull were asymmetric; the right tuber coxa measured 3.5cm by 4.0cm, while the left one measured 2.8cm by 7.5cm. The extra hindlimbs were attached to the lumbosacral region by hypoplastic pelvic bones and muscles. The shafts of the hypoplastic ilia, tuber coxae and the heads of the femurs of the two additional hindlimbs were attached to the right ilium and tuber coxae. The left extra hindlimb was attached to the right extra hindlimb at the ischium and the tuber ischii of the two extra hindlimbs caudal to the hypoplastic obturator foramen through which the sciatic nerve that supplied the additional limbs passed. The muscles of the additional hindlimbs were hypoplastic. The origin of the extra hypoplastic penis was at the point where the two extra hindlimbs joined. There were two recta; one was fully developed as a

continuation of the gastrointestinal tract and led directly to the patent anus. The second rectum was hypoplastic and located between the aponeurosis of the abdominal muscles and the atresic anus that was between the extra hindlimbs (Fig. 3). The bull also had a single hypertrophied kidney that measured 7.0cm by 16cm. There was an intrapelvic urinary bladder that was attached to the pelvic cavity, dorsally. The inlet to the pelvic cavity measured 7.0cm by 10cm. Other postmortem findings were subcutaneous oedema, hydrothorax, congested lungs, hypertrophied heart and traumatic reticulitis due to an ingestion of a sewing machine needle, which was finally diagnosed to be the cause of death of the bull.

Results of serum chemistry and haematological analyses were as presented in tables I and II, respectively. The results of serum chemistry analysis indicated normal values of the total plasma protein (52.0 g/L), alkaline phosphatase (37.0 IU/L), and alanine (7.1 IU/L) and aspartate aminotransferases (29.0 IU/L) activities. Values of blood urea nitrogen and creatinine (11.8 mmol/L and 309.4 mmol/L respectively) were high. Most haematological values were normal except for

TABLE I: Serum chemistry tests results on the 1st and 2nd days of sampling

Parameter	Day 1	Day 2
Total protein (g/L)	68.0	52.0
Alkaline phosphatase (I U/L)	32.0	37.0
ALT (I U/L)	6.8	7.1
AST (I U/L)	26.0	29.0
BUN (mmol/L)	11.1	11.8
Creatinine (mmol/L)	318.2	309.4
Sodium (mmol/L)	126.0	118.0
Potassium (mmol/L)	5.4	5.2
Chloride (mmol/L)	108.0	122.0

TABLE II: Results of haematological analysis on the 1st and 2nd days of sampling

Parameter	Day 1	Day 2
PCV (%)	22.0	15.0
WBC($\times 10^9/L$)	9.3	14.0
RBC($\times 10^{12}/L$)	3.8	3.1
Neutrophils (%)	37.0	41.0
Lymphocytes (%)	54.0	58.0
Monocytes (%)	3.0	1.0
Eosinophils (%)	5.0	1.0
Basophils (%)	0.0	0.0
Band (%)	1.0	0.0




Plate 1: Photograph of the bull with notomelia. Note the two extra hindlimbs (black arrows), the deviated tail (white arrow) and a normal patent anus adjacent to the tail on left and a hidden atresia ani beneath the tail.




Plate 2: Photograph of the bull with notomelia. Note that the two extra hindlimbs were attached to the lumbosacral region on the right.

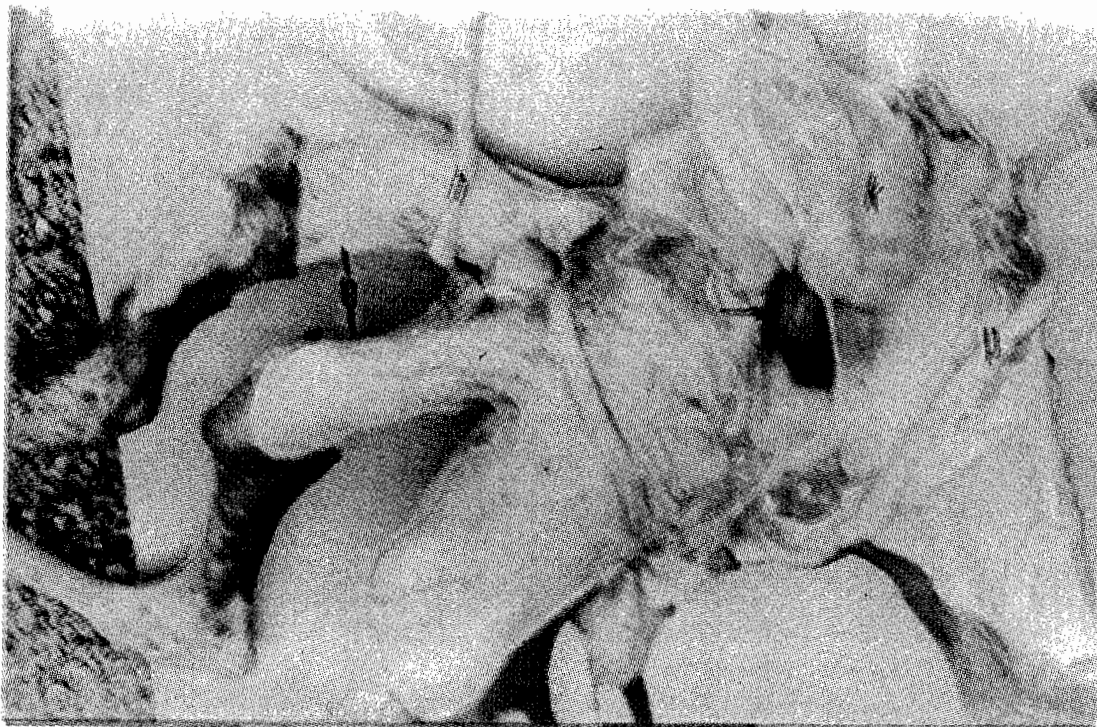

Plate 3: Note the extra hindlimbs (e), the developed penis (p), the hypoplastic penis (h), the hypertrophied common kidney (k) and the dorsally attached intrapelvic urinary bladder (arrow) of the bull.

DISCUSSION

Anomalous duplications such as notomelia, polymelia and anomalous twins have always stimulated curiosity. Notomelia is regarded as non-inherited and is quite common among congenital malformations in the bovine species (Schonfelder et al., 2003; 2004). The presence of two extra hindlimbs observed in this investigation differs from that of Patricia and Woolcock (1965) who reported that, 34 cows of mixed ages and breeding had 10 (29%) calves with Amelia or polymelia but with normal hindlimbs. The affected calves, in their study, had no other observable congenital abnormalities of the skull, brain, thorax, pelvis, hindlimbs or internal organs. Our observation, however, showed notomelia characterized by the presence of two extra hindlimbs on the back, in association with other malformations like the pelvic deformities, a single hypertrophied kidney and a dorsally attached intrapelvic urinary bladder. Such abnormalities were similarly observed to be associated with atresia ani (Kenawy and Kassem, 1992)

Embryonic and anomalous duplications are important because they are usually associated with dystocia and reproductive wastage, but usually incompletely investigated. Despite the fact that these congenital malformations generate interest and curiosity, there is little information on the exact causes as to whether they are environmentally or genetically induced or both (Dennis, 1975). Recent reports by Schonfelder et al. (2003; 2004) indicated that the exact aetiologies of polymelia have not been clearly identified, but they seem to be multifactorial and that dispersing of germinal cells or prior splitting of the embryo have to be considered as possible causes of a simple doubling of limbs (polymelia), while asymmetric twins malformations are considered to be the result of viral infections, toxins and over ripe oocytes.

Outbreaks of systemic skeletal deformities in calves were attributed to teratogenic factors in the plants consumed by the dams (Keeler, 1972; Jubb et al., 1985). For example, it was reported that ingestion of teratogenic plant, *Veratrum californicum* by pregnant cows between days 30 and 36 of gestation resulted in selective inhibition of growth in the length of the

metacarpal and metatarsal bones. Other plants such as *Cornium maculatum* and *Nicotiana glauca* were also reported to cause similar syndrome in calves. Similarly, crooked calf disease was reproduced by feeding pregnant cows with certain wild lupines (*Lupinus* species) especially between days 40 and 70 of gestation (Jubb et al., 1985).

Also, deficiency of manganese in feeds (115mg to 123mg instead of the required 183mg per day) fed to pregnant cows resulted in calving of offspring with deformed limbs that had reduced length of humerus, enlarged joints and twisted legs. The deficiency was attributed to lack of or significantly reduced manganese in the soil, the plant, and the water or due to poor absorption and utilization in the body (Jubb et al., 1985). Overdose of parabendazole between days 12 and 24 of gestation in ewes had caused skeletal abnormalities in limbs (Jubb et al., 1985). Although the cause of the abnormalities in this bull was not investigated, considering the open nature of grazing and the management practices in the area where this notomelic bull was raised, it may be possible that aetiologic agent of plant origin or irrational use of chemotherapeutic agents such as parabendazole or a dietary manganese deficiency, were involved.

Variable degrees of defects were reported to have occurred in calves (Green et al., 1974; Orr and Mackenzie, 1981; Jubb et al., 1985). The observed skeletal deformities in the present report, which include kyphosis, scoliosis and hypoplastic structures like pelvic bones, shafts of the ilia, tuber coxae and femoral heads and the deviated coccygeal bones, were marked. These could have possibly affected the reproductive capacity and could have affected the lifespan of the bull.

The high values of blood urea nitrogen (BUN), creatinine and potassium may suggest renal insufficiency (Bush, 1993; Margi, 1995). The increase in values of BUN and creatinine may be attributable to the presence of a single kidney as opposed to two in normal animals. Even though the single kidney was enlarged, it may not be able to meet the desired normal function of excreting BUN and creatinine from the body of this animal. The low value of sodium and the slightly high level of potassium suggested impairment or reduced ability of the kidney to retain and excrete the sodium and potassium, respectively. These

IBRAHIM et al: Notomelia in a monorchid bull.

findings could also be attributable to the presence of a single kidney. The low total plasma protein value on the day the animal died may be due to loss of protein in exudative inflammation as a consequence of the traumatic reticulitis or, perhaps, impaired ability of the liver to synthesize normal levels of the plasma protein due to severe anaemia, hypoxic injury (Bush, 1993). The moderate leucocytosis just before the bull died could be attributable to traumatic reticulitis and, probably, the severe anaemia.

CONCLUSION

In conclusion, the congenital defects observed in this bull were severe, and could result in impairment of its normal reproductive capacity and render it unfit for breeding. Traumatic reticulitis was the most likely cause of death of this animal.

REFERENCES

- BUSH, B.M. (1993): Plasma biochemistry In: Interpretation of Laboratory Results For Small Animal Clinicians. Blackwell Scientific Publications, London. pp 221-360.
- DENNIS, S.M. (1975): Embryonic duplication in sheep. *Austr. Vet. J.*, 51: 83-87.
- GREEN, H.J., LEIPOLD, H.W., HIBBS, C.M. and KIRKBRIDE, C.A. (1974): Congenital osteoporosis in Angus calves. *J. Am. Vet. Med. Assoc.*, 164: 389-395.
- IBRAHIM, N.D.G., GIANG, E.O., and NJOKU, C.O. (1987). Multiple congenital malformations associated with incomplete twinning in Yankassa sheep. *Zar. Vet.*, 2:81-83.
- IBRAHIM, N.D.G., SAIDU, S.N.A., and NJOKU, C.O. (1990). Monocephalus dipygus twins in Sokoto Red goat. *Zar. Vet.*, 5:107-109.
- JUBB, K.V.F. and KENNEDY, P.C. (1970): Pathology of Domestic Animals. Second Edition, Vol. 1 published by Academic Press Inc., Orlando, Florida and the Academic Press Inc. London. Pp16-32.
- JUBB, K.V.F., KENNEDY, P.C. and PALMER, N. (1985): Pathology of Domestic Animals. Third Edition, Vol. 1 published by Academic Press Inc., Orlando, Florida and the Academic Press Inc. London. Pp16-32.
- KEELER, R. F. (1972): Effects of natural teratogenic and poisonous plants on fetal development in animals. *Adv. Exp. Med. Biol.*, 27: 107-125.
- KENAWY, A.A. and KASSEM, M.M. (1992): Some congenital anomalies in newborn calves. *Ass. Vet. Med. J.*, 26: 356.
- MARGI, S. (1995): Blood Chemistry In: Veterinary Laboratory Procedures. Mosby, Philadelphia. pp 101-121.
- OJO, S.A. (1975). Studies on bovine congenital defects. An MSc. thesis, Ahmadu Bello University, Zaria, Nigeria. Pp 1-197.
- ORR, J.P. and MACKENZIE, G.C. (1981): Unusual skeletal deformities in calves in a Sas Katcheran beef herd. *Can. Vet. J.*, 22: 121-125.
- PATRICIA, R.H. and WOOLCOCK, J.B. (1965): Congenital forelimbs anomalies in calves. *Austr. Vet. J.*, 41:173-177.
- SCHONFELDER, A., WITTEK, T. and SOBIRAJ, A. (2003): Polymelia in calves- a case review including surgical correction. Heft 6 2003-Schattauer GmbH - Naturwissenschaften, 6: 1-2.
- SCHONFELDER, A., LUDEWIG, E. and SOBIRAJ, A. (2004): Polymelia beim kalb-ein Fallbericht. *WTM 08/2004 Kurzübersicht*. P1.