

TOXICITY STUDIES ON THE METHANOLIC EXTRACT OF THE LEAVES OF *Cassia tora* LINN IN MICE

<sup>1</sup>AMBALI, S.F., <sup>1</sup>SILAS, A., <sup>1</sup>AYO, J.O., <sup>2</sup>IBRAHIM, N.D.G. <sup>3</sup>OBALOWU, A.A. AND <sup>4</sup>SALAMI, S.O.

<sup>1</sup>DEPARTMENT OF VETERINARY PHYSIOLOGY AND PHARMACOLOGY

<sup>2</sup>DEPARTMENT OF VETERINARY PATHOLOGY AND MICROBIOLOGY

<sup>3</sup>DEPARTMENT OF ANIMAL SCIENCE

<sup>4</sup>DEPARTMENT OF VETERINARY ANATOMY

AHMADU BELLO UNIVERSITY, ZARIA, NIGERIA.

\*Corresponding Author: [fambali2001@yahoo.com](mailto:fambali2001@yahoo.com)  
elephone No- 234 -803 7015411

SUMMARY

Methanolic extract of *Cassia tora* was evaluated for its acute and subacute toxicity in mice. The extract induced excitement, restlessness and depression following its acute administration to three groups of 3 mice each orally at 100 mg/kg, 1000 mg/kg and 10,000 mg/kg, respectively. Death did not occur in any of the mice dosed with the extract at this dose range. This shows that the plant was not acutely lethal to mice when administered orally. The oral LD<sub>50</sub> could not be determined because no death occurred in mice dosed with the extract even at the highest dose of 20,000 mg/kg. However, in the subacute study, the extract, administered orally to mice for four weeks, caused severe clinical and pathological lesions, and even death. This indicates that *C. tora* can cause widespread organ damage and death following prolonged administration. In conclusion, it is advised that caution should be exercised during prolong administration of *C. Tora*.

## INTRODUCTION

*Cassia tora* Linn is an under shrub widely used by the folks in the treatment of various ailments. All parts of the plant are used as anthelmintics and purgatives. The fresh leaves or roots or the pulverized seed mixed with lime juice are used to treat ringworm and some other pruritic conditions of the skin, while the powdered dried leaves are applied to ulcers and parasitic skin conditions (Dalziel, 1937). The seed of *C. tora* is used in Chinese herbal medicine to improve vision, and is reputed to be of medicinal value as an aperient, antiasthenic, diuretic, tonic and laxatives (Namba, 1980). Modern Chinese physicians used *C. tora* to treat hypercholesterolemia and hypertension (Yen *et al.*, 1998). The methanolic extract of the plant has been shown to exert antioxidant activities (Kim *et al.*, 1994; Choi *et al.*, 1995). Close relationship has been shown to exist between antioxidant properties of the plant and its mutagenicity (Yen *et al.*, 1998).

The active principles in *C. tora* have been shown to include phenolic compounds anthraquinones such as emodin, aloemodin, chrysarobin, anthrone, hydroxyemodin (alaternin), cassiaside, rubrofusarin gentobioside, rhein, and obtusifolin (Duke, 1992; Huang, 1993; Choi *et al.*, 1995).

Apart from its medicinal value, the seed of *C. tora* is used as famine food, while its young leaves can be used as vegetable in soup. The roasted seed when grounded is used as a coffee substitute (Dalziel, 1937). In addition, *C. tora* is found in abundance in the environment where it persists to dry season, hence its availability for foraging by livestock. Therefore, from the foregoing, there is the need to evaluate the toxicity of *C. tora*. This study was aimed at evaluating the acute and subacute toxic effects of *C. tora* in mice.

## MATERIALS AND METHODS

### Plant Collection, Extraction and Preparation

The leaves of *C. tora* used for this study were collected from the wild in Zaria, Nigeria.

They were identified at the herbarium of the Department of Biological Sciences, Ahmadu Bello University, Zaria, air-dried, powdered and stored in air tight container before use. The powdered material was then weighed and macerated in methanol at a ratio of 1:5 w/v for 24 h. Thereafter, the mixture was filtered and the filtrate concentrated *in-vacuo* at 50 °C in a rotary evaporator coupled to a thermocirculator. The semi-solid extract obtained (referred to as extract) was weighed and then stored in a refrigerator at 4°C until required for use. Prior to use, the extract was reconstituted in distilled water to obtain 1% stock solution, which was subsequently used for the study.

### Experimental Animals

Locally bred Swiss albino mice of both sexes obtained from Department of Veterinary Physiology and Pharmacology, Ahmadu Bello University, Zaria, Nigeria were used for the study. The animals were housed under standard condition in the animal room of the Department. They were fed on mice pellets made from chick mash, maize bran and groundnut cake at a ratio of 4:2:1., and water was provided *ad libitum*.

### Acute Toxicity Study

Twelve mice were weighed and randomly assigned to 4 groups of 3 mice each (n=3) 12 hours prior to the commencement of the study. The mice in group 1 were dosed orally with 100mg/kg of the reconstituted extract. Those in groups 2 and 3 were dosed orally at 1,000 mg/kg and 10,000 mg/kg respectively with the reconstituted stock solution of the extract. Mice in group 4 (control) were given distilled water orally. Signs of toxicity and death were monitored for 48 hours and subsequently over a 14-day post-dosing period. The mice were euthanized in a chloroform chamber and gross pathologic examination conducted at the end of the observation period. Sections of tissues such as lung, kidney, spleen, liver, small intestine, thigh muscle and heart were obtained for histopathological processing as described by Luna (1962), and subsequently examined by light microscopy.

### Determination of Median Lethal Dose (LD<sub>50</sub>)

Based on the result of the acute toxicity study, three groups of 3 mice each were dosed orally with the methanolic extract of *C. tora* at a dose of 10,000 mg/kg, 15,000 mg/kg and 20,000 mg/kg respectively. Death was monitored over a period of 24 hours. LD<sub>50</sub> was then determined using the method of Lorke (1983).

### Subacute Toxicity Study

Two groups of 10 mice each were dosed orally at 500 mg/kg and 1000 mg/kg with the extract respectively, while the third group of 10 mice, which served as control was given distilled water orally. All the animals were dosed daily for 4 weeks. Signs of toxicity and death were observed during this period. Gross and histopathological post- mortem examinations were carried out on dead mice during the period of study, and on survivors euthanized at the end of the study.

## RESULTS

### Acute Toxicity Study

Clinical signs of toxicity observed in all cases included initial excitement, restlessness and then followed by prolong depression. Complete recovery occurred in all the test animals after 26 hours post administration of the extract. No other clinical signs or deaths were observed throughout the 14-day period of observation. However, the severity of the clinical signs observed was dose dependent.

Postmortem lesions observed were enlargement and congestion of the heart, congested liver, kidneys and lungs. The histopathological lesions observed included fatty degeneration, dilated sinusoidal space and diffuse necrosis of the hepatic cells with mononuclear cellular infiltration in the liver (Fig 1), and in the heart were area of necrosis and mononuclear cellular infiltration. In the kidneys were necrosis of the glomeruli, proximal and distal convoluted tubules and collecting ducts, renal cast with

periglomerular and inter-tubular mononuclear cellular infiltration. The lung showed thickened inter-alveolar septae, mononuclear cellular infiltration and hemosiderosis.

### Determination of LD<sub>50</sub>

Median lethal dose (LD<sub>50</sub>) could not be determined because no death was recorded in all the three groups of mice at the dose levels of 10,000 mg/kg, 15,000 mg/kg and 20,000 mg/kg.

### Subacute Toxicity Study

The initial signs of toxicity seen included initial restlessness, excitement and then depression. Other signs of toxicity observed were diarrhea, rough hair coat, poor body condition, bleeding from penile orifices and intermittent convulsion, which preceded death in some mice. There were congestion of the mucous membrane of the conjunctiva, and unilateral or bilateral seromucous ocular discharges observed in some mice progressed to total or partial blindness as accessed using the functional observation battery. The limbs and paws of some mice were swollen, with mucous discharges. Microbial culture and examination of the mucous discharges show the presence of *Escherichia coli* and *Proteus species*. The animals also showed an increase in dose-response pattern in mortality (Table 1).

Gross post-mortem lesions observed included hemorrhage of the lungs and spleen, congestion and hemorrhage of the thigh muscles and liver, congested kidneys and enlargement of the heart and thyroid glands. Histopathological findings included congestion and focal necrosis of the hepatocytes, while the thyroid gland has areas of diffuse necrosis of the epithelial lining of the thyroid follicle with mononuclear cellular infiltration (Fig 2). The kidneys were congested with areas of focal necrosis and cast observed in the proximal and distal convoluted tubules. In the brain, there were microabscess and liquefactive necrosis of the cerebral cortex with mononuclear cellular infiltration (Fig 3). The heart was congested with degenerated myocytes, and there was also congestion of the spleen.

## DISCUSSION

The methanolic extract of *C. tora* administered orally at a dose range of 100-20,000 mg/kg did not cause death of any of the mice. This apparently shows the low acute toxicity of the extract even though varying degree of clinical signs and pathologic lesions were observed in the animals, which indicates that the toxin did not have its toxicity restricted to any organ or tissue, but causes generalized tissue damage.

Although the active principles of the extract were not isolated in the present study, *C. tora* has been shown to contain phenolic compounds, anthraquinones that have both pro-oxidant and antioxidant effects on the body. The latter effect results in the protection of tissues and organs, while the former on the other hand causes widespread damage to tissues and organs. Many studies have shown that several phenolic antioxidants can also cause oxidative damage *in vitro* to DNA, proteins and carbohydrate despite their antioxidant effect on lipids (Laughton *et al.*, 1989; Yen and Chuang, 1999). In addition, emodin, an anthraquinone from *C. tora*, has been shown to produce free radicals and hydrogen peroxide during its oxidation to semiquinone in the body (Huang *et al.*, 1992). However, this pro-oxidative damage apparently may be related to the dose and duration of administration of the extract. Furthermore, certain antioxidants like ascorbic acid and indomethacin exhibit either antioxidant or pro-oxidant activities when administered at higher dose (Seifulla and Borisova, 1990).

The oral LD<sub>50</sub> of the extract of *C. tora* could not be determined, indicating that the plant is not acutely lethal. This finding agreed with earlier studies in rats where LD<sub>50</sub> for this plant could not be determined (Kadiri *et al.*, 1996; Chidume *et al.*, 2000). However, when administered continuously over a period of 4 weeks, the extract was found to cause various degrees of toxic signs, pathologic lesions and even death in mice. Diarrhea observed in a few mice has also been observed in rats fed with the seeds of the plant (Vess and Brennecko, 1991). The diarrhea may be due to the irritant effects of the anthraquinone content of the plant (Knight and Walter, 2004). The apparent blindness

observed in some mice may be due to peroxidative damage to the membrane of the retina and other sensitive portion of the eyes. This finding contradicts the traditional use of the seeds of *C. tora* in China to improve visual acuity (Yen and Chuang, 1999), even though leaf extract and not the seed were used in the present study. The protective antioxidant effect of the seed extract on the eyes may be related to the dose and duration of administration. However, it is possible that the leave of this plant contain additional compounds not found in the seeds, which may have contributed to the visual impairment.

Congestion and hemorrhage of skeletal muscle of thigh observed grossly indicate that the plant causes some degree of damage to it, even though no significant pathology was observed at histopathology. *C. occidentalis* has been reported to cause muscle damage in ruminants (O'Hara *et al.*, 1969). Other *Cassia* species such as *Cassia roemeriana* have also been shown to cause muscle damage in sheep and goats (Rowe *et al.*, 1987; Rowe, 1991). The toxin responsible for muscle degeneration in cassia poisoning has not yet been identified (Herbert *et al.*, 1983), although lipid peroxidation may be implicated. The swellings observed in the extremities may also be due to the peroxidative damage on the capillary membrane, thereby allowing leakage of the extracellular fluid into the interstitial spaces. In addition, the swellings may also result from the vasodilatory action of the anthraquinone contents of the plant (Huang *et al.*, 1992). Bleeding from the penile orifices may be due to the effect of some polyphenolic contents of the plants on platelet aggregation (Benavente-Garcisa *et al.*, 1997). The encephalitis observed may be due to peroxidative damage to the brain and subsequent secondary bacterial infection. The microabscess in the brain and widespread mucous discharges in many organs strongly suggest that prolong use of the plant may have immunosuppressive action, thereby enhancing bacterial infection. Indeed, emodin, an anthraquinones content of the plant has been shown to be immunosuppressive (Huang *et al.*, 1992). The enlargement and severe necrosis of the thyroid gland may be due to the widespread peroxidative damage caused by the active

## AMBALI et al: TOXICITY OF *Cassia tora* LEAVES IN MICE

constituents of this plant. Perhaps the use of the plant in Chinese medicine for the treatment of hypercholesterolemia and as herbal slimmer may reflect its effect on the thyroid gland. However, the severe pathology in the thyroid gland may be related to the dose and duration of the administration of the extract.

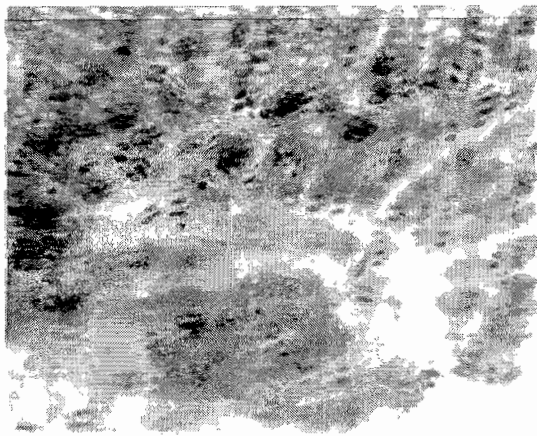
In conclusion, this study has shown that acute administration of the plant may be safe since its LD<sub>50</sub> could not be determined at different dosages given, even though varying degree of toxic manifestations were observed. However, prolonged administration of the plant causes severe clinical and pathological lesions, and death. Therefore, extreme caution should be exercised during prolong use of this plant as observed in some traditional practices.

It is therefore, recommended that further studies should be done to elucidate the pathophysiologic mechanism underlying the deleterious effects of the active compounds contained in the extract. This may open up a new insight into the development of possible

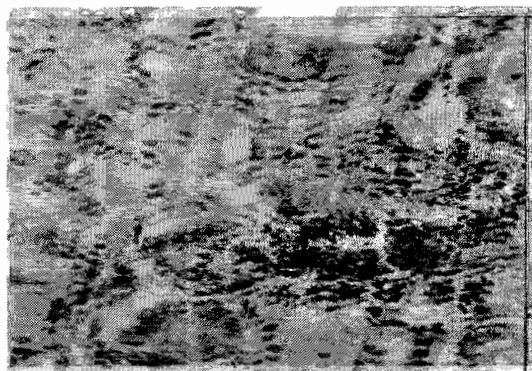
antidotes in cases of toxicity caused by prolong administration of the plants in man and animals.

**Table I: Result of dose-response pattern in mortality following subacute toxicity in mice dosed orally with the methanolic extract of *C. Tora***


with the methanolic extract of <i>C. tora</i>		
Dose of extract (mg/kg)	<u>Mice</u> No dosed No dead	% mortality
500	10 3	30
1000	10 4	40
Control (distilled water)	10 0	0



**Plate 1: fatty degeneration, necrosis of the hepatocytes and dilated sinusoids H&E X400.**



**Plate 2: Thyroid gland of mice dosed for four weeks with methanolic extract of *C. tora*. Note diffuse necrosis of the thyroid follicles with mononuclear cellular infiltrations. H&E x400**



**Figure 3: Cerebral cortex of mice treated for four weeks with methanolic extract of *C. tora* Note liquefactive necrosis with microabscess of the cerebral cortex and mononuclear cellular infiltration. H&E x400**

## AMBALI et al: TOXICITY OF *Cassia tora* LEAVES IN MICE

### REFERENCES

- BENAVANTE-GARCISA, O., CASTILLO, J., MARIN, F.R., ORTUNO, A. and RIO, J.A.D. (1997): Use and properties of *Citrus* flavonoids. *J. Agric. Food. Chem.*, **45**: 4505-4515.
- CHIDUME, F.C; KWANASHIE, H.O., GAMANIEL, K.S. and ADEKEYE, J.O. (2000): Acute toxicity, analgesic and smooth muscle contracting effects of the methanolic extract of *Cassia tora* leaf. International Ethnoveterinary Workshop, Kaduna, Nigeria., 14-18<sup>th</sup> August 2000.
- CHOI, J.S., JANG J.H., LEE, H.J. and KANG, S.K. (1995): A naphthalene glucoside from *Cassia tora*. *Phytochem.*, **40**(3): 997-999.
- DALZIEL, J.M. (1937): The Useful Plants of West Tropical Africa. Crown Agents. London; 612.
- DUKE, J.A. (1992): Handbook of Phytochemical Constituents of Grass, Herbs and Other Economic Plants. C.R.C. Press. Boca Raton, FL; 143-144.
- HEBERT, C.D., FLORY, W., SEGER, C. and BLANCHARD, R.E (1983): Preliminary isolation of a myo-degenerative toxic principle from *Cassia occidentalis*. *Am. J. Vet. Res.*, **44**: 1370-1374.
- HUANG, H.C., CHANG, J.H., TUNG, S.F., WU, R.T. and FOEGH, M.L. (1992): Immunosuppressive effect of emodin, a free radical generator. *Eur. J. Pharmacol.*, **211**: 359-364.
- H U A N G , K . C . ( 1 9 9 3 ) : Antihypercholesterolemic herbs. In: The Pharmacology of Chinese Herbs. C.R.C. Pres: Boca Raton, FL; 103.
- KADIRI, M., BEDRI, B.A. and AJAO, S.S. (1996): Toxicological screening of some Nigerian wild legumes. *Rev. de Biol. Trop.*, **44**: 269-274.
- KIM, S.Y. KIM, J.H., KIM, S.K., OH, M.J., and JUNG, M.Y. (1994): Antioxidant activities of selected oriental herb extracts. *J. Am. Oil. Chem. Soc.*, **171**: 633-640.
- KNIGHT, A.P. and WALTER, R.G. (2004): Plants Affecting the Musculoskeletal System. In: A Guide to Plant Poisoning in Animals in North America. Teton Neomed, Jackson, WY. Internet publisher: International Veterinary Information Service ([www.ivis.org](http://www.ivis.org)) Ithaka, NY. Last updated 2<sup>nd</sup> April 2004.
- LAUGHTON, M.J., HALLIWELL, B., EVANS, P.J. and HOULTS, J.R.S. (1989): Antioxidant and pro-oxidant action of plant phenolics quercetin, gossypol, and myricetin. *Biochem. Pharmacol.*, **38**: 2859-2865.
- LORKE, D. (1983): A New Approach to practical acute toxicity testing. *Arch. Toxicol.*, **54**: 275-287.
- LUNA, L.G. (1962): Manual of Histologic Staining Methods of the Armed Forces Institute of Pathology 3<sup>rd</sup> Ed. McGraw-Hill Book Company; 32-37.
- NAMBA. T. (1980): Coloured Illustration of Wakanyaku. Vol.1. Hoikusha Publishing Co. Japan; 226.
- O'HARA, P.J., PIERCE, K.R. and REID W.K. (1969): Degenerative myopathy associated with ingestion of *Cassia occidentalis*: clinical and pathologic features of the experimentally induced disease. *Am. J. Vet. Res.*, **30**: 2173-2180.
- ROWE, L.D., CORRIER, D.E., REAGOR, J.C. and JONES, L.P. (1987). Experimentally induced *Cassia roemeriana* poisoning in cattle and goats. *Am. J. Vet. Res.*, **48**: 992-997.
- ROWE L.D. (1991): Cassia-induced

myopathy. In: Handbook of Natural Toxins. Toxicology of Plant and Fungal Toxins. R.F. Keeler and A.T. Tu, Eds.: Marcel Dekker: New York; 335-351.

SEIFULLA, R.D. and BORISOVA, I.G. (1990): Problems of antioxidant in pharmacology. *Pharmacol. Toxicol.*, **53**: 3-10 (in Russian).

YEN, G.C. and CHUNG, D.Y. (1999): Antioxidant effect of extracts from *Cassia tora* L. prepared under different degree of roasting on the oxidative damage to biomolecules. *J. Agric. Food Chem.*, **47**: 1326-1332.

YEN, G.C., CHEN, H.W. and DUH, P.D.

(1998): Extraction and identification of an Antioxidative component from Jue Ming Zi (*Cassia tora* L.). *J. Agric. Food Chem.*, **46**: 820-824.

VESS, K.A. and BRENNECKO, L.H. (1991): Toxicological and Hematological effects of sicklepod (*Cassia obtusifolia*) seeds in Sprague-Dawley rats- a subchronic feeding study. *Toxicol.*, **29** (11): 1329-1336.