

THE EFFECTS OF LACTOSE INFUSION ON THE PATHOLOGICAL
MANIFESTATIONS OF *Trypanosoma vivax* INFECTION IN CATTLE

IBRAHIM^{a*}, N.D.G., ESIEVO^a, K.A.N. AND UMAR^b, I.A.

^aDepartment of Veterinary Pathology and Microbiology
Faculty of Veterinary Medicine,
Ahmadu Bello University, Zaria, Nigeria

^bDepartment of Biochemistry,
University of Maiduguri,
Maiduguri, Borno State, Nigeria

*Correspondence

SUMMARY

Except for 4 control calves, 8 calves were experimentally infected using 11×10^6 *T. vivax* Trypanosomes, intravenously, as a source of neuraminidase. At the peak of parasitaemia, lactose was intravenously infused at the rate of 0.5g kg⁻¹ body weight into 4 of the infected calves, to inhibit the binding of desialylated erythrocytes to kupffer cells (macrophages), and therefore, subsequent erythrophagocytosis. This resulted in amelioration of the anaemia in the 4 infected, lactose infused calves which showed no gross lesions except for mild anaemia and emaciation. In contrast, the other 4 infected, non-lactose infused calves had marked anaemia. The mean PCV values were higher in the infected infused calves and the mean PCV values were lower in the infected uninfused calves, with a statistically significant difference ($P < 0.05$). The 4 infected, lactose infused calves showed no gross lesions except for mild anaemia and emaciation. The major gross lesions observed in the infected non-lactose infused calves included rough hair coat, emaciated carcasses, serous atrophy of coronary fat, enlarged oedematous lymph nodes, and hepato-splenomegaly. Two calves each from the infected lactose infused and non-lactose infused groups and one of the control calves were sacrificed for pathological examinations. Histopathological lesions in the infected-lactose-infused calves were narrow hepatic sinusoidal spaces, enlarged Bowman's spaces, hypercellular renal glomeruli, and a less dense lymphoid hyperplasia (proliferation of lymphocytes) in the spleen and lymph nodes compared to the infected-non-lactose infused calves. No significant histopathological changes occurred in the heart, lung, and intestine of the infected-lactose infused calves. In the infected-non-lactose-infused calves there were diffuse hepatic necrosis and erythrophagia by Kupffer cells, dense lymphoid hyperplasia (active lymphoid follicles with plasma cells), and haemosiderosis. There were haemosiderin laden macrophages in the spleen, liver, kidney, and lymph node. Hypercellular glomeruli, necrosis of the proximal, distal and collecting tubules of the kidney with periglomerular and inter-tubular mononuclear cellular infiltration. There was minimal myocarditis, while the brain, lung and the intestine of the calves had no significant histopathological lesions. No significant microscopic lesions were observed in the liver, kidney, lung, heart, spleen, lymph node, brain, and the intestine of the control calf examined. The results of this study have shown that lactose plays a vital role in the prevention or amelioration of tissue injury and cellular reactions in various organs of the body during the course of bovine trypanosomiasis. The finding further supports the safety use of lactose without causing any damage to body organs. As such, its incorporation with other chemotherapeutic agents for treatment of trypanosomiasis is, therefore strongly recommended.

KEY WORDS: *Trypanosoma vivax*, cattle, lactose infusion, lectin, erythrophagocytosis, anaemia

INTRODUCTION

Despite the fact that *T. vivax* infection had long constituted a major component in poor production and losses in cattle in West Africa (Edward *et al.*, 1956). The pathogenesis and pathology of trypanosomiasis in cattle have remained the subject of intensive investigations (Saror, 1980). A principal pathological feature of trypanosomiasis is anaemia. Experimental evidence indicates that the anaemia is haemolytic in nature and that the haemolysis occurs principally extravascularly in expanded mononuclear phagocytic system (Fiennes, 1970; Naylor, 1971; Losos and Ikede, 1972; Saror, 1975; Van Den Ingh *et al.*, 1976). The phenomenon of erythrophagocytosis as a contributing factor to the anaemia is well documented (Mackenzie and Kruickshank, 1973; Esiebo *et al.*, 1982; Esiebo and Saror, 1991). Binding between demasked erythrocyte surface β -galactosyl residues, to the lectin on the macrophage cell membrane is necessary for erythrophagocytosis (Muller *et al.*, 1981; Muller and Schauer, 1983). The binding can be inhibited by β -D-galactosyl containing glycoproteins including lactose (Kolb and Kolb-Bachofen, 1978; Muller *et al.*, 1981; Muller and Schauer, 1983) and such inhibition has been experimentally produced with lactose in animal trypanosomiasis (Ibrahim, 1997). Recent information indicates that lactose has the potential of serving as a base for trypanocidal agents in eradication or control of animal trypanosomiasis (Ibrahim, 1997). This paper reports the role of lactose infusion on the pathological manifestations of *T. Vivax* infection in cattle.

MATERIALS AND METHODS

The parasite

Trypanosoma vivax (Samaru stock) was obtained from a cow with natural infection. Two milliliter of the infected blood from the cow was used to infect a goat that served as donor animal. At the first peak of parasitaemia the blood of the donor goat was used to infect the calves experimentally.

The experimental animals

Twelve Sokoto gudali calves, aged between 12 and 18 months and between 80 and 90kg body weight were purchased from Talatan-Mafara, Sokoto State, Nigeria, an area known to be tsetse-fly free. On arrival in Zaria, they were dewormed with thiabendazole, vaccinated against contagious bovine pleuropneumonia, rinderpest, blackquarter and anthrax. They were sprayed with chlorfenvinphose (Pfizona, Pfizer). The animals were kept in pen, fed with diet supplemented with a mixture of wheat offal and hay. Their blood was taken screened for haemoparasites and confirmed negative. Water and salt licks were provided *ad libitum*.

Experimental design

The animals were divided into 3 groups of four animals each. A group served as control while the others were infected – lactose infused and infected non-lactose infused, respectively. Amongst the infected-non-lactose infused calves, 2 were sacrificed; also amongst the infected-lactose infused calves 2 were sacrificed. One of the control calves was also sacrificed for detailed gross and histopathological studies. The Calves were housed separately. The level of parasitaemia was monitored and at the end of 5 days all the calves were sacrificed.

The carcasses were examined grossly and the gross lesions were recorded.

Infection of the experimental animals

Except for the calves that served as control, the calves in each group were infected with 11×10^6 trypanosomes intravenously with sterile syringe and needle. The level of parasitaemia was monitored daily by HCT, wet mount and haemocytometer techniques.

Preparation and administration of lactose solution for infusion

A 50% solution of lactose in physiological saline (0.9% NaCl) was prepared and placed in an injection bottle, plugged, autoclaved at 15lbs pressure for 5 minutes and allowed to return to room temperature. Normal saline as a solvent was preferred to prevent any minimal systemic haemolysis. Approximately, 80 to 90ml of the lactose solution was administered into four of the infected calves at the peak of the parasitaemia (3-6 days), depending on body weight. It was administered at the rate of 0.5g lactose per kg body weight, three times daily at four hours intervals, intravenously, with sterile syringes and needles at approximately 18ml/minute (Umar *et al.*, 1998). The lactose infusion was done for four days. The lactose solution was not administered into the remaining four infected calves.

Histopathology

Tissue sections of the liver, kidney, spleen, prehepatic and mesenteric lymph nodes, lung, heart, intestine and brain samples were fixed in 10% buffered formalin (PH 7.4) for at least 48 hours. The tissues were processed using technicon and sectioned at 5 to 6 μ m. The tissue section were mounted on clean glass slides in the presence of egg albumin, dried at room temperature and stained with hematoxyline

and eosin. The stained tissue was coverslipped and dried in the oven.

The slides were examined microscopically (Olympus x 40 objective). The histopathological findings were recorded.

Statistical analysis

The data was statistically analysed using student's t-test (Philips, 1978).

RESULTS

Infected-non-lactose infused calves

Gross lesions

The gross lesions observed included pale mucous membranes (severe anaemia) (Table I), rough hair coat, emaciation, serous atrophy of fat, hepatomegally, splenomegaly and enlarged oedematous lymph nodes.

Microscopic lesions

In the liver, there was diffuse areas of necrosis of the hepatocytes, erythrophagia by the kupffer cells, dilated sinusoids (at the portal area) and mononuclear cellular infiltration into the necrotized areas (Fig. 1).

In the spleen and lymph node, there were lymphocyte proliferation (active follicles), plasma cells and haemosiderosis (Fig. 2).

The kidney had hypercellular glomeruli and adhesion of the parietal layer of the glomeruli to the Bowman's capsule, necrosis of the proximal, distal and collecting tubules, periglomerular and inter-tubular mononuclear cellular infiltration into the necrotized areas (Fig. 3)

The heart had minimal myocarditis. The brain, lung, and the intestine had no significant histopathological lesions.

TABLE I: Profiles of mean PCV for all groups

Days post infection	Mean PCV (%)		
	Infected infused group mean \pm Sem	Infected uninfused group mean \pm Sem	Uninfected uninfused (Control) group mean \pm Sem
0	25.5 \pm 1.84	20.0 \pm 1.67	25.0 \pm 1.67
1	25.5 \pm 1.60	20.5 \pm 1.86	24.5 \pm 1.86
2	25.5 \pm 1.62	21.0 \pm 1.33	24.5 \pm 1.33
3	25.0 \pm 1.54	20.5 \pm 1.33	24.5 \pm 1.33
4	25.5 \pm 1.52	20.0 \pm 1.33	25.0 \pm 1.33
5	24.5 \pm 1.73	18.5 \pm 1.33	25.0 \pm 1.33
*6	22.5 \pm 1.60	18.0 \pm 1.67	25.5 \pm 1.66
7	24.0 \pm 1.37	16.5 \pm 1.86	25.0 \pm 1.86
8	20.0 \pm 1.30	13.0 \pm 1.33	25.0 \pm 1.33
9	22.5 \pm 1.65	16.5 \pm 1.86	25.0 \pm 1.86
**10	21.0 \pm 1.42	16.0 \pm 1.86	25.0 \pm 1.86
11	18.5 \pm 1.06	16.5 \pm 1.46	26.0 \pm 1.46
12	19.5 \pm 1.06	20.0 \pm 1.46	26.0 \pm 1.46
13	18.0 \pm 1.06	17.0 \pm 1.46	25.0 \pm 1.33

* The day when lactose infusion started

** The last day of lactose infusion

SEM: \pm the standard error of the means.

The difference between the mean PCV values of the infected infused and the mean PCV values of the infected uninfused was statistically significant ($P < 0.05$).




Fig. 1: Histopathological section from the liver of a *T. vivax* infected calf. Note necrosis of the hepatocytes(N), erythrophagia(E) at the portal area and dilated sinusoids H & X400.

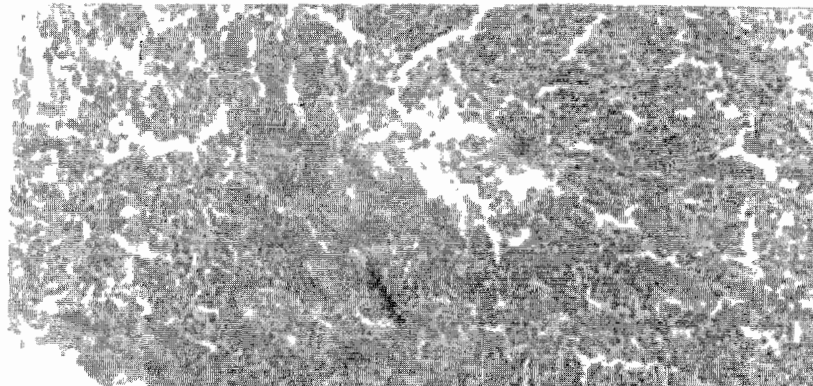


Fig. 2: Histopathological section from the spleen of a *T. vivax* infected calf. Note the lymphocytes proliferation (active follicles) in the spleen. H & E X400.

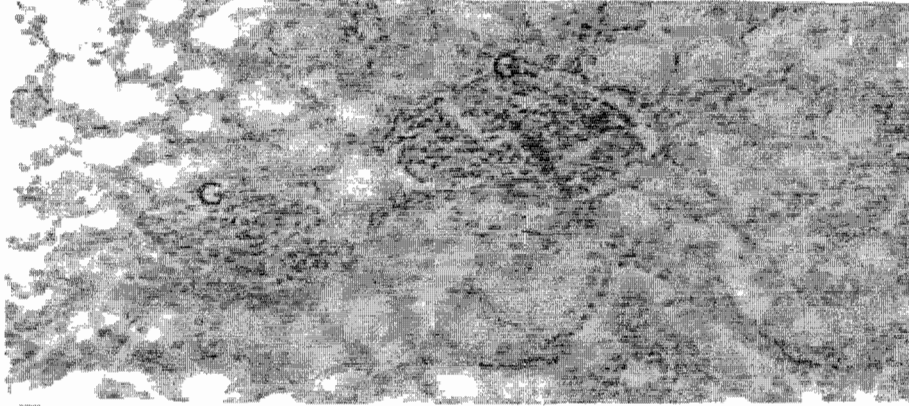


Fig. 3: Histopathological section from the kidney of a *T. vivax* infected calf. Note hypercellular glomeruli, adhesion of the parietal layer of the glomeruli to the Bowman's capsule (G), necrosis of the renal tubules and periglomerular and inter-tubular mononuclear cellular infiltration. H & X400.




Fig. 4: Histopathological section from the liver of a *T. vivax* infected, lactose infused calf. Note fatty degeneration of the hepatocytes and scanty erythrophagia at the centrilobular area. H & E X400.

Infected-lactose-infused calves

Gross lesions

Pre-lactose infusion

The gross lesion was pale mucous membranes (severe anaemia) from days 0 – 6 (Table I). The PCV was changed from 25.5% to 22.5%.

Post-lactose infusion

The mucous membranes were slightly pale (slightly anaemic) Table I. The carcasses were relatively emaciated at the time of necropsy and there were no significant gross lesions in other organs.

The Control Calves

Gross lesions

There were no observable gross lesions in the carcasses.

Microscopically

There was fatty degeneration of the hepatocytes and scanty erythrophagia by the Kupffer cells at the centrilobular area, compared to that of infected-non-lactose infused calves (Fig. 1 and 4). There was less dense lymphoid hyperplasia in the spleen (Fig. 5). The glomeruli were hypercellular and there was no adhesion. The Bowman's space was wide and there was no necrosis of the renal tubules (Fig. 6). There were no significant histopathological lesions in the heart, lungs, brain, and intestine.

Microscopically

The liver, kidney, spleen, lymph node, lung, heart, brain, and intestine did not show significant histopathological lesions.

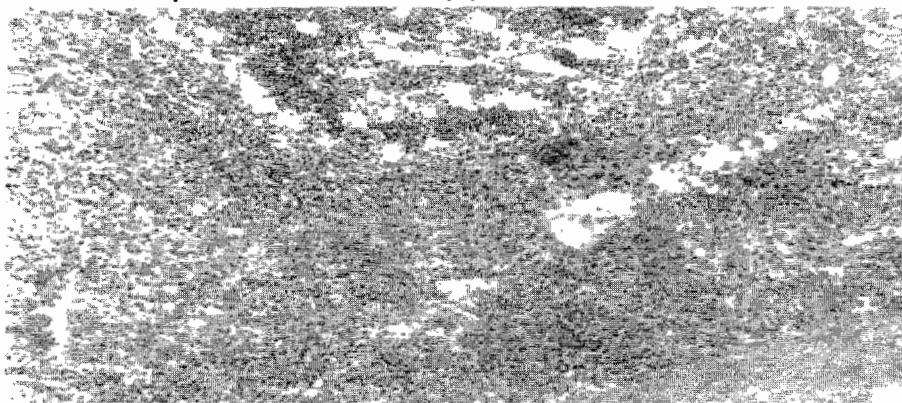


Fig. 5: Histopathological section from the spleen of a *T. vivax* infected, lactose infused calf. Note the less dense lymphoid hyperplasia in the spleen H & E X400.

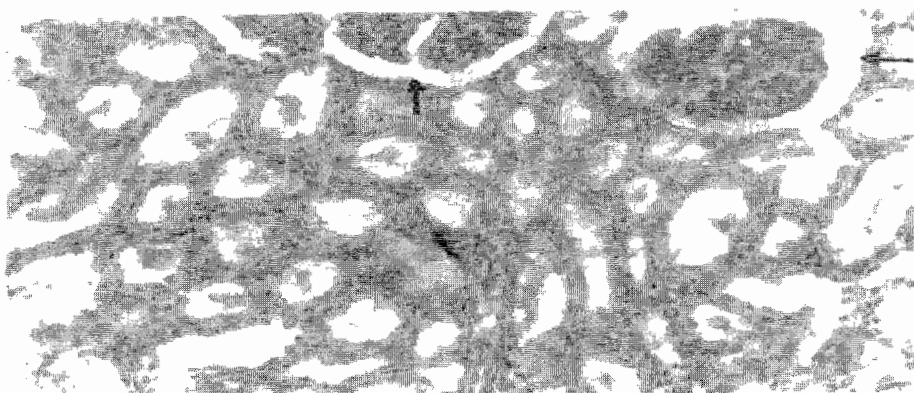


Fig. 6: Histopathological section from the kidney of a *T. vivax* infected, lactose infused calf. Note the wide Bowman's space with no adhesion of the parietal layer of the glomeruli to the Bowman's capsule. Also note the absence of renal tubular necrosis. H & E X400.

DISCUSSION

The predominant gross pathological features in trypanosomiasis include anemia, rough hair coat, emaciation, serous atrophy of the coronary fat, hepatomegaly, splenomegaly and enlarged edematous lymph nodes (Fiennes, 1970; Naylor, 1971; Isoun and Esuruoso, 1972; Losos and Ikede, 1972; Jennings *et al.*, 1974; Murray *et al.*, 1974; Van Den Ingh *et al.*, 1976; Anosa and Isoun, 1976; Saror, 1980; Esiebo *et al.*, 1982). In the present study, severe anaemia, rough hair coat, emaciation, and lymphadenopathy were observed in all the infected calves and at pre-lactose infusion stage after

establishment of the disease. In addition, other observed gross lesions in the infected-non-lactose infused calves were hepatomegaly, splenomegaly, lymphadenopathy and serous atrophy of fat. Following lactose infusion, the anemia was ameliorated, it became mild and the infected-lactose-infused calves then became only slightly emaciated ($P < 0.05$). The liver, spleen, lymph node, and kidney had no observable gross lesions, so also other organs of the carcasses of the infected-lactose-infused calves, an observation that was not reported earlier. However, recently Fatihu (2004) reported that lactose infusion in bovine trypanosomiasis (*T. vivax*) infection prevented early onset of anaemia,

had caused decline in the total plasma protein but, did not prevent leukopenia.

The microscopic feature commonly associated with trypanosomiasis include active follicles with enlarged germinal centers in the lymph node and spleen. Hyperplastic lymphocytes, haemosiderin laden macrophages in the spleen, lymph node, and liver necrosis and erythrophagocytosis by Kupffer cells in the liver. Hypercellular glomeruli, necrosis of the renal tubules, in some cases dilated paroximal tubules with cuboidal epithelial cells, oedema in the alveoli, myositis and myocarditis in some cases with mononuclear cellular infiltration were reported (Fiennes, 1970; Naylor, 1971; Isoun and Esuruoso, 1971; Losos and Ikede, 1972; Anosa and Isoun, 1976; Van Den Ingh *et al.*, 1976; Soror, 1980).

In the present study, there was necrosis of the hepatocytes, erythrophagia by the Kupffer cells similar to previous report by Van Den Ingh *et al.* (1976) and dilated sinusoidal spaces in the infected-non-lactose infused calves. These observed histopathological lesions may indicate that there was interference with the normal cellular and biochemical changes resulting in prevention of the normal physiological function of the liver such as biliary secretion and detoxification, In contrast, the liver of infected-lactose-infused calves had fatty degeneration of the hepatocytes, and scanty erythrophagia (Fig. 1 and 4). These observations compare favorably with that of the control uninfected calf, suggesting that the lactose infusion into *T. vivax* infected calves may be preventing the tissue and cellular damage as manifested histopathologically in the organs associated with the infection. These may lead to near normal, in the restoration of the morphological structure and normal physiological function of the organ.

The observed hypercellular glomeruli in the kidney of the infected calves was similar to that of earlier report by Valli and Forsberg (1979) and in addition, in the present study there was adhesion of the parietal layer of the glomeruli to the Bowman's capsule and necrosis of the renal tubules with mononuclear cellular infiltration. However, in the infected-lactose-infused calves the Bowman's space was dilated and there was no adhesion of the glomeruli to the Bowman's capsule or renal tubular necrosis (Fig. 3 and 6). It would appear that the role of lactose in the prevention of microscopic damages in the liver as stated above also applies to the kidney. This implies that, it prevented destruction of the normal morphology of the tissues and cells of the liver, spleen and kidney to near normal morphology.

In this study, there was proliferation of hyperplastic lymphocytes, plasma cells, haemosiderin-laden macrophages and very active splenic follicles in the infected-non-lactose infused calves. Similar report was made (Van Den Ingh *et al.*, 1976; Valli and Forsberg, 1979; Saror, 1980). However, in contrast, the present study has shown that the lymphoid hyperplastic was less dense in the infected-lactose-infused calves (Fig. 2 and 5), further supporting the role of lactose in preventing or reducing microscopic damages during *T. vivax* infection in cattle.

It may be concluded that, the inhibitory effect of lactose on tissue and cellular injury and erythrophagocytosis by Kupffer cells as shown in the infected -lactose infused calves (Fig. 1 and 4) can result in the following: Amelioration of anaemia, prevention of destruction of the normal morphology of the tissues and cells of the liver, spleen and kidney to near normal in trypanosomiasis. This implies that

probably the normal physiological functions of these organs, such as detoxification of toxic substances by the liver, excretion of such toxic substances by the kidney of the animal suffering from trypanosomiasis may be restored by concurrent lactose infusion during chemotherapy of trypanosomiasis or by using lactose as a base for trypanocidal agents.

REFERENCES

- ANOSA, V.O. and ISOUN, T.T. (1976): Serum proteins, blood and plasma volumes in experimental *Trypanosoma vivax* infection in goats. *Trop. Anim. Hlth. Prod.*, **8**: 14 – 19.
- ANOSA, V.O. and ISOUN, T.T. (1980): Further observations on the testicular pathology in *Trypanosoma vivax* infection of sheep and goats. *Res. Vet. Sci.*, **28**: 151 – 160.
- EDWARDS, E.E., JUDD, J.M. and SQUIRE, F.A. (1956): Observations on Trypanosomiasis in domestic animals in West Africa. *Ann Trop Med Parasitol.*, **50**: 223 – 241.
- ESIEVO, K.A.N., SAROR, D.I., ILEMOBADE, A.A. and HALLAWAY, M.H. (1982): Variations in erythrocyte surface and free serum sialic acid concentrations during experimental *T. vivax* infection in cattle. *Res. Vet. Sci.*, **32**: 1 – 5.
- ESIEVO, K.A.N. and SAROR, D.I. (1991): Immunochemistry and immunopathology of animal Trypanosomiasis. *Protozoological Abstracts*, CAB international, **15**: 337 – 348.
- FIENNES, R.N.T.W. (1970): Pathogenesis and pathology of animal Trypanosomiasis. In: *The African Trypanosomiasis*. Ed. By H.W. Mulligan, George Allen and Unwin Ltd., 40 Museum Street, London, pp. 729 – 750.
- FATIHU, M.Y. (2004): The efficacy of lactose in the prevention of anaemia, tissue pathology and thyroid gland dysfunction in Zebu cattle experimentally infected with *Trypanosoma vivax*. Ph.D thesis. Ahmadu Bello University, Zaria.
- IBRAHIM, N.D.G. (1997): The role of Kupffer cell surface lectin in erythrophagocytosis in bovine *T. vivax* infection. Ph.D. Thesis. Ahmadu Bello University, Zaria, NIGERIA.
- ISOUN, T.T. and ESURUOSO, G.O. (1972): Pathology of natural infection of *T. vivax* in cattle. *Nig. Vet. J.*, **2**: 42 – 45.
- JENNINGS, F.W., MURRAY, P.K., MURRAY, M. and URQUHART, G.M. (1974): Anaemia in Trypanosomiasis: Studies in rats and mice infected with *T. brucei*. *Res. Vet. Sci.*, **16**: 70 – 76.
- KOLB, H. and KOLB – BACHOFEN, V. (1978): A lectin – like receptor on mammalian macrophages. *Biomed. Biophys. Res. Commun.*, **85**: 678 – 683.
- KUSTER, J.M. and SCHAUER, R. (1981): Phagocytosis of sialidase treated rat erythrocytes: evidence of a two-steps mechanisms. *Hoppe – Seyler's Zeitschrift fur Physiologisch Chemie*, **362**: 1507 – 1514.
- LOSOS, G.J. and IKEDE, B.O. (1972): Review of pathology of the diseases in domestic and laboratory animals caused by *T. congolense*, *T. brucei*, *T. rhodensiense* and *T. gambiense*. *Vet. Path.*, **9**: 1 – 71.

- MACKENZIE, P.K.I. and CRUICKSHANK, J.G. (1973): Phagocytosis of erythrocytes and leukocytes in sheep infected with *T. congolense*. *Res. Vet. Sci.*, **155**: 256 – 262.
- MULLER, E., FRANCO, M.W. and SCHAUER, R. (1981): Involvement of membrane galactose in the *in vivo* and *in vitro* sequestration of desialylated erythrocytes. *Hoppe – Seyler's Zeitschrift Fur Physiologisch Chemie*, **362**: 1615 – 1620.
- MULLER, E. and SCHAUER, R. (1983): Factors influencing binding and phagocytosis of sialidase-treated erythrocytes by homologous rat peritoneal macrophages. Glycoconjugates. In: Proceedings of the 7th Symposium on Glycoconjugates Lund Ronneby, July 17 – 23rd pp. 667 – 668. Ed. By Chester, M.A. Heingard D., Lundblann, A. and Svensson, S.J.
- MURRAY, M., MURRAY, P.K., JENNINGS, F.W., FIHSER, E.W., and URQUHAZRT, G.M. (1974): The pathology of *T. brucei* infection in rat. *Res. Vet. Sci.*, **16**: 77 – 84.
- NAYLOR, D.C. (1971): The haematology and histopathology of *T. congolense* infection in cattle. *Trop. Anim Hlth. Prod.*, **3**: 159 – 168.
- PHILIPS O.S. (1978). *Basics Statistics for Health Science Students*, H.W. Freeman and Company, San Francisco.
- SAROR, D.I. (1975): Haematology, serum iron and iron-binding capacity of apparently normal and Trypanosoma infected Zebu cattle. Ph.D. Thesis. Ahmadu Bello University, Zaria.
- SAROR, D.I. (1980): Observations on the course and pathology of *T. vivax* in red Sokoto goats. *Res. Vet. Sci.*, **28**: 36 – 38.
- UMAR, I.A., OMAGE, J.J., SHUGABA, A., IGBOKWE, I.O., IBRAHIM, N.D.G., KADIMA, B. KWEM, AMEH, D.A., KWANASHIE, O. HELEN, AGBEDE, R.I.S., SAROR, D.I. and ESIEVO, K.A.N. (1998): Effects of acute bovine Trypanosomosis (*T. vivax*) on plasma kinetics of intravenously administered lactose. *Vet. Parasitol.*, **74**: 173 – 178.
- VALLI, V.E.O. and FORSBERG, C.M. (1979): The pathogenesis of *T. congolense* infection in calves. V. Quantitative histological changes. *Vet. Path.*, **16**: 334 – 368.
- VAN DEN INGH, T.S.G.A.M., ZWART, D., SCHOFMAN, A.J.H., and VEENENDAAL, G.H. (1976): The pathology and pathogenesis of *T. vivax* infection in goats. *Res. Vet. Sci.*, **21**: 264 – 270.