



## Radiographic Determination Of Costophrenic Angle Sizes In The Nigerian Indigenous Dog

**Rock Odimma Ukaha<sup>1</sup>, Kenneth Kalu Agwu<sup>1</sup>, Raphael O Kene<sup>2</sup>.**

<sup>1</sup>Micheal Opkara University of Agriculture, Umudike Abia State, Nigeria. <sup>2</sup>University of Nigeria, Enugu Campus, Enugu, Nigeria. Corresponding author: Email: [ukaha.rock@mouau.edu.ng](mailto:ukaha.rock@mouau.edu.ng) Tel No: +234 8061530565

### **ABSTRACT**

Assessment of major organs like the heart, trachea, lungs, and diaphragm forms the most common thoracic investigation in small animal radiology. In other words, consideration of the sizes and shapes of thoracic sinuses are usually overlooked, unless the angular recesses are grossly abnormal. The objective of this cross-sectional prospective radiologic study was to measure and document normal index values of costophrenic angular recesses in the Nigerian indigenous dog breed. A total 30 dogs (average body weight:  $8.19 \pm 2.45$  kg) were used for the investigation. Thoracic dorsoventral (DV) and ventrodorsal (VD) projections were obtained of each dog, giving a total of 60 radiographs. Each thoracic silhouette was carefully studied and the costo-phrenic angular recesses (CPAs) were measured, in both DV and VD views, and recorded. Expressed as means and standard errors of means, the results obtained were:  $23.40 \pm 0.770 / 23.40 \pm 0.540$  for the left/right DV CPAs and  $24.20 \pm 0.620 / 24.27 \pm 0.600$  for left/right VD CPAs, respectively. The results of this study are clinically relevant and objectively easily applicable in canine practice for thoracic studies.

**Keywords:** Angular Measurement, Costophrenic Recesses, Radiology, Thoracic Projections.

### **INTRODUCTION**

Assessment of dimensions and shapes of major organs like the heart, trachea, lungs, and diaphragm, (and the positioning of these organs

relative to neighboring structures) forms the most common thoracic investigation in small animal radiology. In other words, consideration of the sizes of thoracic sinuses are usually ignored or

overlooked, unless the angular recesses are grossly abnormal. Costophrenic angle (CPA), used synonymously in radiology with costodiaphragmatic recess or phrenicocostal sinus, is the angle between the costal and diaphragmatic parietal pleurae as they meet at the costodiaphragmatic line of pleural reflection (Blood *et al.*, 2007). The CPA is the recess, in dorsoventral and ventrodorsal radiographs, between ribs (*costa*) and diaphragm (*phrenicus*), formed on either side by the dome of each hemidiaphragm and the thoracic wall.

Each CPA is a potential space in the pleural cavity, at the caudoventral tips of the cavity, and sharply-pointed, downward indentation, normally containing a small portion of each lung. (Kealy and McAllister, 2000; Gaschen, 2013). The normal costophrenic angle size in man usually measures thirty degrees ( $30^0$ ) (Mocelin and Fischer, 2002). The lungs expand into this angular recess during forced inspiration. At expiration, the sinus contains no lung tissue, only pleural fluid. The pleural cavity is usually empty, but may contain a small amount of fluid which serves as a lubricant to minimize friction to respiratory movements as the lungs expand during inspiration and deflate in exhalation. However, the pleural cavity can become a real space for abnormally increased volume of fluid or any other space-occupying lesion (Bates *et al.*, 2001; Gaschen, 2013). Pleural fluid flows through the pleural interface, being secreted by the systemic capillaries of the parietal pleura and resorbed by pulmonary capillaries at the visceral pleura (Marx *et al.*, 2010).

Pleural fluid is also cleared by lymphatic absorption leaving behind only 5–15 ml of fluid in man, which helps to maintain a functional vacuum between the parietal and visceral pleurae (Ferrer and Roldan, 2000; Gallardo *et al.*, 2000; Bates *et al.*, 2001; Marx *et al.*, 2010; Porcel and Light, 2013). Fluids of various kinds may accumulate in the pleural space including lymph or chyle (chylothorax), blood (haemothorax), serum (hydrothorax), pus (empyema, or pyothorax), or urine (urin thorax) very occasionally (Light *et al.*, 1972; Porcel and Light, 2008; Jany and Welte, 2019; USNLM, 2021). When unspecified, the term "pleural effusion" normally refers to hydrothorax. A pleural effusion can also be complicated by air accumulation in the pleural space leading to hydropneumothorax (Marx *et al.*, 2010). Pleural effusion associated with bacterial pneumonia, bronchiectasis or lung abscess is called parapneumonic effusion (Marx *et al.*, 2010). In some diseases, pleural fluid will accumulate if the rate of pleural fluid formation exceeds that of its resorption. Main causes of pleural effusion include cancer, cardiac failure, pneumonia, tuberculosis, pericardial diseases and cirrhosis (Porcel and Light, 2013).

Based on its composition, pleural effusions are generally classified into two types, namely: transudates and exudates (Light *et al.*, 1972). Transudates are fluids of low protein levels and occur in elevated hydrostatic pressure (as in congestive heart failure and hypoalbuminemia), diminished oncotic forces (e.g. hypoproteinemia), increased negative intrapleural pressure (e.g. atelectasis), and ascitic fluid flow across the diaphragm (as seen in hepatic hydrothorax)

(Ferrer and Roldan, 2000; Gallardo *et al.*, 2000; Porcel and Light, 2013). On the other hand, exudates are high-protein-content fluids as a result of increased capillary permeability secondary to infection, neoplasia (resulting in reduction or blockage of lymphatic drainage) or inflammatory process (e.g. parapneumonic effusions) (Ferrer and Roldan, 2000; Gallardo *et al.*, 2000; Porcel and Light, 2013).

Pleural fluid often builds up in the CPA pushing the lung upwards and resulting in "blunting" of the angle. Obtuse angulation of the phrenicocostal sulcus is a sign of disease. Fluid gravitates ventrally in DV radiographs causing cardiac border effacement. In VD projections, pleural fluid usually does not obscure the cardiac silhouette because the fluid now gravitates to the dorsal aspect of the thorax without making contact with the heart to cause any silhouette effect or border effacement. The fluid may cause loss of the normal sharp acuteness (or blunting) of the costophrenic angles in VD/DV views if present between the dorsocaudal aspect of the lung and diaphragm. Advanced imaging modality where available, pleural fluid analysis and pleural biopsy when applicable, are necessary to uncover the underlying disease and its aetiology (Volpicelli *et al.*, 2012; Lau *et al.*, 2017). Rounding of the phrenicocostal angles is used in addition to other radiographic signs of pleural fluid to diagnose pleural effusion. However, radiography is an effective method of diagnosing pleural effusion. Scientific publications of thoracic angular recesses are generally scanty in dogs including the Nigerian Indigenous Dog. Therefore, the present investigation was conducted to estimate reference

measurement values for use in small animal clinical practice for radiologic evaluation of the costophrenic angular recesses in the Nigerian Indigenous Dog.

## **MATERIALS AND METHODS**

### **Design and Location of the Study**

This research was a prospective radiographic cross-sectional survey involving measurements of some thoracic angular recesses of the Nigerian Indigenous Dog (NID); the dogs were sampled using non-probability convenience sampling method.

The work was conducted in the Department of Veterinary Surgery & Radiology, University of Nigeria, Nsukka. Nsukka is a town within the tropical savannah zone of South-eastern Nigeria (latitudes 6° 51' 24" N and longitudes 7° 23' 45" E) (classified as Aw by Koppen and Geiger), 500 m above sea level (Wikipedia.org/wiki/Nsukka) with average annual rainfall and average annual temperature of 1579mm and 24.9°C, respectively.

### **Procurement of Dogs and X-Ray Equipment**

A total of 30 physically well-developed Nigerian Indigenous Dogs (NIDs), equally distributed by sex (50% male, 50% female) including puppies, that is, dogs less than 12 months old (Blood & Studdert, 2005), were procured from local breeders and used for the present study. The dogs were quarantined and acclimatized for 4 weeks. Within that period, the dogs were subjected regularly to general examinations and screened for cardiovascular diseases. Physiological parameters, haematological indices and serum biochemical profiles of the dogs were comparable with findings documented for the NID (Atata *et*

*al.*, 2018). The dogs had no clinical sign of cardiovascular or pulmonary disease and since the vital parameters and laboratory results fell within reference ranges, the animals were adjudged healthy and suitable for the present research (Straub *et al.*, 2002). The body weights of the dogs ranged from 4.0 to 15.6 kg with an average of  $8.19 \pm 2.45$  kg, comprising equal number of both sexes. Identification of individual dogs was by the use of neck chains with pendants numbered 1-30. Materials used for the study included a mobile x-ray machine, Dean Dynamax 40, (GEC Medical Equipment, England), a viewing box, a brand of blue sensitive x-ray film (Begood<sup>®</sup> Medical X-ray, China), cassettes and screens (High-speed Rare earth blue 400, NACAL Medical, England), processing chemicals: developer and fixer powders (Begood<sup>®</sup>, China), a standard protractor and a weighing scale. In all the radiographic exposures, film-focus distance was set at 90 cm while the object-film distance was zero. The dogs had different thoracic thicknesses, and so the kilovolt and milliampere settings were varied (according to each dog's chest thickness) from 45 to 50 kV and 5 to 10 mAs, respectively. Grid was not used in this research, as none of the dogs had a chest thicker than 11 cm.

### **Ethical Approval**

Procedures adopted for the housing and management of the dogs used in the present work were based on the ethical standards of Research Ethical Committee (Approval No: MOUAU/CVM/REC/202125) of the College of Veterinary Medicine, Michael Okpara University of Agriculture, Umudike, Nigeria and on the Helsinki Declaration of 1975 revised in 2000.

### **Description of Radiographic Procedures**

Each of the research animals was restrained for radiography with xylazine hydrochloride (XYL-M2<sup>®</sup>: VMD, Belgium) given at 2 mg/kg intramuscularly and intramuscular injection of ketamine hydrochloride (Ketanir<sup>®</sup>, Aculife Healthcare, India) at 10 mg/kg. Leg-ties and sandbags were used for proper animal positioning. Assistants for manual restraint were not involved in this study. Two survey inspirational thoracic projections adequately identified, namely: dorsoventral (DV) and ventrodorsal (VD) projections, were obtained of each research animal as described by Ettinger and Suter (1970) and Douglas *et al.* (1987). Exposed films were processed manually and the films were kept in labelled envelopes.

Under-exposed, over-exposed, artefactual and inadequately processed radiographs were excluded from the research. Excessive thoracic rotation and obliquity in the dorsoventral and ventrodorsal projections was another exclusion criterion. Radiographs with mal-aligned thoracic silhouette were also excluded. We used only those radiographs that were technically adequate and of clinically normal dogs for the research.

### **Method of Data Collection and Statistical Analyses**

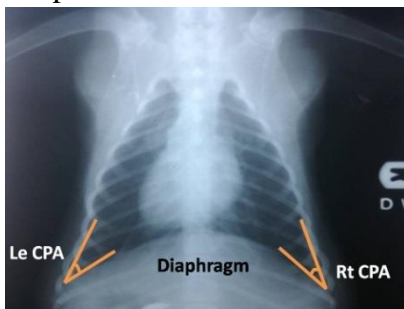
Using a fluorescent viewer and a protractor, sinuses measured in the studied DV and VD radiographs were the right (Rt CPA) and left costophrenic angles (Le CPA) (Figures 1a and b). The angular measurements were taken and recorded in degrees.

Data obtained in the study were expressed in descriptive statistics and displayed in tables. The

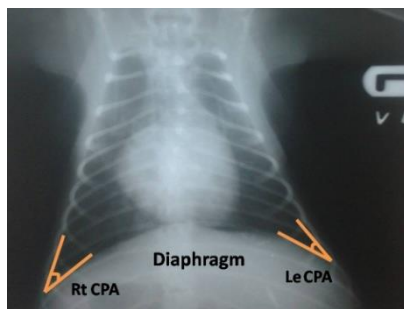
results in degrees were presented as means  $\pm$  standard errors of means. Mean value differences were subjected to Student's t-test using SPSS version 22 for windows. The ranges, means, and standard errors of means were calculated for each sex, age bracket separately, and for all individual animals. A probability value less than, or equal to, five percent ( $p \leq 0.05$ ) was considered statistically significant.

**Delimitation**

The present research sought to ascertain and approximate normal result ranges and mean values of the angular sulci evaluated on thoracic radiographs of NIDs chosen at random without knowledge of their heights, lengths, girths and blood pressures of the dogs. The study did not seek to establish any relationship or correlation between the obtained angular indices and measured body weights, heights, lengths, and or blood pressures of the research animals.



a.



b.

Figure 1: (a) Dorsoventral and (b) ventrodorsal thoracic radiographs of the Nigerian Indigenous Dog showing costophrenic recesses measured for the determination of their normal angular values

**Legends:**

Le CPA = left costophrenic angle

Rt CPA = right costophrenic angle

**RESULTS**

Left mean costophrenic angle (Le CPA),  $23.40 \pm 0.54^0$ , is slightly bigger than right (Rt CPA) mean,  $23.40 \pm 0.77^0$ , in dorsoventral (DV) views. In ventrodorsal (VD) projections, the Rt CPA mean,  $24.27 \pm 0.60^0$ , is slightly more than the Le CPA mean value,  $24.20 \pm 0.62^0$  See TABLE I a.

In TABLE I b and in the DV views of the male dogs studied, Le CPA means  $23.93 \pm 1.06^0$  is greater than the Rt CPA mean values  $23.93 \pm 0.85^0$ , but VD Rt CPA means  $24.33 \pm 0.80^0$  is greater than the VD Le CPA mean values  $24.27 \pm 0.89^0$ . In females, DV Le CPA mean  $22.87 \pm 1.13^0$  is greater than Rt CPA mean value  $22.87 \pm 0.68^0$ ; while VD Le CPA mean  $24.13 \pm 0.90^0$  is slightly less than VD Rt CPA mean value  $24.20 \pm 0.90^0$ .

In TABLE 1 c, adult Rt CPA means  $23.40 \pm 0.76^0$  and  $24.90 \pm 0.79^0$  are greater than the Le CPA mean value  $23.30 \pm 0.86^0$  and  $24.80 \pm 0.72^0$  in both DV and VD views, respectively; whereas in puppies, Rt CPA means  $23.40 \pm 0.70^0$  and  $23.00 \pm 0.66^0$  are less than the Le CPA mean values  $23.60 \pm 0.82^0$  and  $23.00 \pm 0.70^0$  in both DV and VD projections, respectively.

**TABLE I (a): Costophrenic angles in degrees in dorsoventral and ventrodorsal thoracic radiographs of Nigerian Indigenous Dogs.**

| Costophrenic angles | DV Views                | VD Views                |
|---------------------|-------------------------|-------------------------|
| Le CPA              | 23.40±0.77 <sup>0</sup> | 24.20±0.62 <sup>0</sup> |
| Rt CPA              | 23.40±0.54 <sup>0</sup> | 24.27±0.60 <sup>0</sup> |

Mean CPAs are not significantly different from each other (P≥0.05).

**TABLE I (b): Costophrenic angles determined in dorsoventral and ventrodorsal thoracic radiographs of male and female Nigerian Indigenous Dogs.**

| View   | DV (Females)            | VD (Females)            | DV view (Males)         | VD view (Males)         |
|--------|-------------------------|-------------------------|-------------------------|-------------------------|
| Le CPA | 22.87±1.13 <sup>0</sup> | 24.13±0.90 <sup>0</sup> | 23.93±1.06 <sup>0</sup> | 24.27±0.89 <sup>0</sup> |
| Rt CPA | 22.87±0.68 <sup>0</sup> | 24.20±0.90 <sup>0</sup> | 23.93±0.85 <sup>0</sup> | 24.33±0.80 <sup>0</sup> |

Rt CPA and Le CPA mean values in DV and VD views of each sex are not significantly different from each other (P≥0.05).

**TABLE I (c): Age differences in costophrenic angles in dorsoventral and ventrodorsal thoracic radiographs of Nigerian Indigenous Dogs**

| Views  | DV (Adult dogs)         | VD (Adult dogs)         | DV (Puppies)            | VD (Puppies)            |
|--------|-------------------------|-------------------------|-------------------------|-------------------------|
| Le CPA | 23.30±0.86 <sup>0</sup> | 24.80±0.72 <sup>0</sup> | 23.60±0.82 <sup>0</sup> | 23.00±0.70 <sup>0</sup> |
| Rt CPA | 23.40±0.76 <sup>0</sup> | 24.90±0.79 <sup>0</sup> | 23.40±0.70 <sup>0</sup> | 23.00±0.66 <sup>0</sup> |

Mean CPAs in each radiographic view are not significantly different from each other (P≥0.05).

TABLE II is summary table. None of the mean values compared were significantly different from each other.

**TABLE II: Summary of sex and age mean differences, pooled means and ranges of costophrenic angles in degrees (CPA) in DV/VD Radiographs of the Nigerian Indigenous Dog. n = number of radiographs studied**

|                           | CPA <sup>0</sup> (DV)<br>Left angle/Right angle<br>(Range in left angle/right in angle) | CPA <sup>0</sup> (VD)<br>Left angle/Right angle<br>(Range in left angle/right in angle) |
|---------------------------|---|---|
| <b>Male</b><br>(n = 15)   | <b>23.93±1.06/23.93±0.85</b><br>(16 – 31/19 - 30)                                       | <b>24.27±0.89/24.33±0.80</b><br>(18.0-31.0/19.0-30.0)                                   |
| <b>Female</b><br>(n = 15) | <b>22.89±1.13/22.87±0.68</b><br>(15 – 32/18 - 28)                                       | <b>24.13±0.90/24.20±0.92</b><br>(18.0-31.0/20.0-30.0)                                   |
| <b>Adult</b><br>(n = 20)  | <b>23.30±0.86/23.40±0.76</b><br>(16 – 31/18 - 30)                                       | <b>24.80±0.72/24.90±0.79</b><br>(18.0-31.0/19.0-30.0)                                   |
| <b>Puppy</b><br>(n = 10)  | <b>23.60±0.82/23.40±0.70</b><br>(15 – 32/20 - 26)                                       | <b>23.00±0.70/23.00±0.66</b><br>(18.0-29.0/20.0-27.0)                                   |
| <b>Pooled</b><br>(n = 30) | <b>23.40±0.77/23.40±0.54</b><br>(15 – 32/18 – 30)                                       | <b>24.20±0.62/24.27±0.60</b><br>(18.0-31.0/19.0-30.0)                                   |

## DISCUSSION

The pleurae are serous membranes investing the lungs including inter-lobar fissures (pulmonary or visceral pleurae) and lining the walls of the thoracic cavity (parietal pleurae); the two distinct sacs formed by the pleurae enclose potential spaces known as the pleural cavities or the pleural spaces (Kealy and McAllister, 2000; Gaschen, 2013), for collection of pathological fluid.

The easiest and cheapest modality to confirm a provisional diagnosis of pleural effusion, according to Mocelin and Fischer (2002) is thoracic radiography. These authors also reported that pleural fluid is occasionally revealed by thoracic radiographs as an incidental finding. The classic sign of pleural effusion in thoracic projections is rounding or blunting of costodiaphragmatic angles (Bates *et al.*, 2001; Marx *et al.*, 2010). It is already stated that CPAs are diagnostically very important and that the normal value in man of each phrenicocostal recess is  $\leq 30^\circ$  with a sharp point; blunting occurs when the angle is greater than  $30^\circ$ .

However, CPA values determined in the present research for the NID, as recorded in Tables 1 and 2, are more acute with sharper points than the value documented for humans. That means, acuity may not be synonymous with normalcy of costodiaphragmatic angle in the NID. In other words, a CPA of  $28^\circ$  is normal in man but, in the dog, such angular value may indicate the presence of pathological fluid or other space-occupying lesion, based on the results of the present research. The mean values of CPA were slightly higher in VD views than DV means except in puppies for which reverse is the case

with VD ratios slightly less than DV values; but there was not a statistic difference in mean indices between these views, age groups and sexes ( $p \geq 0.05$ ). The slight differences in DV/VD CPA means between puppies (with not fully developed chest) and adult dogs may not be unconnected with differences in thoracic conformations between these two groups of dogs. Evaluation of costophrenic angles in animals is either not reported or obscure, and the present study may be the first document of CPA in the dog. In man and according to Hensche *et al.* (1989), lateral decubitus radiograph with the affected side down is a very clear view to identify an effusion of 5 to 15 millilitres. Blunting or obtuse angulation of the costodiaphragmatic recess is a sign of disease which may be due to pleural effusion, pleural abscess, haemothorax, pulmonary embolism or growth (Ruskin *et al.*, 1987; Armato *et al.*, 1998; Light, 2010). Armato *et al.*, (1998) and Light (2010) disclosed that the most common cause of CPA blunting is pleural fluid, and clinical signs include dyspnoea (fluid accumulation which causes compression of lungs and shortness of breath), thoracic pain due to the compression effect of fluid on lungs, fever observed when pleural effusion is associated with infection e.g. tuberculosis and pneumonia, and cough due to irritation of visceral pleura. These authors (Armato *et al.* and Light) equally reported that dehydration places the diaphragm in a flaccid state resulting in abnormal increase or blunting of CPA. Armato *et al.* and Light also disclosed that effective treatment for CPA blunting include intravenous fluid, broad spectrum or appropriate intravenous antibiotic therapy, thoracocentesis

(needle aspiration), tube thoracotomy, pleural decortications (surgical removal of parietal pleura resulting in decrease secretions of serous fluid), and pleurodesis (artificial obliteration of the space between visceral and parietal pleurae by irritating their surfaces).

Influence of respiratory phases on thoracic conformation was reported by Hassan *et al.*, 2019 as a limitation to accurate parametric measurements in the thoracic silhouette. However and in the present work, all the research animals were exposed in the peak inspirational phase, thereby ruling out any effects of phasic differences. The similarity of results between DV and VD views, male and female dogs, and adult dogs and puppies is further evidence of adequate radiographic procedures with insignificant interference of breathing stages.

## CONCLUSION

In humans, pleural effusion of 200 ml can cause blunting of CPA in a postero-anterior standing projection (Ferrer and Roldan, 2000; Mocelin and Fischer, 2002; Na, 2014). There is no such work and record available or visible for animals including the Nigerian dog. However, the present study has determined, probably, for the first time the normal costophrenic angular values in the NID. The thoracic angular measurements did not change significantly with sex, growth or age in the NID. This present work has provided normal sizes of CPA and the authors recommend the results for use in clinical practice to increase the scope and accuracy of thoracic radiologic diagnoses in the NID. The results of this study provide a helpful guide in the thoracic radiographic evaluation, in clinico-biomedical investigation, of the NID.

However, validation of the results with clinical cases of pleural fluid awaits research. The results determined in this research may proffer useful imaging guidelines in small animal (canine) clinical practice prequel to echocardiography, computed tomography, or other superior methods; or for assessment of costo-diaphragmatic recesses where radiography is the only obtainable research or diagnostic modality.

The results of this investigation are easily reproducible and objective if applied and they should be correlated with computed tomographic findings. We equally recommend further studies on evaluation of costodiaphragmatic recesses in other breeds of dogs for comparative purposes. Clinical significance of this study is related to the diagnosis and treatment of pleural effusion in the NID.

## CONFLICT OF INTEREST

The authors declare no conflicts of interest exist.

## REFERENCE

- ARMATO. S.G., GIGER, M.L., and MACMAHON, H. (1998):  
Computerized delineation and analysis of costophrenic angles in digital chest radiographs; *Academic Radiology* May 5(5):329-335.
- BATES, B., BICKLEY, L.S. and HOEKELMAN, R.A. (2001).  
*Guide de l'Examen Clinique* (4th Ed.). Reuil-Malmaison cedex; Arnette; 239–246.



- BLOOD, D.C. and STUDDERT, V.P. (2005).  
Puppy. *Saunders Comprehensive Veterinary Dictionary* 2nd Ed.,  
WB Saunders Co.: Philadelphia; 947
- FERRER, J. and ROLDAN, J. (2000).  
Clinical management of the patient with  
pleural effusion. *European  
Journal of Radiology* **34**(2):76–86.
- GALLARDO, X., CASTANER, E. and MATA,  
J.M. (2000).  
Benign pleural diseases. *European  
Journal of  
Radiology* **34**(2):87–97.
- GASCHEN, L. (2013).  
The canine and feline esophagus. In Thrall  
DE (Ed.) *Textbook of Veterinary Diagnostic  
Radiology* 6<sup>th</sup> Ed. Elsevier Saunders: St  
Louis: 500-520.
- HASSAN, M.H., HASSAN, E.A., and TORAD, F.A.  
(2019).  
Influence of phase of respiration on thoracic  
conformation at multiple vertebral levels in  
German shepherd dog; *Anatomical Science  
International* 1-5.  
Retrieved from  
<https://link.springer.com/article/10.1007/s00132-019-0350-0>
- HENSCHKE, C.I., DAVIS, S.D., ROMANO,  
P.M. and YANKELEVITZ, D.F. (1989).  
Pleural effusions: pathogenesis,  
radiologic evaluation, and therapy.  
*Journal of Thoracic Imaging* 4(1):49–60.
- JANY, B. and WELTE, T. (2019).  
Pleural Effusion in Adults—Etiology,  
Diagnosis, and Treatment. *Deutsches  
Ärzteblatt International*, **116** (21):377–  
386.
- KEALY, J.K. and McALLISTER, H. (2000).  
The thorax. In Kealy JK and McAllister H  
(Eds) *Diagnostic  
Radiology and Ultrasonography of the Dog  
and Cat* 3rd Ed. WB Saunders  
Co. Philadelphia; 149 -249
- LAU, J.S.K., YUEN, C.K., MOK, K.L.,  
YAN, W.W. and KAN, P.G. (2017).  
*Visualization of the  
inferoposterior thoracic wall (VIP) and  
boomerang signs-novel sonographic signs  
of right pleural  
effusion. The American Journal of  
Emergency Medicine*, **36** (7):1134–1138.
- LIGHT, R.W. (2010).  
Pleural effusion in pulmonary embolism;  
*Semin Respir Crit Care Med* Dec  
**31**(6):716-722.
- LIGHT, R.W., MACGREGOR, M.I.,  
LUCHSINGER, P.C. and BALL, W.C. Jr (1972).  
Pleural effusions: the  
diagnostic separation of transudates and  
exudates. *Annals of Internal Medicine*  
**77**(4):507–513.

- MARX, J.A., HOCKBERGER, R.S., WALLS, R.M. and ADAMS, J.G. (2010).  
Rosen's Emergency Medicine:  
Concepts and Clinical Practice. Vol. 1.  
Mosby Incorporated
- MOCELIN, H.T. and FISCHER, G.B. (2002).  
Epidemiology, presentation and treatment  
of pleural effusion. *Paediatr Respir  
Rev.* 3(4):292–297.
- NA, M.J. (2014).  
Diagnostic tools of pleural effusion.  
*Tuberculosis and Respiratory Diseases*  
(Seoul) **76**:199- 210.
- PORCEL, J.M. and LIGHT, R.W. (2008).  
Pleural effusions due to pulmonary  
embolism. *Current Opinion in  
Pulmonary Medicine* **14** (4): 337–42.
- RUSKIN, J.A., GURNEY, J.W., THORSEN, M.K.,  
and GOODMAN, L.R. (1987).  
Detection of pleural effusions  
on supine chest radiographs. *AJR American  
Journal of Roentgenology* April **148**(4):681-  
683.
- PORCEL, J.M. and LIGHT, R.W. (2013).  
Pleural effusions. *Disease-A-Month  
Journal* **59**(2):29–57.
- USNLM (2021).  
Pleural effusion. United States National  
Library of Medicine.
- STRAUB J, PEES M, and KRAUTWALD-  
JUNGHANN ME (2002)  
Measurement of the cardiac silhouette  
in psittacines, *J Am Vet Med Assoc* Jul 1  
**221**(1):76-79.
- VOLPICELLI, G., ELBARBARY, M., BLAIVAS,  
M., LICHTENSTEIN, D.A., MATHIS, G.,  
KIRKPATRICK, A.W. and MELNIKER, L.,  
Gargani, L. & Noble, V.E. (2012).  
*Intensive Care Medicine* **38** (4):577–591.  
fetus on ram sperm cell quality. *J. Med.  
Microbiol.*, 57, 1405-1410.