



NIGERIAN VETERINARY JOURNAL

ISSN 0331-3026

Nig. Vet. J., July 2023

Vol 44 (3): 47 - 54.

<https://dx.doi.org/10.4314/nvj.v44i3.5>

ORIGINAL ARTICLE

Outbreak Of Fowlpox In Commercial Brown Pullets Previously Vaccinated With Fowlpox Vaccine In Zaria, Kaduna State, Nigeria

Umar, B. N¹.; AHMAD, M. T. ² and UNGOGO M. A^{3,4}.

¹Department of Veterinary Microbiology, Faculty of Veterinary Medicine, Ahmadu Bello University, Zaria, Nigeria.

²Veterinary Teaching Hospital, Ahmadu Bello University, P.M.B 1045, Zaria, Nigeria. ³Department of Veterinary Pharmacology and Toxicology, Faculty of Veterinary Medicine, Ahmadu Bello University, Zaria; ⁴Institute of Infection, Immunity and Inflammation, College of Medical, Veterinary and Life Sciences, University of Glasgow, UK.

*Corresponding author: Email: umarningi5@gmail.com, Tel; +234 807 078 1916.

SUMMARY

Fowlpox is a contagious viral disease of poultry, ranked as the third most important cause of mortality in Nigerian indigenous chickens. The present study confirms an outbreak of fowlpox in a flock of 500 Isa brown, 11-weeks-old pullets in Zaria, Kaduna State, Nigeria. The pullets were managed under deep litter system and previously vaccinated with live attenuated vaccine (ABIC biological laboratories Ltd. Israel) at 8-weeks old. They had gross lesions suggestive of cutaneous fowlpox on skin of the head region with 58% morbidity but persistent low mortality rate of 13.8%. Fowlpox virus was isolated from the cutaneous lesions using chorioallantoic membrane (CAM) inoculation in 9 to 11-day-old embryonated chicken eggs based on the presence of opaque-white pock lesions, then confirmed by Agar Gel Immuno Diffusion test using homologous known fowlpox virus (antigen) and antisera. Specific antibodies to fowlpox virus were quantified from the sera of the chickens using an indirect ELISA (Abbkine, Inc, China). The case was managed using; Intramuscular injection of oxytetracycline (TLA), topical applications of oxytetracycline spray as well as oral administrations of Doxygen® and vitamins. Apparently healthy chickens were revaccinated against fowlpox and the pen was thoroughly cleaned, washed, and disinfected. This report had shown an occurrence of vaccine failure, alongside a promising management option and highlighted the significance of vaccination with strict biosecurity measures in the control of fowlpox in Nigeria.

Keywords: Fowlpox virus, Outbreak, Pullets, Vaccination, Vaccine failure.

INTRODUCTION

Fowlpox is a contagious viral disease of poultry caused by fowlpox virus (FWPV) which is characterized by proliferative multifocal nodular lesions on featherless areas of the skin (cutaneous form) and or diphtheritic lesions on mucous membranes of digestive and respiratory tracts of birds (Tripathy and Reed, 2008; Meseko *et al.*, 2017). Fowlpox is endemic in tropical and subtropical countries, affecting both domestic and wild birds with varying degree of morbidity and mortality (Beytut and Haligur, 2007; OIE, 2016). It is one of the most economically important poultry diseases that is widespread in backyard and to some extent intensively reared poultry flocks in Nigeria (Adene and Fatumbi, 2004). The aetiologic agent of the disease is a double stranded DNA virus in the genus; avipoxvirus, subfamily: *Chordopoxvirinae* and family *Poxviridae*. It is resistant to desiccation, 1% phenol, trypsin treatment and 1:100 formalin for up to nine days (Randall and Gafford, 1962). However, it is sensitive to chloroform and ether (Randall *et al.*, 1964) as well as heating at 50 °C for 30 minutes or 60 °C for 8 minutes (Andrews *et al.*, 1978). The virus can be isolated through inoculation of avian cell cultures (ACC) or via the chorioallantoic membrane (CAM) of 9 to 12- day old embryonated chicken eggs (ECE) (MacLachlan and Dubovi, 2017). Fowlpox is mainly prevented by rigorous sanitary measures and immunization of susceptible birds of usually 6 to 8 weeks or older but at least a month prior to start of lay with attenuated strains of either FWPV or the antigenically similar pigeonpox virus via the wing-web method

(Tripathy and Reed 1997; Hygieia, 2017). The disease may persist for long periods of time especially in high-density multiple-age farms. Despite preventive vaccinations, several recurrent outbreaks have been reported globally (Okworet *et al.*, 2014; Ferreira *et al.*, 2018). In recent years, the world had witnessed a gradual increase in fowlpox outbreaks within both vaccinated and unvaccinated poultry flocks due to an emerging FWPV (Davidson *et al.*, 2008; Zhao *et al.*, 2014). The virulence of these new viruses varies and is enhanced by frequent integration of reticuloendotheliosis virus (REV) sequences into the FWPV genome (Biswas *et al.*, 2011; Zhao *et al.*, 2014). Like most viral diseases, there is no satisfactory treatment for fowlpox. Therefore, this paper reports a clinico-laboratory diagnosis and a particular management approach to field fowlpox disease in previously vaccinated chickens.

CASE PRESENTATION

Appearance of crusty lesions in a flock of 500 Isa brown, 11-weeks-old pullets was reported to the Avian Clinic of Veterinary Teaching Hospital, Ahmadu Bello University, Zaria, from a commercial poultry farm located at Zangon Shanu, Samaru, Zaria, Nigeria. Other major complaints were weakness and persistent mortality for about a week. History revealed that the birds had up to date Gumboro and Newcastle disease vaccination record, were managed on self-compounded feed and have been vaccinated with live attenuated fowlpox virus vaccine (ABIC biological laboratories Ltd. Israel) at 8-weeks old.

Clinical Examination

A farm visit was carried out, and analyses of farm records and clinical presentations of the disease were made. Clinical signs observed were stunted growth, ruffled feathers, somnolence, huddling, anorexia, unilateral and bilateral blindness, serous ocular discharge, typical skin pock lesions (Plate 1A) and soiled vent (Plate 1B). The cutaneous lesions on featherless skin areas of their backs, eyelids, nostrils and commissure of the beaks ranged from nodular, ulcerative to multifocal or coalescing proliferative type. There was no vaccine “take” reactions within the supposed fowlpox vaccination (wing web) sites. The morbidity and mortality rates were 58% and 13.8 %, respectively while the mortality pattern was 5,7,14,16,19 and 8. Based on the history and clinical examination, fowlpox was strongly suspected. Thus, further investigations were carried out.

MATERIALS AND METHODS

Laboratory Diagnoses

Moribund and dead birds were collected for thorough postmortem evaluation. Cutaneous lesions were aseptically harvested into universal bottle for FWPV isolation. The viral isolation and propagation were achieved using CAMs of 10-day-old specific pathogen free (SPF) chicken embryos in accordance with OIE, (2016) guidelines while fowlpox virus identification was carried out via Agar Gel Immuno Diffusion (AGID) test using homologous known antigen and antisera as reported by Meseko *et al.* (2012). Blood samples from nine (9) apparently healthy pullets were aseptically collected through brachial veins for quantification of specific FWPV antibodies using

an indirect Enzyme Linked Immunosorbent Assay (ELISA) (Abbkine, Inc, China).

Ethical Statement

Ethical approval for the use of animals in this study was provided by the Ahmadu Bello University Committee on Animal Use and Care (ABUCAUC).

RESULTS

The postmortem pathologies observed were, mucoid trachea and pseudomembranous lesions on tip of the tongues (Plate 2A). Opaque-white pock lesions and generalised haemorrhages or thickening of the CAMs (Plate 2B) were observed 5 days post inoculation of 20% scab homogenate containing the fowlpox virus isolate. The result of antibody response to FWPV vaccine is shown in Figure 1; The mean FWPV antibody titre of 1/40 serum dilution of the 9 pullets was 1.19 ng/L.

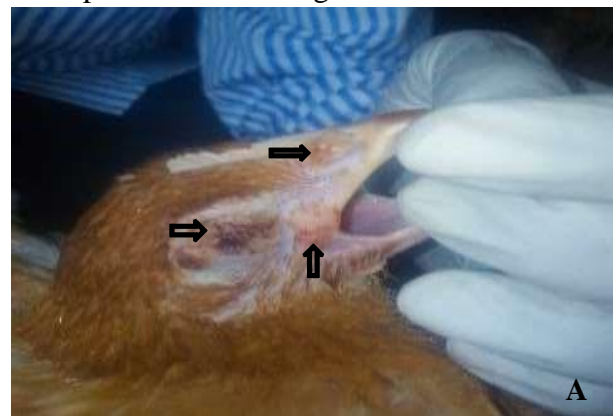



PLATE 1: Macropathologic images of fowlpox virus infection in 11-weeks-old brown pullets from a commercial flock in Zaria, Nigeria. A) Proliferative nodular skin lesions on eyelids, nostril and commissure of the beak (black arrows). B) Moribund and dead birds with soiled vent (black arrow).

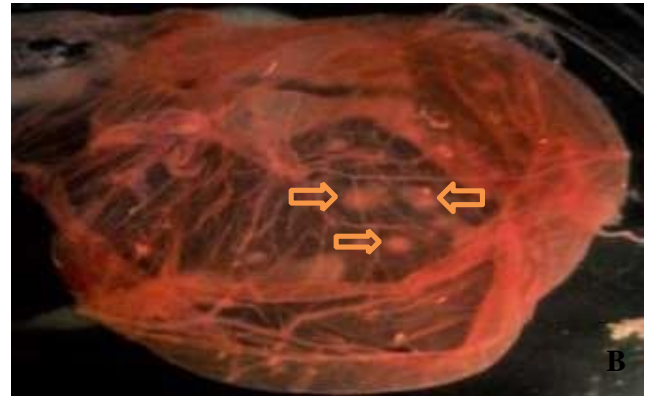
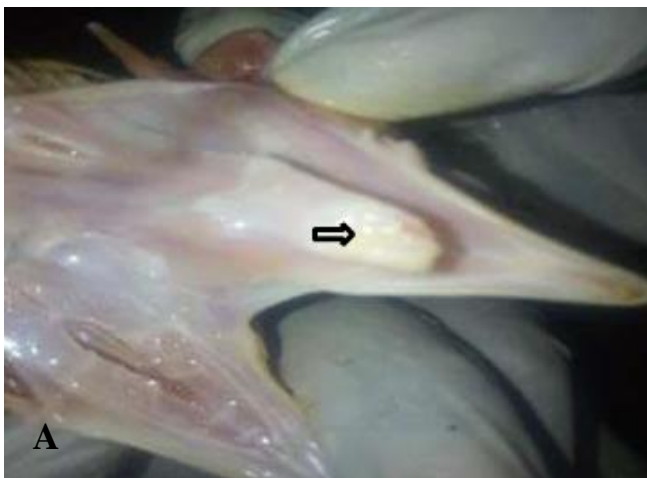

Plate 2: A) Diphtheritic lesion on tip of the tongue (black arrow) following postmortem evaluation, and B) Chorioallantoic membrane of 10-dayold embryonated chicken egg infected with fowlpox virus isolate from fowlpox outbreak in Zaria, Nigeria. Generalised haemorrhages and opaque-white pock lesions (white arrows) are seen.

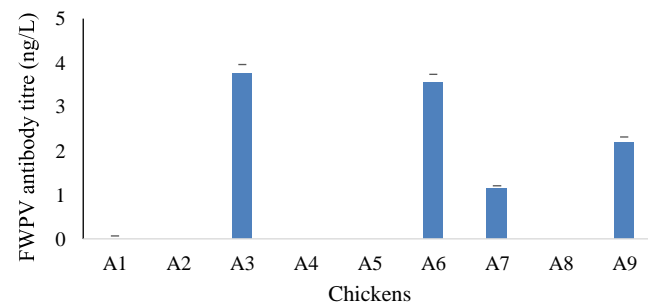


Fig. 1. ELISA antibody response to fowlpox virus vaccine in 11-weeks old pullets vaccinated at 8-weeks of age.

MANAGEMENT

The case was managed using single intramuscular injection of oxytetracycline long acting (TLA, Kepro, Holland) at 0.3 mL per bird (60 mg/bird IM), topical application of oxytetracycline spray (on parts of the body from which lesions were

harvested), and oral administration of V-ox® (mixture of inorganic peroxygen compounds; Polchem Hygiene Laboratories Pvt. Limited, India) and Vitavet® (multivitamins, Pharma-Swede, Egypt) both at 1 g/L of drinking water for 5 consecutive days. Doxygen® (doxycycline and gentamycin, Kepro, Holland) was also administered at 1 g/2 L of drinking water for 3 consecutive days starting from day 3 post oxytetracycline injection. Apparently healthy chickens were revaccinated using live attenuated FWPV vaccine (ABIC Biological Lab. Ltd, division of Phibro Animal Health Corp PO Box 489, West Industrial Zone Beit-Shemesh, Israel) via wing web method. The pen was thoroughly cleaned, washed, and disinfected using Glutasan (glutaraldehyde and alkyl dimethyl ammonium chloride; Pine Oil, USA) at 1:300 dilution of water and Hypo (sodium hypochlorite; Multipro Enterprises Ltd., Nigeria) at 2mL/L of water.

DISCUSSION

Fowlpox occurs most commonly as a cutaneous form, but a diphtheritic form or combination of both forms and a rare systemic form have been reported (Van Riper and Forrester, 2007). This is in line with the current findings as combination of cutaneous and diphtheritic form was observed. Although, the number of passages required for adaptation is unpredictable, the development of pock lesions on infected CAMs of ECE during FWPV isolation is a highly consistent finding (Islam *et al.*, 2008). This observation correlates well with the findings of present study, however, the frequently reported eosinophilic intracytoplasmic inclusion bodies (Bollinger) following histopathological studies of the infected CAMs were not observed. Bollinger bodies are not

always present in fowlpox cases, and our finding agrees with the results of Gilhare *et al.* (2015) and Ferreira *et al.* (2018) who reported the absence of inclusion bodies in more than 50% of their samples. The morbidity and mortality rates reported in the present case were higher than those documented by Ferreira *et al.* (2018), but lower than the findings of Okwor *et al.* (2014), and Zhao *et al.* (2014). The difference might be related to the immune status of the birds, virulence of the FWPV strains involved and the period when intervention was instituted. Many avian pox outbreaks were reported to occur due to improper vaccine administration (Anon, 2016). Similarly, the origin of the present outbreak had been linked to the inability of the FWPV vaccine administered earlier to confer protection, because the infection started 2-weeks post vaccination which was enough to have mounted protective immunity provided that the vaccine was effective. In addition, the ELISA mean antibody titre recorded 3-weeks post vaccination was lower than the protective titre reported by Wang *et al.* (2006), and when the apparently healthy pullets were revaccinated, 90-94% vaccine “takes” were observed. Therefore, the chickens were not initially immunized following the first vaccination, hence confirming vaccination failure. This is in line with the reports of OIE, (2010) and HyeJeong, (2013) who independently stated that the success of vaccination programme against FWPV is established by the presence of protective immune response in over 80% of vaccinated chickens.

CONCLUSION

The present case report confirms an outbreak of fowlpox in previously vaccinated commercial

pullets and presented a management approach that proved to be effective in alleviating morbidity and mortality of fowlpox in chickens.

REFERENCES:

- ADENE, D.F. AND FATUMBI, O. (2004). Case Review and Lesson on Poultry Diseases Control in South West Nigeria, In: *Poultry Health and Production, Principles and Practice*, Stirling Horden Publishers (Nig) Ltd, Ibadan, Oyo State, Nigeria, Pp.191-200.
- ANDREWS, C., PEREIRA, H.G. AND WILDY, P. (1978). *Viruses of Vertebrates* (4th edition). Bailliere Tindall publishers, London, Pp. 356-389.
- ANONYMOUS (2016). Fowlpox in layers: an overview. Hy-Line International Red book. Retrieved on 20 January, 2019 from www.hyline.com.
- BEYTUT, E. AND HALIGUR, M. (2007). Pathological, Immunohistochemical and Electron Microscopic Findings in the Respiratory Tract and Skin of Chickens Naturally Infected with Avipoxvirus. *Turk. J. Vet. Anim. Sci.*,31(5): 311-317.
- BISWAS, S.K., JANA, C, CHAND, K., REHMAN, W. AND MONDAL, B. (2011). Detection of Fowl Poxvirus Integrated with Reticuloendotheliosis Virus Sequences from an Outbreak in Backyard Chickens in India. *Vet. Ital.*, 47:147–153.
- DAVIDSON, I., SHKODA, I. AND PERK, S. (2008). Integration of the Reticuloendotheliosis Virus Envelope Gene into the Poultry Fowlpox Virus Genome is not Universal. *J. Gen. Virol.*, 89: 2456–2460.
- FERREIRA, B.C., ECCO, R., COUTO, R.M., COELHO, H.E., ROSSI, D.A., BELETTI, M.E. AND SILVA, P.L. (2018). Outbreak of Cutaneous Form of Avian Poxvirus Disease in Previously Pox-vaccinated Commercial Turkeys. *Pesq. Vet. Bras.*, 38: 3.
- GILHARE, V.R., HIRPURKAR, S.D., KUMAR, A., NAIK, S.K. AND SAHU, T. (2015). Pock Forming Ability of Fowlpox Virus Isolated from Layer Chicken and its Adaptation in Chicken Embryo Fibroblast Cell Culture. *Vet. World.*, 8: 2231-0916.
- HYEJEONG, H.A., ALLEY, M., HOWE, L. AND GARTRELL, B. (2013). Evaluation of the Pathogenicity of Avipoxvirus Strains Isolated from Wild Birds in New Zealand and the Efficacy of a Fowlpox Vaccine in Passerines. *Vet. Micro.*, 165 (3-4): 268-274.
- HYGIEIA BIOLOGICAL LABORATORIES (2017). Fowlpox Vaccine. Hygieia biological laboratories, P.O. Box 8300, Woodland, California 95776, USA. Retrieved at 10:05 am on 13th march, 2018 from *live virus*. <http://www.drugs.com/vet/fowlpoxvaccine.html>.

- ISLAM, M.R., KHAN, M.S.R., ISLAM, M.A., KAYESH, M.H., KARIM, M.R., GANI, M.O. AND KABIR, A. (2008). Comparative Efficacy of Imported Fowlpox Virus Vaccine with Locally Produced One in Backyard Chicks. *Bangl. J. Vet. Med.*,6 (1):23–26.
- MACLACHLAN, N.J. AND DUBOVI, E.J. (2017). Fowlpox. In: *Fenner's Veterinary Virology* (5th ed.) Elsevier Academic Press, Amsterdam. Pp. 157-174.
- MESEKO, C.A., SHITTU, I.A. AND AKINYEDE, O. (2012). Seroprevalence of Fowlpox Antibody in Indigenous chickens in Jos North and South Council Areas of Plateau State, Nigeria: Implication for Vector Vaccine. *ISRN Vet. Sci.*, 4. doi:10.5402/2012/15497.
- MESEKO, C.A., SHITTU, I., BWALA, D.G., JOANNIS, T.M. AND NWOSUH, C.I. (2017). Fowlpox Virus from Backyard Poultry in Plateau State Nigeria: Isolation and Phylogeny of the P4b Gene Compared to a Vaccine Strain. *Nigerian Vet. J.*, 38 (2): 124-128.
- OIE (Office Internationales Epizooties). (2010). Manual of Diagnostic Tests and Vaccines for Terrestrial Animals. Retrieved at 02:20 pm on 14th march, 2018 from <http://www.oie.int/internationalstandardsetting/terrestrialmanual/access-online>.
- OIE (Office Internationales Epizooties terrestrial manual). (2016). Fowlpox Ch. 3.2.10. Retrieved at 11:30 am on 10th march, 2018 From www.oie.int/fileadmin/Home/eng/Health_standards/tahm/2.03.10_fowlpox.
- OKWOR, E.C., EZE, D.C. AND CHAH, K.F. (2014). Recurring Outbreaks of Fowl Pox in a Poultry Farm in Nsukka, Southeast Nigeria. *IOSR JAVS*,7 (4): 104-108.
- RANDALL, C.C AND GAFFORD, L.G.(1962). Histochemical and biochemical studies of isolated viral inclusions. *Am. J. Pathol.*, 40: 51-62.
- RANDALL, C.C., GAFFORD, L.G., DARLINGTON, R.W. AND HYDE, J. (1964). Composition of Fowlpox virus and inclusion matrix. *J. Bacteriol.*, 87: 939-944.
- TRIPATHY, D.N. AND REED, W.M. (1997). Pox. In: Calnek W.B., Barnes H.J., Beard C.W., McDougald, L.R. and Saif, Y.M. (Eds.) *Diseases of Poultry*, Iowa State University Press, Ames, pp. 643–659.
- TRIPATHY, D.N. AND REED, W.M. (2008). Pox. In: *A Laboratory Manual for the Isolation, Identification and Characterization of Avian Pathogens*. American Association of Avian Pathologists press, Athens, Pp.116-119.
- VAN RIPER, C. AND FORRESTOR, D.J. (2007). Avian pox. In: Thomas, N.B., Hunter D.B. and Atkinson, C.T. (Eds.) *Infectious Diseases of Wild Birds*, IA Blackwell Publishing, Ames, Iowa, USA, Pp. 131-176.

WANG, J., MEERS, J., SPRADBROW, P.B. AND ROBINSON, W.F. (2006). Evaluation of Immune Effects of Fowlpox Vaccine Strains and Field Isolates. *Vet. Micro.*, 116:106–119.

ZHAO, K., HE, W., XIE, S., SONG, D., LU, H., PAN, W., ZHOU, P., LIU, W., LU, R., ZHOU, J. AND GAO, F. (2014). Highly Pathogenic Fowlpox Virus in Cutaneously Infected Chickens, China. *Emerg. Infect. Dis.*, 20(7):1208-1210.