

**SEQUENTIAL HISTOPATHOLOGICAL CHANGES OF THE LOWER RESPIRATORY AND GASTROINTESTINAL TRACTS IN CHICKENS INFECTED WITH VELOGENIC NEWCASTLE DISEASE VIRUS****Igwe, A. O<sup>1\*</sup>**

<sup>1</sup>Department of Veterinary Pathology, College of Veterinary Medicine, Michael Okpara University of Agriculture, Umudike, PMB 7267 Umuahia, Abia State, Nigeria.

\*Corresponding author: Email: [docoleji@yahoo.com](mailto:docoleji@yahoo.com); Tel No: +234 803 450 9991

**SUMMARY**

Velogenic Newcastle disease is a highly contagious and fatal disease that affects domestic poultry, and is clinically manifested by haemorrhagic gastroenteritis and respiratory distress. This study investigated the sequential histopathologic changes in the lungs, proventriculus, and intestines of broiler chickens infected with velogenic Newcastle disease virus (vNDV). Fifty broiler chickens (6-weeks-old) were randomly assigned into two groups of 25 each: UC – unvaccinated with Newcastle disease (ND) vaccines and intranasally inoculated with vNDV, UU – unvaccinated uninfected. At 4, 5 and 6 days post-infection (d.p.i) tissue samples were collected from birds in each group for histopathology. The lungs showed hyperaemia, haemorrhages, inflammatory oedema and cellular infiltrations in the secondary bronchi, parabronchi (atria, infundibular, air and blood capillaries of the exchange tissue), depletion of bronchial-associated lymphoid tissues, loss of cilia and hyperplasia of surface epithelium of bronchi and parabronchi at 4 d.p.i. The lesions progressed to collapsed air capillaries with fibroplasia and fibrosis of the area at 6 d.p.i. Similar inflammatory changes were observed in the proventriculus, but accompanied by degeneration and attenuation of surface epithelium of proventriculus and proventricular glands at 4 d.p.i., and severe necrosis and disintegration of the proventricular glands at 6 d.p.i. The intestine showed severe inflammatory changes in the mucosa, submucosa and serosa and depletion of gut-associated lymphoid tissues at 4 d.p.i., and ulcerative enteritis at 5 d.p.i. The lumen was filled with necrotic debris at 6 d.p.i. This study reinforces the concept making pathologic animal experiments important tools for a complete characterization of strains in susceptible animals, as this information will be helpful in the accurate diagnosis of velogenic Newcastle disease in chickens.

**Key words:** Histopathology, Newcastle disease, Respiratory tract, Gastrointestinal tract, Chickens.

## INTRODUCTION

Newcastle disease virus (NDV), also known as avian orthoavulavirus-1 (AOaV-1), an enveloped avian paramyxovirus virus-1 with a non-segmented, negative-sense RNA genome, of the genus *Orthoavulavirus*, family *Paramyxoviridae* (Amarasinghe *et al.*, 2019; Suarez, 2020). The virulence of NDV strains can be categorized into pathotypes based on their clinical signs in chickens after experimental inoculation. The pathotypes are listed in decreasing order of virulence as velogenic, mesogenic, lentogenic, and asymptomatic enteric (Alexander, 2000; Miller and Koch, 2020). Because the new avian orthoavulavirus-1 (AOaV-1) terminology is still not widely adopted and World Organisation for Animal Health (*Office International des Epizooties* (OIE)) still uses NDV to refer to virulent APMV-1 viruses, APMV-1 remains the most important pathogen for poultry with the virulent forms of the serotype defined as NDV (Suarez, 2020; OIE, 2023). Newcastle disease (ND) causes considerable impact on the poultry industry worldwide, with significant morbidity and mortality, and high economic losses. Occurrence of ND requires reporting to the OIE and subsequent trade restrictions (Alexander and Senne, 2008; OIE, 2023). Velogenic ND is enzootic in Africa, Middle and Far East (Saidu *et al.*, 2006; Snoeck *et al.*, 2013; Shittu *et al.*, 2016a). The poultry industry in Nigeria is the most capitalized among the Agricultural sectors in the country and contribute the largest to the economy next to the oil industry (Adene and Oguntade, 2006), with poultry identified as a major source of national income that provides about 9–10 % of the nation's gross domestic product (GDP) worth \$250 million (Shittu *et al.*, 2016a). However, ND is enzootic across the entire country (Shittu *et al.*, 2016a) and is ranked first among other diseases

affecting the poultry industry (Echeonwu *et al.*, 1993; Hassan *et al.*, 2013, Shittu *et al.*, 2016a). Newcastle disease affects the respiratory, gastrointestinal, nervous, and reproductive systems in non-vaccinated chickens (Okoye *et al.*, 2000; Igwe *et al.*, 2018a; Miller and Koch, 2020). The virus, NDV, has been documented many times to be transmitted horizontally. Susceptible birds may become infected by inhaling contaminated dust or aerosolized virus (Li *et al.*, 2009), or by ingesting contaminated faeces or contaminated carcasses (Alexander *et al.*, 1985). Infection by inhaling aerosolized virus is illustrated by the success of applying live NDV vaccines using nebulizers, or highly significant morbidity and mortality caused by intranasal inoculation in non-vaccinated birds under experimental infection (Mazija *et al.*, 2010, Igwe *et al.*, 2018b ). Hence, under natural conditions, the virus enters the body through the respiratory tract and also through the digestive tract and starts to multiply in mucosal epithelium resulting in respiratory distress and predominantly diarrhoea. Moreover, unlike in mammals, the avian lung undergoes little change during breathing and consequently, auscultatory signs of pulmonary infection are almost impossible to detect, and damage to the mucosa of upper respiratory tract may enable pathogenic bacteria to reach the lower respiratory tract and establish secondary bacterial infections or predispose to other pathogens (Sato *et al.*, 1970; Fedde, 1998; Hooper *et al.*, 1999; Kotani *et al.*, 1987; Brown *et al.*, 2013), and gastrointestinal disease characterized by proventriculitis or enteritis with consequent impairment of nutrient absorption, decreased efficiency of feed utilization and productivity and this, by itself, is an important source of economic loss (Guy,

2006). Although pathological changes of duck/Nigeria/Plateau/Kuru/ 113/1992, class II, genotype XVII have been well studied in ND affected dead or sick birds, very little is known about the in-depth progressive development of histopathologic changes in the lower respiratory and gastrointestinal tracts in intranasally NDV-infected chickens. In this study, a detailed investigation of the sequential histopathologic changes in these significant target tissues were carried out.

## MATERIALS AND METHODS

This study was scrutinized and approved by Michael Okpara University of Agriculture, Umudike (MOUUAU), Abia State, Nigeria, Committee on Medical and Scientific Research Ethics (Reference number: MOUUAU/CVM/REC/202319).

### Area of Study

The study was carried out in Umudike, Abia State, which is located about 10 kilometers southeast of Umuahia, the state capital, within the Lowland Rain Forest Ecological Zone of Nigeria, between latitude 5°32'N, and longitude 7°29'E; the average rainfall of this zone is 3,500 mm per annum, and the average temperature ranges from 22°C to 32°C (FRoN-UNFCCC, 2019).

### Broiler Chickens

Fifty-day-old White Marshall broiler chicks (*Gallus gallus domesticus*) procured from a reputable local commercial hatchery were used for the study. The chicks were randomly assigned into two groups of 25 birds each as follows: unvaccinated with ND vaccines and intranasally inoculated with vNDV (UC) and unvaccinated and

uninoculated (UU). Brooding was done separately for each of the groups on deep litter and they were not vaccinated against any disease. Feed and water were provided *ad libitum*. The chicks were kept in isolation in the poultry experimental unit of Department of Veterinary Pathology, MOUUAU, under strict biosecurity measures. General care of the birds was provided in accordance with the Institutional Animal Care and Use Committee, as outlined in the Guide for the Care and Use of Agricultural Animals in Agricultural Research and Teaching (Ag Guide, 2020).

### ND Virus Challenge.

The challenge velogenic virus used, duck/Nigeria/Plateau/Kuru/113/1992, class II, genotype XVII (Shittu *et al.*, 2016), was obtained from National Veterinary Research Institute (NVRI), Vom, Nigeria. It was isolated from apparently healthy duck and characterized as velogenic viscerotropic NDV (vvNDV) by Echeonwu *et al.* (1993) and Igwe *et al.* (2014). The inoculum had a median embryo infective dose (EID<sub>50</sub>) of 10<sup>6.4</sup> per millilitre. At 6 weeks of age, the chickens were found to be serologically negative for NDV antibodies by haemagglutination inhibition (HI) test. Each broiler chicken in group UC was inoculated intranasally (I/N) with 0.2 mL of the viral inoculum, while each broiler chicken in group UU received 0.2 mL of phosphate buffered saline (PBS) through the same route as placebo.

### Histopathology

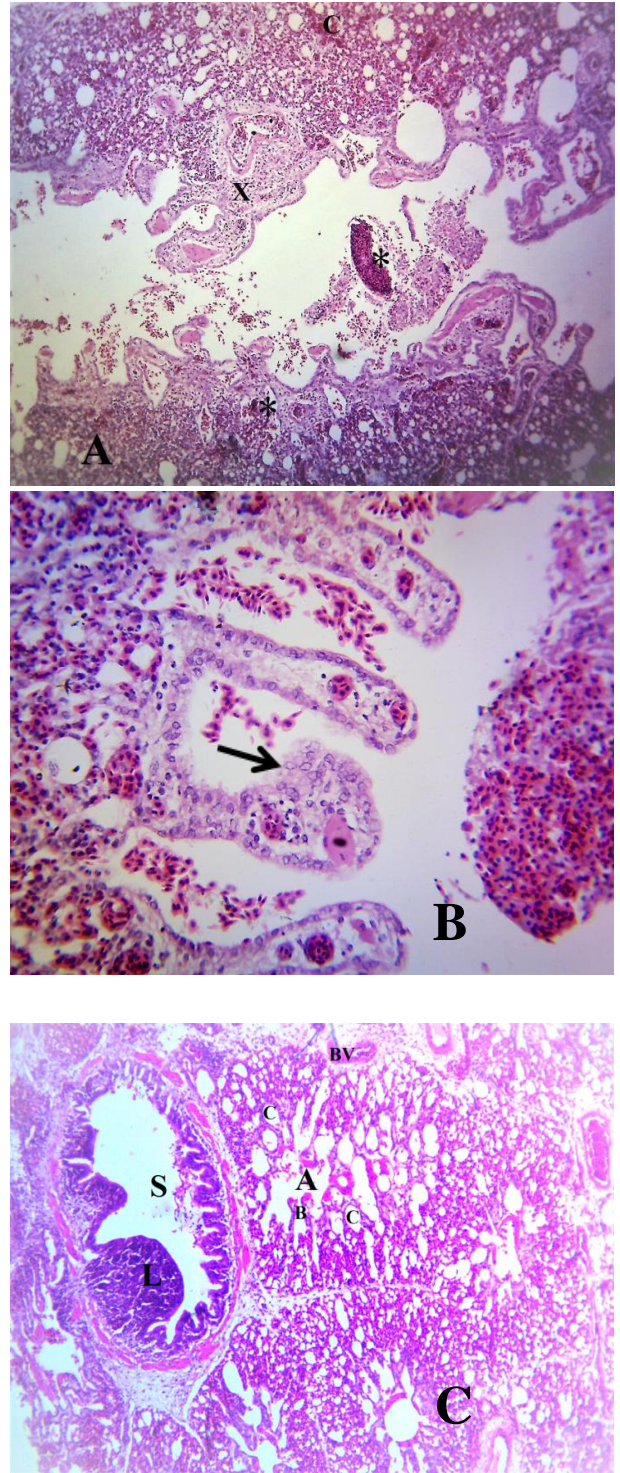
Three birds were euthanized in each group and necropsied along with the dead ones at 4, 5 and 6 days post infection (d.p.i.). For each time period, the lungs, proventriculus and intestines

were harvested immediately post-mortem and fixed in 10% formal saline for 48 hours and processed for histopathology as described by Suvarna *et al.* (2018). Sections (5 µm) were stained with haematoxylin and eosin (HE) staining and examined for histologic lesions under the light microscope.

**RESULTS**

**Histopathology**

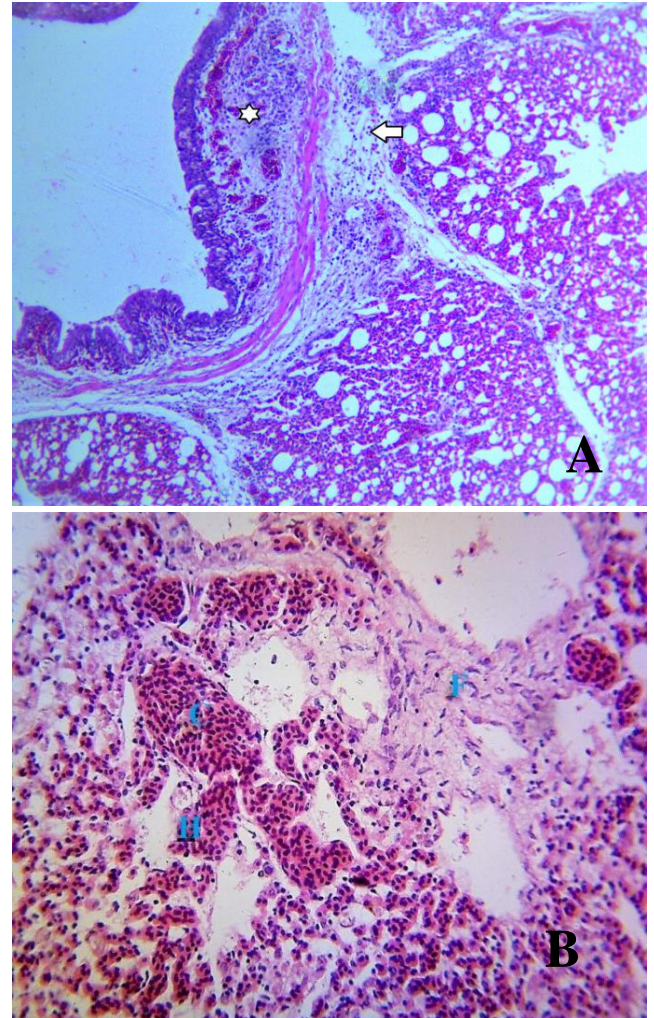
No histopathological changes were found in the unvaccinated, uninfected group. In birds infected with the challenged virus, lesions were severe. The lungs showed diffused hyperaemia, marked inflammatory oedema cellular infiltrates in the bronchi, parabronchi, atria, the funnel-shaped ducts (infundibula) in the floor of atria, lead to the air capillaries of the exchange tissue. The exchange formed by networks of air capillaries and blood capillaries were severely congested and haemorrhagic with inflammatory cellular infiltrates expanding the interstitium of the parabronchi and interatrial septa. At 4 d.p.i., there were epithelial cell hyperplasia of the of the interatrial septa, sloughing of surface epithelial cells with desquamation of the wall, and the lumina of the parabronchi, atria, infundibula contained exudates, degenerated and desquamated epithelia cells and erythrocytes compared with that of uninfected group, control (Plate 1 A, B, C).



**Plate 1:** (A). Lung section of group unvaccinated, infected broiler chicken at 4 d.p.i. Tertiary bronchi (parabronchi), atria and air capillaries are filled with necrotic debris and haemorrhages (\*), air capillaries of the

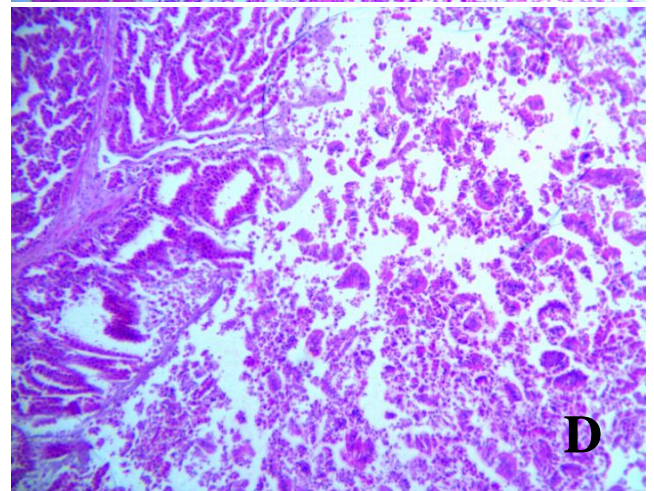
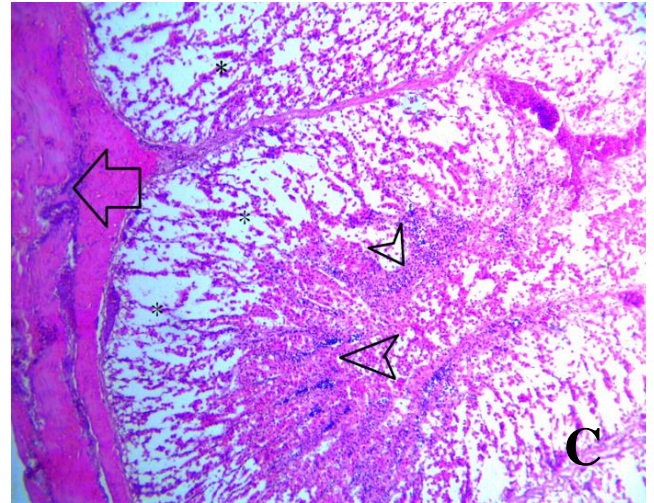
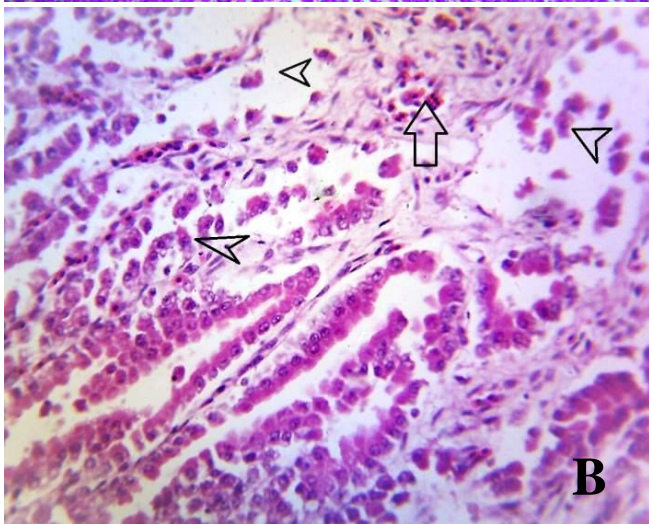
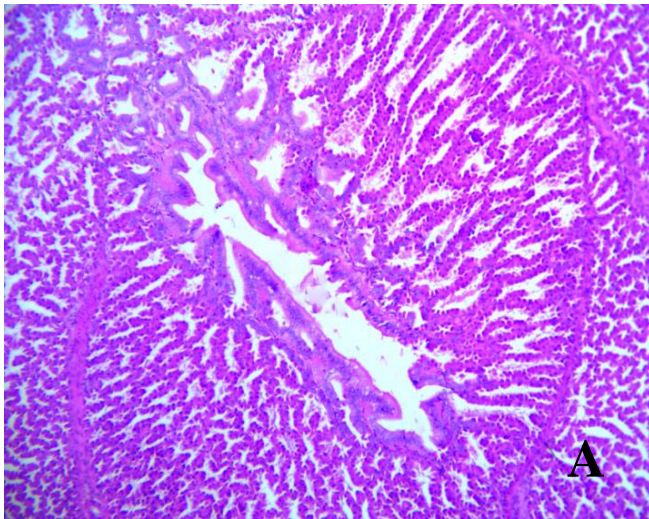
exchange tissues are congested (c) and haemorrhagic and surrounding interstitial tissues expanded by oedema and inflammatory cells (X). H&E, X100 . (B). Higher magnification of (A) showing hyperplastic epithelial layer of interatrial septa (arrow). There were necrotic debris in the lumen of a parabronchus, inflammatory oedema with cellular infiltrates expanding the interatrial septa and the interstitium of the air capillares, and haemorrhages in the atria. H&E, X200. (C). Normal Lung section unvaccinated, uninfected group through a secondary bronchus and parabronchi. The parabronchi are separated by interparabronchial septa. The lumen of each parabronchus is lined by a simple squamous epithelium and communicates with the atria, hence, the Atrium (B) open into the lumen (A) of the parabronchi. The presence of numerous cup-shaped atria in each parabronchus distinguishes this part of the bronchial tree from the secondary bronchus (S) with bronchial-associated-lymphoid tissue (L). Air capillaries (C) surrounded by vascular capillaries open into the atria. H&E, X100.

The lesions progressed to diffuse inflammatory oedema with cellular infiltrates expanding the interstitium, depletion of lymphocytes in the bronchial-associated-lymphoid tissue, deciliation with epithelial cell hyperplasia. The bronchial mucosal epithelia consisted of two to four layers of immature epithelial cells that had deeply basophilic cytoplasm, and lymphocytic infiltration of the mucosa on day 5 d.p.i. There were multifocally collapsed air capillaries, with fibrosis and fibroplasia in areas where many of the air capillaries had collapsed on 6 d.p.i. (Plate 2A, B) and haemorrhages in the parennchyma.



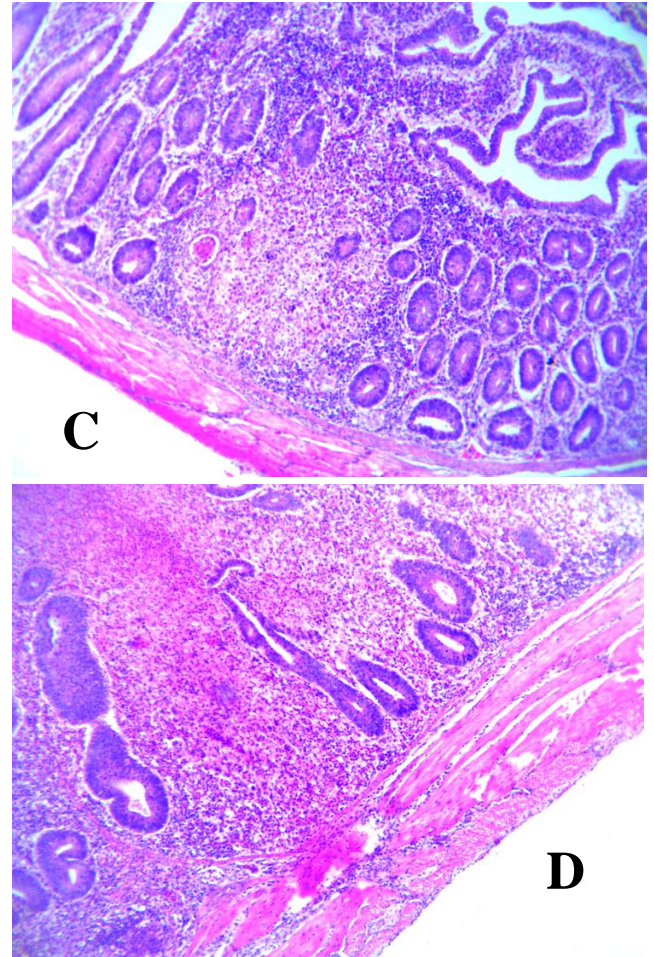
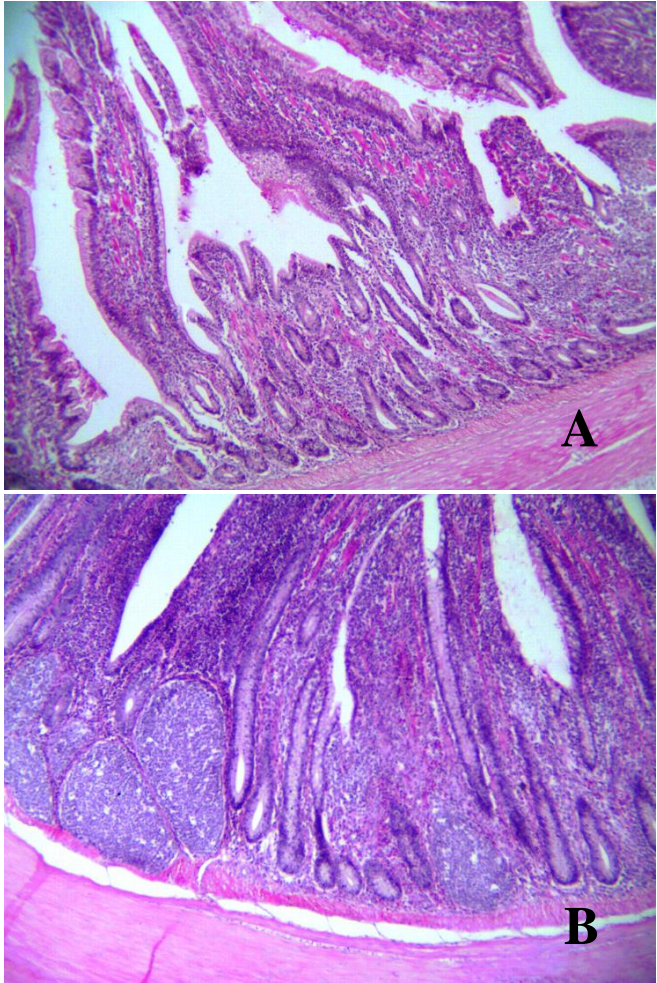
**Plate 2:** (A). Photomicrograph of lung in group unvaccinated, infected broiler chicken showing diffuse inflammatory oedema with cellular infiltrates expanding the interstitium (arrow), depletion of lymphocytes in the bronchial-associated-lymphoid tissue (asteriks) with hyperplastic epithelial layer on day 5 d.p.i. H&E, X200. (B). Unvaccinated, infected broiler chicken's lung section, the parabronchi showing marked hyperaemia (C) with haemorrhages (H), and collapsed air capillaries and fibroplasia of the area (F) at 6 d.p.i. H & E, X200.

In the gastrointestinal tract, the lesions in the proventriculus consisted mainly of slight haemorrhages and congestion with severe inflammatory oedema in the lamina propria, multifocal degeneration with erosion and sloughing of the mucosal folds (plicae) and glandular epithelia at 4 d.p.i. These were followed by severe necrosis and attenuation of the glandular epithelia with dilation of the proventricular glands, and severe diffused haemorrhages admixed necrotic debris in the dilated glands and ducts, and inflammatory cellular infiltrates in the submucosa on 5 d.p.i.. Severe necrosis and disintegration of the proventricular glands were observed on 6 d.p.i. (Plate 3A, B, C, D).



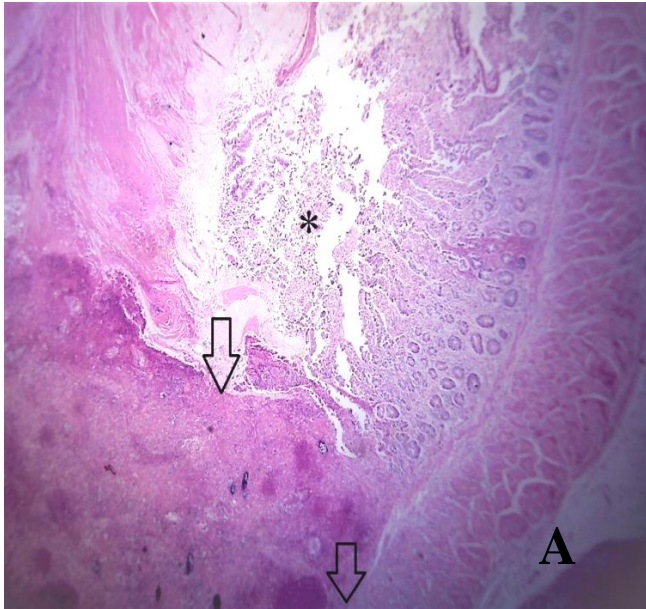
**Plate 3:** (A). Section of the proventriculus with the glands of unvaccinated, uninfected broiler chicken showing normal histologic architecture. H&E, X100. (B). Proventriculus showing inflammatory oedema (arrow heads) with mild haemorrhages in the lamina propria (arrow) and degeneration, erosion and sloughing of the epithelial of proventricular gland (middle arrow head) at 4 d.p.i. H&E, X200. (C). Necrosis, and attenuation of the glandular epithelia with dilation of the proventricular glands (\*) and severe diffused haemorrhages admixed necrotic debris in the ducts (arrow heads), and inflammatory cellular infiltrates in the loose connective tissue of the very thin submucosa (arrow) on 5 d.p.i.. H&E, X100. (D) Severe necrosis and disintegration of the proventricular glands on 6 d.p.i. H&E, X100.

The lesions in the intestine consisted mainly of deciliated epithelium on the mucosal surface. Some areas of depletion of gut-associated lymphoid tissues, and inflammatory oedema with infiltration of inflammatory cells which expanded the lamina propria. Inflammatory cellular infiltrates in the submucosa and tunica muscularis, were observed at 4 d.p.i (Plate 4A, B, C, D).



**Plate 4:** (A, B). Photomicrograph of the wall of jejunum and ileum in unvaccinated uninfected group showing normal architecture. (C, D) Photomicrograph of jejunum and ileum in unvaccinated infected group showing loss of cilia and depletion of the lymphoid tissues in the lamina propria with infiltration of inflammatory cells in the tunica muscularis on 4 d.p.i. H&E, X100.

These were followed by more severe lesions which consisted mainly of severe congestion, haemorrhages and ulcerative enteritis with the intestinal lumen filled with fibrin and necrotic debris at 5 d.p.i (Plate 5A, B).



**Plate 5: (A).** Small intestinal section from the ileum of a dead unvaccinated infected group showing severe ulcerative enteritis characterized by large, deep necrotic ulcers that extended deep into the tunica muscularis (arrow) at 5 d.p.i.. The lumen is filled with fibrin and necrotic debris (\*). H&E, X40.

## DISCUSSION

In the present study, severe histopathologic changes occurred in the lower respiratory and gastrointestinal tracts of non-vaccinated birds infected with the velogenic NDV strain used, indicating that velogenic NDV infection is associated with severe systemic disease in the respiratory and gastrointestinal systems in non-vaccinated susceptible chickens. Susceptible birds may become infected by inhaling contaminated dust or aerosolized virus (Li *et al.*, 2009), or by ingesting contaminated feeds or contaminated carcasses (Alexander *et al.*, 1985) which will be accompanied by high morbidity and high flock mortality ((Okoye *et al.*, 2000; Igwe *et al.*, 2018b). The microscopic lesions observed at the early stages in the lower respiratory system were

congestion, haemorrhages, oedema, vascular damage in blood capillaries and cellular infiltrations, and are similar to those described in chickens infected intranasally by Kabiraj *et al.* (2020). However, in the present study, epithelial cell hyperplasia of the of the interatrial septa, necrotic debris in the lumen of the parabronchi and atria were observed at 4 d.p.i. These lesions became increasingly severe with depletion of bronchial associated lymphoid tissues (BALT) in the lamina propria at 5 d.p.i, deciliation of epithelial cells associated with bronchial epithelial cell hyperplasia. The bronchial mucosal epithelia consisted of two to four layers of immature epithelial cells that had abundant basophilic cytoplasm. Lung lesions observed in the infected chickens indicated primary predilection of NDV to the respiratory system. NDV antigen has been detected in lungs in other studies (Nakamura *et al.*, 2008; Susta *et al.*, 2011; Etriwati *et al.*, 2017). Viruses attach to the respiratory epithelial cells by utilizing sialic acid receptor (Wen *et al.*, 2016). The trachea, primary bronchi, and the roots of the secondary bronchi are lined mostly with ciliated columnar epithelial cells, and the lumen of the parabronchi which communicates with the atria is lined by a simple squamous epithelium (McLelland, 1990a). Inhaled foreign particles are removed by nasal mucociliary action, by the mucociliary escalator in the trachea, primary bronchi, and secondary bronchi. Small particles that enter parabronchi appear to be phagocytized by the squamous epithelial cells in the atria and infundibulum (Fedde, 1998). Hence, in the present study the histopathologies observed could be explained by; NDV replication in the lung induces deciliation, damage and impairment of the muco-ciliary escalator and cellular defense (lymphoid depletion of BALT) of the birds respiratory system and probably some other lymphoid organ,



weakening the protective defenses of the lining, thereby, affecting the respiration, gas exchange in parabronchi and the general function of the birds respiratory system. Epithelial cell hyperplasia observed in the bronchi is suggested to be a non-specific response to damage of the mature cells. In contrast, Okoye *et al.* (2000) reported that the lungs of chickens infected intramuscularly with a velogenic NDV isolated from Guinea fowl showed no lesion. Beard and Hanson (1984) reported that the intramuscular, intravenous and intra-cerebral routes appeared to enhance the neurological signs while the natural routes (oral, intra-ocular and nasal) emphasized respiratory involvement. Histopathologically, gastrointestinal tract, and particularly at gut associated lymphoid tissues (GALT) showed severe changes comparable to the changes typical of viscerotropic velogenic ND in experimental infections (Okoye *et al.*, 2000; Susta *et al.*, 2011; Igwe *et al.*, 2018b; Kabiraj *et al.*, 2020), and most outbreaks of ND in village chickens transmitted through ingestion of contaminated feed (Martin, 1992). Although, the gross lesions in the gastrointestinal, and the associated lymphoid tissues have been well reported in experimental and natural ND studies (Kabiraj *et al.*, 2020), however, these reports did not investigate or evaluate a comprehensive sequential histopathological changes associated with velogenic ND. In the proventriculus, initial changes characterized by diffuse inflammatory oedema, congestion, severe haemorrhages, and cellular infiltrates were observed in the mucosal and submucosal layers of the proventriculus, though not in the gizzard at 4 to 5 d.p.i. These lesions progressed to severe necrosis and disintegration of the columnar mucus-secreting epithelia of the plicae and glandular epithelium which secretes both the pepsin and hydrochloric acid on 6 d.p.i. In the intestines, haemorrhagic and necrotizing and ulcerative lesions were the most

predominant lesion with inflammatory oedema and leucocytic infiltration, and the severe necrosis of the lymphoid-dependent areas was associated with focal to locally extensive ulceration of the epithelium and accumulation of necrotic material within the intestinal lumen at 4 to 6 d.p.i., resulting in proventriculitis and enteritis. These histopathologic evaluations of ND in the gastrointestinal tract of non-vaccinated birds has an important role in explaining weight loss and greenish diarrhoea observed in experimental infections and natural outbreaks in susceptible birds. The proventriculus is responsible for the production of digestive secretions (secretes mucus, hydrochloric acid, and pepsinogen), and villous enterocytes are responsible for both digestion (production of disaccharidases, peptidases, etc.) and absorption of nutrients and water (McLelland, 1990b; Guy, 2006; Proszkowiec-Weglarz, 2022). Extensive replication of the velogenic NDV has been described in the digestive tract (Nakamura *et al.*, 2008; Susta *et al.*, 2011; Mariappan *et al.*, 2018). In the present study we did not evaluate the presence of the virus to demonstrate the tropism this virus have to the layers in the gastrointestinal tract, and GALT, however, we demonstrated and described the sequential histopathologic changes. Therefore, the histologic lesions showed that the proventriculitis resulted from viral replication and damage in the proventricular mucosal linings (plicae) and proventricular glandular epithelium, with consequent impairment of pepsinogen and hydrochloric acid synthesis and impaired nutrient absorption. Decreased activities of the digestive enzyme may be related to poor production performance after NDV outbreaks in commercial poultry. The severe enteritis reflects the severe viral replication and damage in the intestinal wall (mucosa, submucosa and serosa), with consequent impairment of digestion and

absorption of nutrients, while the immunosuppression predisposing to subsequent high mortality in field situations in velogenic NDV infection could be explained by the lymphoid depletion and atrophy of the lymphoid aggregates of the wall of the intestine, GALT, and other lymphoid organs.

## CONCLUSION

This study fully characterized the lower respiratory and gastrointestinal tract lesions through histopathological observation of the velogenic NDV strain, duck/Nigeria/Plateau/Kuru/113/1992, class II, genotype XVII in infected chickens. The information derived from this study will be helpful in the accurate diagnosis of velogenic Newcastle disease in chickens.

## REFERENCES

- ADENE, D. and OGUNTADE, A. (2006): The structure and importance of the commercial and village based poultry industry in Nigeria. Nigerian Poultry Sector Report. Rome; <http://www.fao.org/docs/eims/upload//214281/ReviewNigeria>.
- AG GUIDE (2020): Guide for the Care and Use of Agricultural Animals in Research and Teaching, 4<sup>th</sup> Ed. The American Dairy Science Association®, the American Society of Animal Science, and the Poultry Science Association, Champaign, Illinois, USA: 1–209.
- ALEXANDER, D.J., WILSON, G.W.C., RUSSELL, P.H., LISTER, S.A. and PARSONS, G. (1985): Newcastle disease outbreaks in fowl in Great Britain during 1984. *Veterinary Record*, 117:429–434.
- ALEXANDER, D.J. (2000): Newcastle disease and other avian paramyxoviruses. *Revue scientifique et technique (International Office of Epizootics)*, 19(2): 443–462.
- ALEXANDER, D.J. and SENNE, D.A. (2008): Newcastle Disease Virus and other Avian Paramyxoviruses. In: *A laboratory Manual for the Isolation and Identification and Characterization of Avian Pathogens*, 5<sup>th</sup> Ed. L. Dufour Zavala, D.E. Swayne, J.R. Glisson, M.W. Jackwood, J.E. Pearson, W.M. Reed and P. Woolcock, American Association of Avian Pathologists: Athens, GA.: 156–163.
- AMARASINGHE, G.K., AYLLÓN, M.A., BÀO, Y., BASLER, C.F., BAVARI, S., BLASDELL, K.R., BRIESE, T., BROWN, P.A., BUKREYEV, A., BALKEMA-BUSCHMANN, A., BUCHHOLZ, U.J., CHABI-JESUS, C., CHANDRAN K., CHIAPPONI, C., CROZIER, I., de SWART, R.L., DIETZGEN, R.G., DOLNIK, O., DREXLER, J.F., DÜRRWALD, R., DUNDON, W.G., DUPREX, W.P., DYE, J.M., EASTON, A.J., FOOKS, A.R., FORMENTY, P.B.H., FOUCHIER, R.A.M., FREITAS ASTÚA, J., GRIFFITHS, A., HEWSON, R., HORIE, M., HYNDMAN, T.H., JIANG, D., KITAJIMA, E.W., KOBINGER, G.P., KONDŌ, H., KURATH, G., KUZMIN, I.V., LAMB, R.A., LAVAZZA, A., LEE, B., LELLI, D., LEROY, E.M., LĚ, J., MAES, P.,

- MARZANO, S.L., MORENO, A., MÜHLBERGER, E., NETESOV, S.V., NOWOTNY, N., NYLUND, A., ØKLAND, A.L., PALACIOS, G., PÁLYI, B., PAWEŚKA, J.T., PAYNE, S.L., PROSPERI, A., RAMOS-GONZÁLEZ, P.L., RIMA, B.K., ROTA, P., RUBBENSTROTH, D., SHĪ, M., SIMMONDS, P., SMITHER, S.J., SOZZI, E., SPANN, K., STENGLEIN, M.D., STONE, D.M., TAKADA, A., TESH, R.B., TOMONAGA, K., TORDO, N., TOWNER, J.S., van den HOOGEN, B., VASILAKIS, N., WAHL, V., WALKER, P.J., WANG, L.F., WHITFIELD, A.E., WILLIAMS, J.V., ZERBINI, F.M., ZHĀNG, T., ZHANG, Y.Z. and KUHN, J.H. (2019): Taxonomy of the order *Mononegavirales*: update 2019. *Archives of Virology*, 164(7): 1967–1980.
- BEARD, C.W. and HANSON, R.P. (1984): Newcastle disease and other Paramyxoviridae infections. In: *Diseases of Poultry*, 8<sup>th</sup> Ed. M.S. Hofstad, H.J. Barnes, B.W. Calnek, W.S. Reid and H.J. Barnes, Iowa State University Press, Ames, IA, USA: 452–470.
- BROWN, C.C., SULLIVAN, L., DUFOUR-ZAVALA, L., KULKARNI, A., WILLIAMS, S., SUSTA, L., ZHANG, J. and SELLERS, H. (2013): Comparing presence of avian paramyxovirus-1 through immunohistochemistry in tracheas of experimentally and naturally infected chickens. *Avian Diseases*, 57(1): 36–40.
- ECHEONWU, G.O.N., IROEGBU, C.U. and EMERUWA, A.C. (1993): Recovery of velogenic Newcastle disease virus from dead and healthy free roaming birds in Nigeria. *Avian Pathology*, 22: 383–387.
- ETRIWATI, D.R., HANDHARYANI, E. and SETIYANINGSIH, S. (2017): Pathology and immunohistochemistry study of Newcastle disease field case in chicken in Indonesia. *Veterinary World*, 10(9): 1066–1071.
- FEDDE, M.R. (1998): Relationship of Structure and Function of the Avian Respiratory System to Disease Susceptibility. *Poultry Science*, 77(8): 1130–1138.
- GUY, J.S (2006): Pathology. In: *Avian Gut Function in Health and Disease*, 1<sup>st</sup> Ed. G.C. PERRY, CABI Abingdon, Oxfordshire (OX), UK: 227–243.
- HASSAN, D.I., YUSUF, N.D., MUSA-AZARA, I.S., ARI, M.M., OGAH, D.M., ALAGA, A.A. and ELAYO, S.A. (2013): Prevalence of Newcastle disease in village chickens reared in Lafia, Nasarawa State, Nigeria. *Egyptian Poultry Science Journal*, 33(1): 135–142.
- HOOPER, P.T., HANSSON, E., YOUNG, J.G., RUSSELL, G.M. and DELLA-PORTA, A.J. (1999): Lesions in the upper respiratory tract in chickens experimentally infected with Newcastle disease viruses isolated in Australia. *Australian Veterinary Journal* 77( 1): 50–51.
- IGWE, A.O., EZEMA, W.S., EZE, D.C. and OKOYE, J.O.A (2014): Experimental velogenic Newcastle disease can be very

severe and viscerotropic in chickens but moderate and neurotropic in guinea fowls. *International Journal of Poultry Science*, 13(10): 582–590.

- IGWE, A.O., AFONSO, C.L., EZEMA. W.S., BROWN, C.C. and OKOYE, J.O.A. (2018a): Pathology and distribution of velogenic viscerotropic Newcastle disease virus in the reproductive system of vaccinated and unvaccinated laying hens (*Gallus gallus domesticus*) by immunohistochemical labelling. *Journal of Comparative Pathology*, 159(2): 36–48.
- IGWE, A.O., SHITTU, I. and Okoye, J.O.A. (2018b): Response of cyclophosphamide treated broiler chickens to challenge with velogenic Newcastle disease virus. *Journal of Applied Animal Research*, 46(1): 938–946.
- KABIRAJ, C. K., MUMU, T. T., CHOWDHURY, E. H., ISLAM, M. R., and NOORUZZAMAN, M. (2020): Sequential pathology of a Genotype XIII Newcastle disease virus from Bangladesh in chickens on experimental infection. *Pathogens (Basel, Switzerland)*, 9(7), 539. <https://doi.org/10.3390/pathogens9070539>
- KOTANI, T., ODAGIRI, Y., NAKAMURA, J. and HORIUCHI, T. (1987): Pathological Changes of Tracheal Mucosa in Chickens Infected with Lentogenic Newcastle Disease Virus. *Avian Diseases* 31(3): 491–497.
- LI, X., CHAI T., WANG, Z., SONG, C., CAO, H., LIU, J., ZHANG, X., WANG, W., YAO, M. and MIAO, Z. (2009): Occurrence and transmission of Newcastle disease virus aerosol originating from infected chickens under experimental conditions. *Veterinary Microbiology*, 136:226–232.
- McLELLAND, J. (1990a): Respiratory System. In : *A Colour Atlas of Avian Anatomy*, Wolfe Publishing Ltd, London, UK: 95–119.
- McLELLAND, J. (1990b): Digestive system. In: *A Colour Atlas of Avian Anatomy*, Wolfe Publishing Ltd, London, UK: 47–65.
- MARIAPPAN, A.K., MUNUSAMY, P., KUMAR, D., LATHEEF, S.K., SINGH, S.D., SINGH, R., and DHAMA, K. (2018): Pathological and molecular investigation of velogenic viscerotropic Newcastle disease outbreak in a vaccinated chicken flocks. *Virusdisease*, 29(2): 180–191. <https://doi.org/10.1007/s13337-0180445-5>
- MARTIN, P.A.J. (1992): The epidemiology of Newcastle disease in village chickens. In: *Newcastle disease in village chickens, control with thermostable oral vaccines*. Spradbrow P.B., ACIAR, Canberra, Australia: 40–45.
- MAZIJA, H., ČAJAVEC, S., ERGOTIĆ, N., CIGLAR-GROZDANIĆ, I, GOTTSTEIN, Z. and RAGLAND, W.L. (2010): Immunogenicity and safety of Queensland V4 and Ulster 2C strains of Newcastle disease virus given to maternally immune, newly hatched chickens by nebulization. *Avian*

- Diseases*, 54(1): 99–103.
- MILLER, P. J. and KOCH, G. (2020): Newcastle Disease. In: *Diseases of Poultry*, 14<sup>th</sup> Ed. D.E. Swayne, M. Boulianne, C.M. Logue, L.R. McDougald, V. Nair and D.L. Suarez, Wiley-Blackwell, Hoboken, NJ, USA: 140–156.
- NAKAMURA, K., OHTSU, N., NAKAMURA, T., YAMAMOTO, Y., YAMADA, M., MASE, M. and IMAI, K. (2008): Pathologic and immunohistochemical studies of Newcastle disease (ND) in broiler chickens vaccinated with ND: Severe nonpurulent encephalitis and necrotizing pancreatitis. *Veterinary Pathology*, 45(6): 928–933.
- OKOYE, J.O.A., AGU, A.O., CHINEME, C.N. and ECHEONWU, G.O.N. (2000): Pathological characterization in chickens of a velogenic Newcastle disease virus isolated from guinea fowl. *Revue d'Élevage et de Médecine Vétérinaire des PaysTropicaux* 53(4): 325–330.
- PROSZKOWIEC-WEGLARZ, M. (2022): Gastrointestinal Anatomy and Physiology. In: *Sturkie's Avian Physiology* 7<sup>th</sup> Ed. C.G. Scanes, Academic Press, Elsevier Inc., San Diego, California, USA: 485–527.
- SAI'DU, L., ABDU, P.A., TEKDEK, L.B., UMOH, J.U., USMAN, M. and OLADELE, S.B. (2006): Newcastle Disease in Nigeria. *Nigerian Veterinary Journal*, 27: 23–32.
- SATO, S., NONOMURA, I., SHIMIZU, F., SHOYA, S. and HORIUCHI, T. (1970): Mixed infection with *Mycoplasma gallisepticum* and the B1 strain of Newcastle disease virus in chickens. *National Institute of Animal Health quarterly*, 10(2): 58–65.
- SHITTU, I., JOANNIS, T.M., ODAIBO, G. N. and OLALEYE, O. D. (2016a): Newcastle disease in Nigeria: epizootiology and current knowledge of circulating genotypes. *VirusDisease*, 27(4): 329–339.
- SHITTU, I., SHARMA, P., JOANNIS, T.M., VOLKENING, J.D., ODAIBO, G.N., OLALEYE, D.O., WILLIAMS-COPLIN, D., SOLOMON, P., ABOLNIK, C., MILLER, P.J., DIMITROV, K.M. and AFONSO, C.L. (2016b): Complete genome sequence of a genotype XVII Newcastle disease virus, isolated from an apparently healthy domestic duck in Nigeria. *Genome Announc.* 4(1):e01716–15. doi:10.1128/genomeA.01716-15.
- SNOECK, C.J., OWOADE, A.A., COUACY-HYMAN, E., ALKALI, B.R., OKWEN, M.P., ADEYANJU, A.T., KOMOYO, G.F., NAKOUNÉ, E., LE FAOU, A. and MULLER, C.P. (2013): High genetic diversity of Newcastle disease virus in poultry in West and Central Africa: cocirculation of genotype XIV and newly defined genotypes XVII and XVIII. *Journal of Clinical Microbiology*, 51(7): 2250–2260. <https://doi.org/10.1128/JCM.00684-13>
- SUAREZ, D.L. (2020): Newcastle Disease, other Avian Paramyxoviruses, and Avian Metapneumovirus Infections. In: *Diseases*

of *Poultry*, 14<sup>th</sup> Ed. D.E Swayne, M. Boulianne, C.M Logue, L.R McDougald, V. Nair and D.L Suarez, Wiley-Blackwell, Hoboken, NJ, USA: 139–140.

SUSTA, L., MILLER, P. J., AFONSO, C. L., and BROWN, C. C. (2011): Clinicopathological characterization in poultry of three strains of Newcastle disease virus isolated from recent outbreaks. *Veterinary Pathology*, 48(2): 349–360.

SUVARNA, K.S., LAYTON, C. and BANCROFT, J.D. (2018): *Bancroft's Theory and Practice of Histological Techniques*, 8<sup>th</sup> Ed. Oxford, UK: Elsevier.

WEN, G., HU, X., ZHAO, K., WANG, H., ZHANG, Z., ZHANG, T., YANG, J., LUO, Q., ZHANG, R., PAN, Z., SHAO, H., and YU, Q. (2016): Molecular basis for the thermostability of Newcastle disease virus. *Scientific Reports*, 6: 22492. <https://doi.org/10.1038/srep22492>

WOAH (2023): Newcastle Disease. Terrestrial Animal Health Code, 2023 [Internet]. [retrieved 2023 July 2]. Paris: World Organisation for Animal Health. Available from: [https://www.woah.org/en/what-we-do/standards/codes-and-manuals/terrestrial-code-online-access/?id=169&L=1&htmfile=chapitre\\_n\\_d.htm](https://www.woah.org/en/what-we-do/standards/codes-and-manuals/terrestrial-code-online-access/?id=169&L=1&htmfile=chapitre_n_d.htm)