



COMPARATIVE PREGNANCY DIAGNOSIS OF DIGITAL RECTAL PALPATION TECHNIQUE, ULTRASONOGRAPHY, PROGESTERONE ASSAY AND NON-RETURN-TO-HEAT IN RED SOKOTO GOAT.

Bello, A. A^{1*}; Voh Jr, A. A²; Ogwu, D¹; and Ayo, J. O³.

¹Department of Theriogenology and Production, Faculty of Veterinary Medicine, Ahmadu Bello University, Zaria. ²National Animal Production Research Institute, Shika, Ahmadu Bello University, Zaria. ³Department of Veterinary Physiology, Faculty of Veterinary Medicine, Ahmadu Bello University, Zaria.

*Corresponding author: Email: adehabello@abu.edu.ng; Tel No: +234 803 615 3483.

ABSTRACT

Comparative pregnancy diagnosis was carried out to evaluation the effectiveness of digital rectal palpation technique in Red Sokoto goat, at Small Ruminant Research Program of National Animal Production Research Institute, Shika, Zaria. Forty two does were randomly divided into groups A, B and C, (n = 14 each). Semen was collected from two Red Sokoto bucks using artificial vagina, processed and stored at 4°C. Oestrus was synchronised with prostaglandin F₂-alpha, and oestrus detected by apronised bucks and visual observation. Breeding was by artificial inseminating for groups A and B while group C bred by natural service. Comparative pregnancy diagnosis was carried out using ultrasonography (US) and digital rectal palpation technique (DRP) on day 14, 21, 28 and 126, while progesterone assay (P4) and non-return-to-heat (NRH) on day 21, post-breeding. Pregnancy rates on day 21 were 64.3 %, 92.9 % and 100 % (US); 42.9 %, 57.1 % and 57.1 % (DRP); 78.6 %, 78.6 % and 100 % (P4); 85.7 %, 78.6 % and 92.9 % (NRH). There was significant ($P < 0.05$) difference between US, DRP, P4 and NRH in groups B and C. It was concluded that DRP technique was effective in early pregnancy diagnosis (days 14, 21, and 28) in Red Sokoto goat does.

Keywords: Comparative; Pregnancy; Diagnosis; Digital Rectal Palpation Technique; Goat;

INTRODUCTION

Pregnancy examination in goats may be requested by the owner. Perhaps, the most important reason for pregnancy diagnosis is the detection of non-pregnancy, pseudo-pregnancy or hydrometra, which may occur in pet and commercial goats, especially in dairy herds where breeding is delayed to adjust for milk supplies (Dawson, 1999; Dawson, 2002; Karadaev, 2015; David, 2016; Lone, 2016). A reliable technique for early detection of pregnancy would allow early culling, rebreeding or re-selling to reduce feed expenses; while non-pregnant yearling does could be marketed at a higher price than mature does (Dawson, 1999; Karen *et al.*, 2001). Separation of the goat herd into pregnant and non-pregnant females may reduce reproductive and production losses in the form of abortions, still-births and production of weak kids (Dawson, 1999; Karen *et al.*, 2001). On the other hand, does pronounced open or pseudo-pregnant are often culled or given luteolytic substances to induce oestrus; hence, great emphasis is placed on a highly accurate pregnancy diagnostic test (Dawson, 1999; Dawson, 2002) that may be used in the field. Hence, an on-farm, simple, reliable, affordable and accurate method of pregnancy diagnosis in goats has become imperative (Bello *et al.*, 2022a). The objective of the research was to carry out comparatively pregnancy diagnosis using digital rectal palpation (DRP) technique, ultrasonography, progesterone assay and non-return-to-heat to evaluate effectiveness of DRP technique in red Sokoto goat.

MATERIALS AND METHODS

Location

The experiment was conducted at Small Ruminant

Research Programme of National Animal Production Research Institute (NAPRI), Shika, Ahmadu Bello University Zaria, Nigeria. Shika is located in Northern Guinea Savannah zone between latitude 11° 12'N and longitude 7° 33'E, and altitude of 640 M above sea level. It has an average annual rainfall of 1041 (617 to 1365) mm, most of which falls from June to October. Daily ambient temperature ranges from 14 to 30° C, with average relative humidity of 21% during the harmattan season. Average ambient temperature and relative humidity during the wet season are 25° C and 72%, respectively, (Malau-Aduli, 1996; Abeke *et al.*, 2008).

Experimental Animals

A total of 51 animals with 42 does and 9 bucks were used for the experiment. The does were matured adult, non-pregnant, pluriparous (two to three parities), aged 18 to 36 months, weighed 20 to 40 kg and with body condition score (BCS) of 3 to 4 (scale: 1 to 5). The bucks were matured adults, aged 18 to 36 months, weighed 20 to 30 kg and BCS of 3 to 4. Six bucks were used for breeding while three for oestrus detection (Voh Jr., 1996).

Animal grouping

After a balanced distribution of parity, age, weight and body condition score, animals were grouped into three groups of 14 does each by simple random sampling:

Group A: Artificial insemination by digital rectal palpation technique (AIDRP)

Group B: Artificial insemination by vaginal speculum method (AIVSM)

Group C: Natural service (NS) - Control

Each group had one apronised buck introduced for heat detection. Breeder bucks for the control were kept separately in a different pen.

Feeds and feeding

Animals were confined and fed concentrate and hay (*Digitaria smutsi*). The concentrate ration had a metabolisable energy (ME) of 11.68 mJ/kg dry matter (DM) and 15% crude protein (CP) made up of maize (*Zea mays*), maize offal, wheat offal and cotton seed cake, with salt added at 2%. The ration was fed twice daily at 09:00 h and 16:00 h, at a feeding regime of 50:50 ratio of grass to concentrate at an average of 23.8 g/animal/day of concentrate. The goats were given access to water and mineralized salt lick *ad libitum*.

Animal restraint

Restraint of animals for breeding by artificial insemination and pregnancy diagnosis by digital rectal palpation technique was carried out by an attendant with doe restrained in standing position, between legs and holding the head. Restraint for weight was by carrying the doe upward and held at level of the chest by an attendant standing on bath room weighing scale. Weight of doe was obtained by subtracting weight of attendant from total weight of attendant and doe.

Digital rectal palpation technique

Digital rectal palpation (DRP) technique was carried out as reported by (Kutty, 1999) with some modifications of using the right index finger and sitting on the left side of the animal for examination (Bello, 2019; Bello *et al.*, 2021). As examiner, sitting at the level of pelvic region on the left side of the animal, tail of doe was raised with left hand;

index (first) finger of gloved and lubricated right hand was inserted into the rectum and faecal pellets were removed. Tail was released and same left hand moved to the pelvic region of posterior abdomen to evacuate a distended urinary bladder by gentle recto-abdominal pressure and to stabilize the internal genitalia within the pelvic cavity, resulting in a bi-manual examination. The left palm was held vertically, with the finger tips touching the ventral floor of the posterior abdomen; it was then lifted upwards to move abdominal organs cranially. Then, using regulated forward, upward and backward movements, the cervix as land-mark structure was identified and position maintained on pelvic floor with the finger, and the reproductive tract within the pelvic cavity was held in the palm of the left hand. Examination was performed per rectum using the index finger assisted by the fingers of the left hand (Fig. 1 and Plate I).

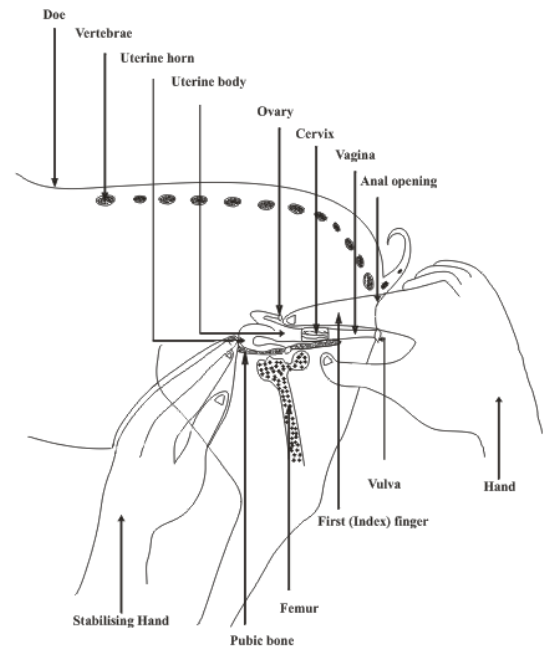


Figure 1: Schematic illustration of digital rectal palpation technique in Red Sokoto Goat doe. Bello *et al.* (2022a).

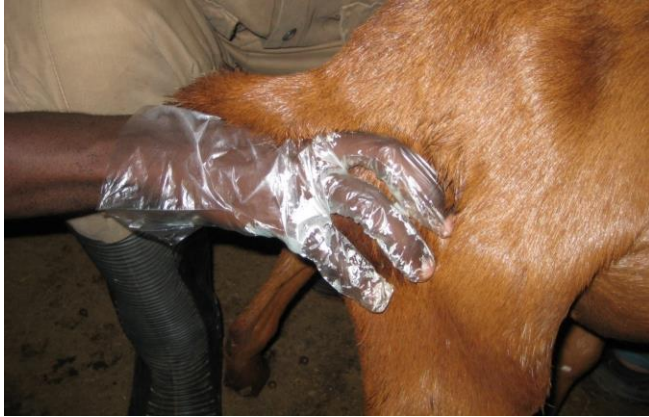

Plate I: Pregnancy diagnosis using Digital Rectal Palpation in Red Sokoto goat doe.

Using the cervix as a land-mark for identification of segments of the genitalia, the palpability, size, shape, consistency and surface characteristics of the vagina, cervix, uterus and ovary were assessed (Kutty, 1999; Bello *et al.*, 2021). Precautions observed for the procedure: examination was carried out before feeding and watering; fecal pellets were evacuated from the rectum; urinary bladder was emptied before examination.

Semen Collection

Semen was collected at the experimental site from two selected breeding bucks using the artificial vagina (AV). The semen was evaluated, processed and storage was at 4° C.

Oestrus synchronization and detection

Oestrus was synchronized with prostaglandin F₂-alpha (PGF₂α; *Dinoprost tromethamine*, Lutalyse®) for all the does in groups A, B, and C. The animals were treated with 12.5 mg per animal by deep intramuscular, double injection, 12 days apart, protocol (Voh Jr., 1996; Bello; 2019). Three mature bucks (one per group) that demonstrated high libido were apronised and used for oestrus detection.

Breeding of animals

Does detected in oestrus were bred following second PGF₂α injection by artificial insemination (groups A and B) and by natural service (group C).

Artificial insemination

Artificial insemination (AI) gun size 0.5 ml was used to inseminate does. Insemination was done 12 h after detecting standing oestrus. Site for semen deposition was intracervical. Double insemination protocol (0.5 ml per insemination), 12 h apart was adopted (Leethongdee and Ponglowhapan, 2014; Farin, 2015; Bello *et al.*, 2022b).

Group A (Recto-vaginal AI by DRP technique): Does were restrained standing by an assistant and foecal pellets and urine evacuated as described earlier in digital rectal palpation technique. Insemination was achieved by insertion of a gloved lubricated left index finger into the rectum to palpate and locate the cervix, while the right hand manipulated entry of AI gun per vagina into the cervix to deposit the semen (Fig. 2) (Bello *et al.*, 2022b).

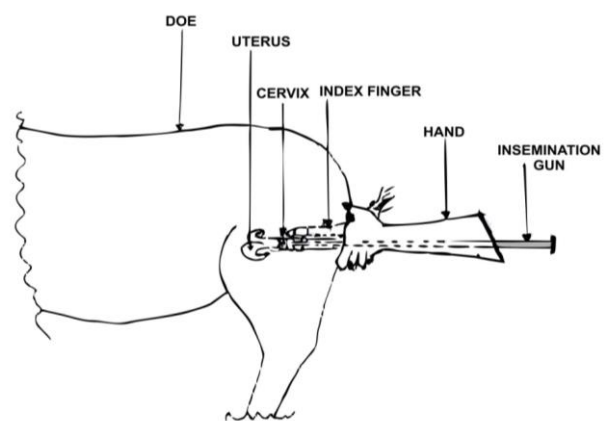


Figure 2: Schematic illustration of recto-vaginal artificial insemination using Digital Rectal Palpation technique in a Red Sokoto goat doe - Cervix located and used as site for semen deposition. Source: Bello *et al.* (2022b).

Group B (Vaginal AI): Does were restrained in a similar manner as in group A, except that the hind quarters were raised, and a lubricated small ruminant vaginal speculum inserted into the vagina (Leethongdee and Ponglowhapan, 2014; Farin, 2015; Bello *et al.*, 2022b). A flash light was used to locate *os-cervix externa* for entry and manipulation into the cervix to deposit the semen.

Natural Service

Group C (Natural Service): Does were bred by natural service using hand mating breeding method, twice, 12 h apart, following detected oestrus. Breeding was monitored until mating was confirmed by observing ejaculatory thrust.

PREGNANCY DIAGNOSIS

Digital rectal palpation

Digital rectal palpation (DRP) technique was used to diagnose pregnancy 14-, 21-, 28- and 126-days post-breeding. Pregnancy diagnosis was carried out by palpating the uterus to detect amniotic vesicle, cotyledon/placenta and foetus. Amniotic vesicle, a positive sign of pregnancy, was identified as a fluctuating fluid in the uterine horn that began to enlarge after mating. Similarly, cotyledon/placenta as circumscribed round bodies and foetus with foetal parts detected, were used as positive signs of pregnancy (Bello *et al.*, 2022a)

Ultrasonography

Ultrasonography (Sonostar Laptop-C5[®], 5 MHz Curvilinear Probe, China) was carried out to diagnose pregnancy on day 14, 21, 28 and 126 post-breeding. The perineal area cranial to the

mammary gland of posterior abdomen was shaved and animal restrained on dorsal recumbency on cradle on a table. An aquasonic gel was applied on shaved area and using transcutaneous probe; pregnancy was diagnosed by scanning for embryonic vesicle, embryo proper and foetus as diagnostic of pregnancy.

Radioimmunoassay

Blood samples were collected in all groups from bred does on day 21 post-breeding for progesterone assay to diagnose pregnancy. A 10 ml syringe and needle was used to obtain blood sample by veni-puncture of the jugular vein. A total of 5 ml blood sample was collected and subsequently taken to the laboratory for serum separation and storage. The serum was assayed for progesterone concentration using ELISA (AccuBind[®] - Monobind Inc., Lake Forest, CA 92630, USA; Product Code: 4825-300). The intra-and-interassay coefficients of variation were 5.3 % and 7.9 %, respectively. Progesterone concentrations of ≥ 0.5 ng/ml in bred does was considered diagnostic for pregnancy, while concentrations of ≤ 0.04 ng/ml indicated non pregnancy (Bello *et al.*, 2022a).

Non-return to oestrus

Pregnancy was diagnosed in bred does by observing their return to oestrus after 21 days post-breeding. Does that did not return to oestrus after 21 days were considered pregnant, while does that returned to oestrus after 21 days were considered not pregnant.

Data collection and analyses

Data on breeding, oestrus synchronization response, non-return to oestrus rate, pregnancy rate were collected. The data were subjected to one-way analysis of variance (ANOVA) and GraphPad Prism Version 5.0. Values of $P < 0.05$ were considered significant (SPSS, 2011).

Ethical clearance

Approval of Ethical Clearance on Bioethics and Animal Use was obtained from Ahmadu Bello University Ethical Clearance Committee with approval number: ABUCAUC/2019/004, before the experiment was carried out.

RESULTS

Semen collection, processing and storage.

Table 1 shows semen characteristics: 0.5 to 0.8 mL (volume), creamy (colour), 95 % (motility), 7.0 (pH), 10 to 18 (sperm abnormality), 90:10 (live-dead ratio), $311 \times 10^6/\text{mL}$ to $422 \times 10^6/\text{mL}$ (concentration) and < 1.0 to 1.0 minutes reaction time (libido). Semen was stored at 4°C and survived for three days with motility declining from 95 to 45 %.

Table 1: Semen characteristics of Red Sokoto goat bucks used for artificial insemination method of breeding for groups A and B.

S/N	Tag No.	Semen characteristics							
		Volume (mL)	Colour	*Motility (%)	pH	Sperm Abnormality.	LDR	Concentration	Libido (RT: Min.)
1.	505	0.5	creamy	90	7.0	10	90:10	$422 \times 10^6/\text{ml}$	1.0
2.	789	0.8	creamy	95	7.0	18	90:10	$311 \times 10^6/\text{ml}$	< 1.0

* Semen was stored at 4°C and survived for three days with motility declining from 95 to 45 %.

Note: LDR – live/dead ratio, RT – reaction time, Min. - minute

Oestrus synchronisation, oestrus response rate and breeding.

Table 2 shows oestrus response rates was 92.9%, 85.7% and 100% for groups A, B and C, respectively. There was no significant difference ($P > 0.05$) between groups for oestrus response rate, non-return rate and return to oestrus rate.

Table 2: Summary of oestrus response rate, breeding and return to oestrus rate in Red Sokoto goat does for groups A, B and C.

S/N		Breeding			Total
		Group A (AIDRP)	Group B (AIVSM)	Group C (NS: Control)	
1.	No. of does per group	14	14	14	42
2.	No. in oestrus and bred (ORR)	13 (92.9 %) ^a	12 (85.7 %) ^a	14 (100 %) ^a	39 (92.9 %)
3.	No. not responded to treatment and not bred (NR)	1 (7.1 %) ^a	2 (14.3 %) ^a	0 (0.0 %) ^a	3 (7.1 %)
4.	No. returned to heat and rebred (RR)	1 (7.1 %) ^a	0 (0.0 %) ^a	1 (7.1 %) ^a	2 (4.8 %)

Letter superscription indicate no significant ($P > 0.05$) difference.

Key: AIDRP – artificial insemination by digital rectal palpation, AIVSM – artificial insemination by vaginal speculum method, NS – natural service, NR – oestrus non-return rate, ORR – oestrus response rate, RR – oestrus return rate. No significant difference ($P > 0.05$) between groups for ORR, NR and RR.

Pregnancy diagnosis

Table 3 shows comparative pregnancy diagnosis on day 14, 21, 28 and 126 using US, DRP, P₄ and NRH for groups A, B and C. Pregnancy rates for day 14 were: 57.1 %, 7.1 % and 21.4 % (US); 7.1 %, 42.9 % and 64.3 % (DRP); day 21 were 64.3 %, 92.9 % and 100 % (US); 42.9 %, 57.1 % and 57.1 % (DRP); 78.6 %, 78.6 % and 100 % (P₄); 85.7 %, 78.6 % and 92.9 % (NRH); day 28 were 78.6 %, 100 % and 100 % (US); 78.6 %, 64.3 % and 85.7 % (DRP); and day 126 were 57.1 %, 64.3 % and 92.9 % (US); 57.1 %, 64.3 % and 85.7 % (DRP) for groups A, B and C, respectively. There was significant ($P < 0.05$) difference between US and DRP on day 14 in group A; between US, DRP, P₄ and NRH on days 21 and 28 in group B; and between US, DRP, P₄ and NRH on day 21 in group C.

Table 3: Comparative pregnancy diagnosis rates using ultrasonography, digital rectal palpation, progesterone assay and non-return to heat in Red Sokoto recto-vaginal and vagina speculum artificial insemination; and natural service groups (A, B and C).

S/N	Method of Diagnosis	Day	Pregnancy diagnosis and rates; N = 42		
			Group A; n = 14	Group B; n = 14	Group C; n = 14
			PR (%)	PR (%)	PR (%)
1.	US	14	57.1 ^a	7.1	21.4
		21	64.3	92.9 ^a	100 ^a
		28	78.6	100 ^a	100
		126	57.1	64.3	92.9
2.	DRP	14	7.1 ^b	42.9	64.3
		21	42.9	57.1 ^b	57.1 ^b
		28	78.6	64.3 ^b	85.7
		126	57.1	64.3	85.7
3.	P ₄	21	78.6	78.6 ^c	100 ^c
4.	NRH	21	85.7	78.6 ^d	92.9 ^d

Different letter superscription indicate significant ($P < 0.05$) difference on day 14 in group A; on day 21 in groups B and C; and on day 28 in group B.

Key: - DRP – digital rectal palpation, NRH - non-return heat, P₄ – progesterone assay, PR – pregnancy rate, US – ultrasonography, % - percentage, group A – recto-vaginal AI, group B – vaginal speculum AI and group C – natural service; control.

Kidding

Kidding parameters for groups A to C are shown in Tables 4. Group A had 12 kids with five males and seven females; with single, twin and triplet births. Group B had 8 kids with four males and four females; with single and twin births. Group C had 15 kids with five males and 10 females; with single and twin births. Rates ranges across groups A to C were: 62.5 to 85.7 % (single), 14.3 to 36.4 % (twin), 0.0 to 12.5 % (triplet) and 0.0 % (quadruplet), 78.6 to 100 % (kidding rate), while gestation had 126 to 176 days.

Table 4: Kidding parameters of Red Sokoto goat does for groups A, B and C.

S/ N	Group n = 14 per group	No. bred	No. preg- nant	No. abor- ted	No. kid- ded	Kidding						
						Single births	Twin births	Triplet births	Male births	Female births	Total	Gestation
1.	A	13	8	0	8 (100)	5 (62.5)	2 (25.0)	1 (12.5)	5 (41.7)	7 (58.3)	12 (34.3)	154 129-173
2.	B	12	7	0	7 (100)	6 (85.7)	1 (14.3)	0 (0.0)	4 (50.0)	4 (50.0)	8 (22.9)	164 161-170
3.	C	14	14	0	11 (78.6)	7 (63.6)	4 (36.4)	0 (0.0)	5 (33.3)	10 (66.7)	15 (42.9)	148 126-176
Total; 42		39	29	0	26	18	7	1	14	21	35	

NB: Percentages (%) in parentheses.

DISCUSSION

Semen processed for breeding had good semen characteristics and quality for artificial insemination (AI). The volume, motility, concentration and libido among other features compared with findings of Jatau (2002), Bello (2019) and Bello *et al.* (2022b) for this breed. Semen concentrations in this experiment was comparable to vaginal AI concentration and above the normal cervical AI standard and, hence, the obtained fertility, which agrees with reported fertility (Leethongdee and Ponglowhapan, 2014; Bello *et al.*, 2022b). This was considered to achieve high fertility rate, especially being recto-vaginal

DRP AI and in the Red Sokoto goat breed. However, it appears the concentration in the present study was inconsequential, evidenced by similar return to oestrus rate in all groups. It is believed that with the present fertility obtained and return to oestrus rate for the AI and control groups, the standard dilution concentration used for goats may be used and similar fertility rate may equally be achieved. The oestrus response observed in this experiment was good and high. Attention should be paid on similar oestrus response when planning synchronised breeding especially with natural service. Provision for additional bucks should be made to overcome exhaustion and fatigue (Bello *et al.*, 2022b).

The good response rate generally, but notably for the natural service group C was challenging for the two bucks initially designated to minimize influence of buck on fertility, and breeding intended to be spread over seven days. Ultimately, additional bucks were used to make up for the good response and reduce the challenge of breeding fatigue and exhaustion. Hence, mating was strictly restricted to mounting only once with evidence of an ejaculatory thrust at each of the two mating 12 hours apart. Perhaps, this explained the low return to oestrus rate after breeding for the group. The return to oestrus rate for the experiment was generally low and resulted in few does re-bred (Bello, 2019). Breeding indicated high and acceptable conception rate and pregnancy rates as reported; and fertility result showed no significant difference between DRP AI, vaginal speculum AI and control, indicating great potentials in the new technique (Bello *et al.*, 2022b). Evaluation showed that vaginal speculum AI was cumbersome, requiring many hands for restraint and insemination, particularly in the absence of a chute; flash torch light was required even in broad day light. Furthermore, insertion, positioning and stabilization of the speculum, uncertainty of deposition site of semen, fear of exerting excessive pressure with AI gun intracervical or intrauterine were other factors. In contrast, recto-vaginal DRP technique for AI found enumerated factors above unnecessary, especially with facility such as chute or crush as for large ruminant AI. The DRP AI was much easier and convenient; significantly it gave comparably equal conception rate and even higher pregnancy rate results than speculum AI (Bello *et al.*, 2022b). Comparative, digital rectal palpation (DRP) technique pregnancy rate (PR) was similar to that of ultrasonography across the groups. The technique showed great potential for early pregnancy diagnosis in the breed and probably in

goats generally. This highlights the relevance and significance of DRP technique application for breeding and pregnancy diagnosis. Pregnancy rate for DRP increased significantly from day 14 to day 126 across groups with highest rates on day 28; suggesting early pregnancy diagnosis in Red Sokoto goat does, day 28 may be the standard. However, Bello *et al.* (2022a; 2012) reported similar findings on day 21 for the breed, which agrees with report of Abou- El- Roos and Shawki (2003) in ewes on day 30. The low rate on day 14 in group A was attributed to inexperience and lack of skills, palpation usually starts from group A to C. The mistakes and learning took place in group A, when procedure was being carried out in groups B and C, some level of skill perfection was achieved. Hence, the higher rates even on day 14 (64.3 %) in group C. This implies that early pregnancy diagnosis using DRP on day 14 is feasible even as a standard, which may be more beneficial. However, much research and practice would be required. Digital rectal palpitations technique is simple, cheap, fast, instant, field-based, no power required, 'double edged' function of gynaecological examination and breeding (artificial insemination). It requires common and simple materials for the procedure, adoptable and safe, and holds a great prospect and potentials for the goat industry. Pregnancy rates obtained in this study were high and acceptable, comparable, agree and confirms the reports of Kutty (1999), Abou- El- Roos and Shawki (2003), Bello *et al.* (2012), Bello (2019) and Bello *et al.*, (2022a), where similar values on days 21 to 30 post-service were reported. Besides, the results indicated uterine distension was palpated and identified earlier on days 14 and 21 after mating than the 28 to 30 days reported (Abou- El- Roos and Shawki, 2003; Bello, 2019; Bello *et al.*,

2022a). Reason for variation in results may be attributed to species and individual skills. The result suggests the technique may be comparable with ultrasonography, which sometimes is not field friendly especially in developing countries. The results also indicates that at the third to fourth week of gestation, uterine distension on days 21 to 28 was unmistakable, as experience or expertise increased greatly with increasing palpation. Foetal membrane slip and cotyledons were not detected in this experiment, but foetus was positively detected on day 126 with distinct parts identifiable in all diagnosed does. Possibly, as more experience is being gained, much earlier detection may be achieved. The present findings differed with results of Kutty (1999) and Abou- El- Roos and Shawki (2003), who reported detection of foetus at 90 days in 85 % of cases. This is another useful finding which may also be of advantage when established through further investigation. Digital rectal palpation technique may be comparable with pregnancy diagnosis per rectum in large animals. The accuracy of diagnosis at one month is much lower in large animals especially using the amniotic vesicle (22% in cattle) (Voh Jr., 1996); since uterine distension is not marked at this stage, compared with that in small ruminants (Kutty, 1999). If more work is done to establish this finding, the prospect is enormous in goats and small ruminant production generally. Differences in the results might probably be due to breed differences. It may be inferred that the smaller the breed, the higher the probability of detecting distended uterus, which may easily fill-up the relatively smaller pelvic cavity. Another reason for the variation may be the small modification of the technique, where the first (index) finger was solely used for the palpation. The conscious effort of using one hand to stabilize the pelvic structures, while mainly using the index finger to palpate and

explore structures within the cavity in relation to the examiner and the index finger, as well as avoidance of excessive stress not to induce abortion, probably made the difference in detected structures. Despite the above, the minimal force used by the supporting hand, might have also influenced the position of structures in pelvic cavity in a posterior manner. Despite the observations made, the technique holds a great prospect for positively changing small ruminant reproduction and production management in general. The study, therefore, showed that digital rectal palpation was effective and successful in diagnosing pregnancy in Red Sokoto goat does. The various pregnancy diagnostic techniques used in each group, showed similarities and did not differ significantly, and both agreed with reports of different authors (Ishwar, 1995; Dawson, 1999; Kutty, 1999; Dawson, 2002; Abou- El- Roos and Shawki, 2003; Bello *et al.*, 2012; Kumar, 2015; Lone, 2016; Bello, 2019; Bello *et al.*, 2022a). Comparison on day 21 for US, DRP, P₄ and NRH showed similarity with little variation for both techniques; and were higher than the report of Kutty (1999) but lower than Bello *et al.* (2012). Generally, results indicates that US, P₄ and NRH gave higher PR values and DRP the least. However, overall summary results showed P₄ was the best diagnostic method. Results indicates, that ultrasonography fairly remained consistent across days (14 to 126) and across groups (A to C) with minor variations. Similarly, observation was true for progesterone and non-return to heat (Kutty, 1999; Bello *et al.*, 2012; Bello *et al.*, 2022a). Across days (14 to 126) and groups (A to C), values increased with increase in days and across groups. Two reasons may be responsible: the increasing fast developing anatomical structures within the uterus, resulting in growth,

and change in position, especially with the small sized pelvic cavity of the doe, enabling easy detection with increasing days. Furthermore, the practice of palpation procedure which always began with group A to C and only realized after the experiment, enabled experience to be gained, with skill developed and technique perfected from the first to the last doe in each palpation procedure. This finding is highly significant because better results may be obtained with later days (as in day 21, 28 and 126) as well as frequent and higher number of palpation (as in group C). This observation further highlights the significance of DRP in the study. All the methods effectively diagnosed pregnancy in Red Sokoto goats with acceptable pregnancy rates. Fertility across days and groups indicated little variations, especially between AI groups, which compares favourably with the control. The rates were within reported range (Leethongdee and Ponglowhapan, 2014; Anghel *et al.*, 2016; Bello *et al.*, 2022b). Obtained rates was even higher than the previous report of Smith (1995) using fresh and frozen semen in artificial insemination with pregnancy rate of 10 % (frozen) to 50 % (fresh) for vaginal, 35 % (frozen) for cervical, 40 % (fresh) and 40 to 50 % (frozen) for transcervical; while 70 % (fresh) and 65 % (frozen) for laparoscopic. Notably, natural service and AI PR obtained in this study were higher than those of the vaginal, cervical and laparoscopic inseminations. Significantly was the comparable fertility of vaginal speculum and DRP recto-vaginal AI. The specific finding may suggest a new line of investigation for improvement of production in goats and small ruminant in general. Speculum AI (group B) had seven kidding, while recto-vaginal DRPAI (group A) had eight as against control (group C) with 11. Overall, bred does diagnosed pregnant successfully kidded with 19 single, six twins and

one triplet births without intervention giving a total of 31 kids. Recto-vaginal DRP AI, compared favourably not only by effecting pregnancy, but does carried pregnancies to term and kidded successfully without assistance. Significantly, the group also produced the only triplet birth, further highlighting the effectiveness of the new breeding technique, which may indicate that the high prolific tendency of the breed was not affected (AU, 2015; Bello *et al.*, 2022b). Overall results showed group C had the best kidding parameters while group B had the least. Gestation ranged from 126 to 176, and was within the reported values (Bello, 2019). Kidding rates in all groups is in agreement with AU (2015) and Bello *et al.* (2022b) for the breed. The rate obtained was acceptable and high, though less than 175% reported by Adu (1980) over the 5 year study period, and similar to Bello *et al.* (2022b) which ranked the breed among the most prolific breed of goats, but comparable to the reports of Leethongdee and Ponglowhapan, (2014) and Anghel *et al.* (2016). Abortion rate of 0.0 % was significant especially with the nature of the experiment, where does were subjected to stress of palpation during the experimental period. This may imply less negative effect of DRP technique procedure on both health and reproductive life of Red Sokoto goat does. The litter type results differed from the reports of Akusu (2003), who obtained lower percentage for singletons (27.0 %) and higher for twinning (57.0 %), triplets (13 %) and quadruplets (3 %) births; but similar to Bello *et al.* (2022b). The differences in the findings may be due to breed difference, method of diagnosis applied and management system. The study, therefore, showed that digital rectal palpation (DRP) technique was

effective and successful in comparative early pregnancy diagnosis with ultrasonography, progesterone assay and non-return to heat in Red Sokoto goat; hence, supporting and confirming earlier reports for the breed and in goats. It was concluded that digital rectal palpation (DRP) technique positively and effectively diagnosed pregnancy on days 14 (64.3 %), 21 (57.1 %) and 28 (85.7 %), with maximum detection on day 28, in comparison with ultrasonography; and on day 21 to progesterone assay and non-return to heat in Red Sokoto goat does. It is therefore recommended for adoption in goats.

ACKNOWLEDGEMENTS

We acknowledge the Executive Director, National Animal Production Research Institute, Shika, Ahmadu Bello University, Zaria, for permission and support to carry out the work in the Institute.

REFERENCES

- ABEKE, F. O., SEKONI, A. A., ONI, O.O., ADEYINKA, I. A. and NWAGU, B. I. (2008). Response of Shika-Brown Pullet Chicks and Layers to Homemade and Commercial Feeds in Zaria, Kaduna State, Nigeria. *Journal of Tropical Agriculture, Food, Environment and Extension*, 7(3): 223 – 228.
- ABOU- EL- ROOS, M. and SHAWKI, G. (2003). Clinical Approach for Assessment of the Reproductive Status in Ewes. *Zagazig Vet J.* 31.1, 1-1 0.
- ADU, I. F., BUVANENDRAN, V. and LAKPINI, C. A. M. (1980). Highlights of sheep and Goat Research at NAPRI, Shika. A paper presented at Veterinary and Livestock Continuing Education Workshop, Ahmadu Bello University Zaria. 159 – 17.
- AFRICAN UNION (AU), (2015). The Red Maradi Goat (*Capra hircus*). Interafrican Bureau For Animal Resources. <https://www.google.com.ng/search?q=African+Union++The+Maradi+goat&rlz=>; (accessed 17 February, 2018).
- AKUSU, M. O. (2003). Reproductive Performance of Goats for Maximum Animal Production in Nigeria. Inaugural Lecture, 2002/2003, University of Ibadan Nigerian. 6-7.
- ANGHEL, A., NADOLU, D., ANGHELESCU, C. and SONEA, C. (2016). Artificial Insemination of Carpathian Goats with Semen Preserved in different Forms. The Annals of “Valahia” University of Targoviste. DOI: 10.1515/agr-2016-0004.
- BELLO, A. A., VOH (JR), A. A., OGWU, D. and TEKDEK, B. L. (2012). Digital rectal palpation: a technique for gynaecological examination and pregnancy diagnosis in Red Sokoto goat. Book of Abstract, No. 3202. *Reproduction in Domestic Animals*, Vol. 47, Issue Supplement S4. 17th International Congress on Animal Reproduction. July 29th – 2nd Aug.

- 2012, Vancouver, British Columbia, Canada. 544. URL: <http://onlinelibrary.wiley.com/doi/10.1111/rda.2012.47.issue-s4/issuetoc/> (accessed April 5 2013).
- BELLO, A. A. (2019). Digital Rectal Palpation as a Technique for Gynaecological Examination, Artificial Insemination and Pregnancy Diagnosis in Red Sokoto Goat Does. Ph.D. Thesis, Ahmadu Bello University, Zaria, Nigeria. 83-128.
- BELLO, A. A., VOH (JR), A. A., OGWU, D., TEKDEK, B. L. and MARUF, L. (2021). Digital Rectal Palpation: A Technique for Gynaecological Examination, Pregnancy Diagnosis and Ageing in Red Sokoto Goat. *Tropical Veterinarian*, 39(2): 2-19.
- BELLO, A. A., VOH, A. A. JR, OGWU, D., TEKDEK, L. B., and AYO, J. O. (2022a). Comparison of ultrasonography, progesterone assay, ballottement, and non-return-to-heat with digital rectal palpation technique for early pregnancy diagnosis in Red Sokoto goat. *Reproduction in Domestic Animals*, 00, 1-9. <https://doi.org/10.1111/rda.14283>
- BELLO, A. A., VOH (JR), A. A., OGWU, D., AYO, J. O. (2022b). Recto-vaginal artificial insemination using digital rectal palpation technique in Red Sokoto goat. *Small Ruminant Research*, 215 (2022) 106780, 1-5. <https://doi.org/10.1016/j.smallrumres.2022.106780>
- DAVID, M. (2016). Pregnancy diagnosis in goats. *Surgery, Orthopedics & Anesthesia*. 85- 102. <https://veteriankey.com/category/surgery-orthopedics-anesthesia/> (accessed March 23; 2019).
- DAWSON, L. J. (1999). Pregnancy Diagnosis in Goats. Proc. 14th Annual Goat Field Day, Langston University, Langston, UK. 97-103.
- DAWSON, L. (2002). Pregnancy diagnosis in goat: Proceedings of 17th Annual Goat Field Day Langston University, UK. 41-44.
- FARIN, C. E. (2015). Artificial Insemination and Embryo Transfer in Goats. <https://meatgoats.ces.ncsu.edu/wp-content/uploads/2015/10/Goat-AI-ET.pdf?fwd=no>, (accessed 25 January, 2019).
- IBM CORP. IBM SPSS (2011). Statistics for Windows, Version 20.0. Armonk, NY: IBM Corp; Released 2011.
- ISHWAR, A. K. (1995). Pregnancy diagnosis in sheep and goat - a review. *Small Ruminant Research*; 17, 37-44.
- JATAU, J. D. (2002). Oestrus Response and Conception Rate of Red Sokoto Goats following oestrus synchronisation with prostaglandin F2-alpha. H.N.D. Thesis. Federal College of Animal Production and Husbandry, Vom, Plateau State, Nigeria. 30-45.

- KARADAEV, M. (2015). Pregnancy Diagnosis Techniques in Goats – A Review. *Bulgarian J of Vet. Med.* 18.3, 183-93.
- KAREN, A., KOVACS, P., BECKERS, J. F and SZENCI, O. (2001). Pregnancy diagnosis in sheep: Review of the most practical methods. *Acta Veterinaria Brno.* 70, 115-126.
- KUMAR, K., CHANDOLIA, R. K., PAL, M., and KUMAR, S. (2015). Two-dimensional and three-dimensional ultrasonography for pregnancy diagnosis and antenatal fetal development in Beetal goats. *Veterinary World.* 8.7, 835-840.
- KUTTY, C. I. (1999). Gynaecological examination and pregnancy diagnosis in small Ruminants using bimanual palpation technique; a review. *Theriogenology.* 51.8, 1555-64.
- LEETHONGDEE, S. and PONGLOWHAPAN, S. (2014). Artificial Insemination in Goats: An Update. *Thai Journal of Veterinary Medicine.* 44.Suppl. 1, 73-77.
- LONE, S. A., GUPTA, S. K., KUMAR, N., SHINDE, K. P., GANAIE, B. A., RATHER, H. A. and KUMAR, S. (2016). Recent Technologies for Pregnancy Diagnosis in Sheep and Goat: An Overview. *International Journal of Science, Environment and Techno-logy.* 5.3, 1208-1216.
- MALAU-ADULI, A. E. O., ABUBAKAR, B. Y., EHOICHE, O. W. and DIM, N. I. (1996). Studies on milk production and growth for Friesian and Bunaji crosses. I. Dairy performance. *American Journal of Animal Science.* 9.5, 503-508.
- SMITH, J. F. (1995). Artificial insemination in dairy goats: Goat Breeding: *Artificial Insemination versus Natural Breeding.* Goatworld (© 1999-2008 Goatworld.com). <http://www.goatworld.com/> (accessed February 7, 2021).
- VOH JR., A. A. (1996). Fertility and Embryonic Mortality rates of Zebu Cows following Oestrus Synchronisation and Artificial Insemination. Ph.D. Thesis, Ahmadu Bello University, Zaria, Nigeria. 119-133.