



MANAGEMENT OF ACUTE ASPERGILLOSIS IN NEWLY HATCHED CHICKS: A CASE REPORT.

Oladele, O. O^{1*}; Ameji, N. O¹.; Odey, M¹.; Gurumyen, G. Y².; Adanu, A. W³.; Bitrus, A. A².; Durkwa, H. U⁴.; Anifowose, O. R⁵. and Unanam, E. S¹.

¹Department of Veterinary Medicine, Surgery and Radiology, Faculty of Veterinary Medicine, University of Jos, Nigeria.

²Department of Veterinary Microbiology and Pathology, University of Jos, Nigeria. ³Department of Veterinary Public Health and Preventive Medicine, University of Jos, Nigeria. ⁴Veterinary Teaching Hospital, University of Jos, Nigeria. ⁵Department of Veterinary Medicine, Faculty of Veterinary Medicine, University of Ibadan, Nigeria.

*Corresponding author: Email: oludotunoladele@gmail.com; Tel No: +234 803 382 3237.

SUMMARY

High and early mortalities of chicks often result in colossal economic losses. Aspergillosis, a fungal infection in chicks often occurs in the first 2 weeks of life and may be misdiagnosed as a common respiratory problem like Mycoplasmosis. Some Veterinarians are of the opinion that there is no effective way of treating Aspergillosis. This clinical case report describes the management of acute aspergillosis in chicks. Necropsies were done thrice. Grossly, congested livers, hemorrhagic nephritis, and congested lungs with whitish nodules were observed. Histologically, there were numerous multinuclear giant cells, macrophages and heterophils in the liver. The lung showed fungal hyphae and inflammatory cells. In the kidney, there was severe tubular epithelial necrosis indicated by the pyknotic nuclei, mononuclear infiltrates and haemorrhages. Considering the mortality rate, necropsy findings, microbial isolation and histopathologic observations, systemic Aspergillosis was diagnosed. The secondary bacterial infection was caused by *Escherichia coli* which was resistant to 8 antibiotics and susceptible only to Penstrep® (Penicillin + streptomycin). Initial resistance to copper sulphate necessitated a change to Nystatin which was used for 12 days via drinking water. Cumulative mortality was 757 (34.37%) in a flock of 2,202 chicks. Better control of systemic fungal infections may be enhanced by early application of anti-fungal susceptibility test.

Keywords: Aspergillosis, Chicks, Mortality, Necropsy, Nystatin.

INTRODUCTION

Early and high mortalities in newly hatched chicks are often triggered by several factors which could be either biotic or abiotic in nature. Of the abiotic factors, the most common could be poor regulation of brooding temperature. High temperatures lead to panting, dehydration, and eventual death. Temperatures below the optimum required for brooding, results in excessive huddling and stampeding can occur. This is often caused by management errors. Chilling or overheating at early phase of chicks' growth can result in poor growth, feed conversion and increased susceptibility to disease (Brian, 2012). Amongst the biotic factors are microorganisms, some of which are vertically transmitted bacteria and aerial fungal spores that are inhaled by newly hatched chicks within the hatchers. Some of these fungal spores could also be found in feed and on litter materials (Chauhan and Roy, 2007; Michelle and Megan, 2020). This can result in fungal infection via ingestion and inhalation respectively. It is a known fact the eggshell surface gets contaminated by microbes (Amal *et al.*, 2015), hence chick embryos can also get infected through contaminated eggshell (Hamet *et al.*, 1991; Chauhan and Roy, 2007). The most common fungal disease that causes early and high mortality in chicks is Aspergillosis, a non-contagious systemic fungal disease caused by *Aspergillus* species like *Aspergillus fumigatus*, *A. flavus* and *A. niger*. *A. fumigatus* is the principal etiologic agent of aspergillosis in poultry (Abdu and Musa 2019; Michelle and Megan, 2020) and has been reported in about 95% of cases of Aspergillosis (Martins *et al.*, 2020). It affects various avian species i.e. both domestic and wild

species (Della *et al.*, 2019). Aspergillosis (brooder pneumonia) usually occurs within the first 10 to 14 days of life of the birds (Kannoju *et al.*, 2021). The disease occurs in two forms: acute (which results from the ingestion of large number of fungal spores) and chronic (mostly seen in birds with reduced immunity) (Arne *et al.*, 2011). Aspergillosis initially affects respiratory system in birds (trachea, lungs, air sacs) and spreads to other organs by hematogenous route (Kannoju *et al.*, 2021). In acute infection especially within 3 to 5 days of exposure to the fungal spores, chicks will manifest the clinical signs of gasping and dyspnea, lack of appetite, emaciation, increased thirst, and drowsiness (Abdulrahman, 2014). Other clinical signs include eye swelling, blindness and torticollis. Some workers are of the opinion that there is no effective way of treating birds with aspergillosis (Michelle and Megan, 2020) and the focus is more on prevention. This clinical case described the management of acute aspergillosis in newly hatched chicks with severe mortalities.

Case History

On the 19th of May 2021, a client presented twelve (12) live day-old Isa brown chicks from a flock of 2,202 chicks to the Avian and Aquatic animal Clinic of the University of Jos, Veterinary Teaching Hospital for day-old chick assessment. The birds were fed vital® feed chick mash and given well water that is sanitized. On the 23rd of May 2021, there was a distress call from the farmer that 90 chicks had died. The farmer was advised to bring some of the dead chicks for post mortem examination to ascertain the cause of mortality and aid in diagnosis.

Diagnostic Tests

Necropsy

On three occasions, post-mortem examinations were conducted on the chicks and on the first day only 3 weak/moribund chicks were selected and examined. On day 5 of age, more carcasses (from a flock of about 2,200 chicks) were presented and on these two occasions, the key gross lesions observed were congested livers, hemorrhagic nephritis, and congested lungs with whitish nodules (Plate 1).

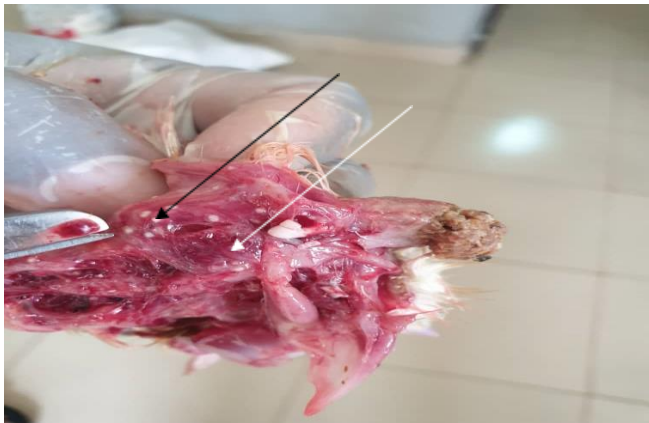


PLATE 1: Congested lung (white arrow) with whitish nodules on it and on the rib cage (black arrow).

At week 2 of age, another post-mortem examination was done and the following lesions were observed: lean breast muscle with slightly prominent keel bone, empty crops, mild ascites, partially congested livers, congested lungs with greyish-white area of necrosis and congested kidneys with slightly distended ureters. Affected organs were harvested and divided into two parts, one for microbial analysis and the other preserved in 10% formalin for histopathologic investigation.

Microbial analysis

Harvested organs like lungs, liver, spleen, kidneys were cultured on Blood agar, MacConkey agar and Sabouraud Dextrose Agar and isolates were identified using routine standard microbiological culture and identification. Direct antimicrobial susceptibility test was done on nutrient agar and as described by Rosemary, (2019). Inoculated agars were incubated aerobically at 37°C for 24 hours for blood agar, nutrient agar and MacConkey agar and up to 48 hours for Sabouraud dextrose agar.

Histopathologic Investigation

Harvested organs like lungs, liver and kidneys that were preserved in 10% formalin were subjected to dehydration under various concentration of ethanol (70%, 80%, 90% and 100%), cleared in xylene and embedded in paraffin blocks before sectioning on the microtome. Sectioning and staining with hematoxylin and eosin were done as described by Akpavie, (2014).

RESULTS

Management of condition and discussion

Microbial analysis of tissues of chicks on blood agar yielded high growth of white convex bacterial colonies that were non-hemolytic. On MacConkey agar the bacterial colonies were lactose fermenters. Gram staining and other biochemical tests conducted on the isolate as shown on Table 2 confirmed organism to be *Escherichia coli*. The antibiotic susceptibility test conducted showed that isolate was susceptible to Penstrep® (Penicillin +

streptomycin) and resistant to enrofloxacin, gentamicin, streptomycin, florfenicol, colistin, oxytetracycline, tylosin, and furaltadone (Table 1).

TABLE I. Antimicrobial susceptibility pattern of *Escherichia coli* isolated from clinical case of acute aspergillosis in newly hatched chicks.

Susceptible	Intermediate	Resistant
Penstrep®		Enrofloxacin Gentamicin Streptomycin Furaltadone Florfenicol Colistin Oxytetracycline Tylosin

Key Penstrep® = (Penicillin + streptomycin)

TABLE II. Biochemical tests for bacterial identification of *Escherichia coli*

TEST	RESULT
Gram reaction	-
Shape	Rods
Oxidase	-
Catalase	+
Hemolysis	-
Motility	-
Citrate	-
Glucose	+
Lactose	+
Sucrose	+
EMB agar Reaction	Greenish metallic sheen

Swabs of kidneys, livers and lungs streaked on Sabouraud dextrose agar started yielding fungal growth from 24 hours post incubation and by 48 hours, it had predominantly yielded growth of *Aspergillus fumigatus* (ash-colored colonies) and *Aspergillus niger*. (Plate 2)

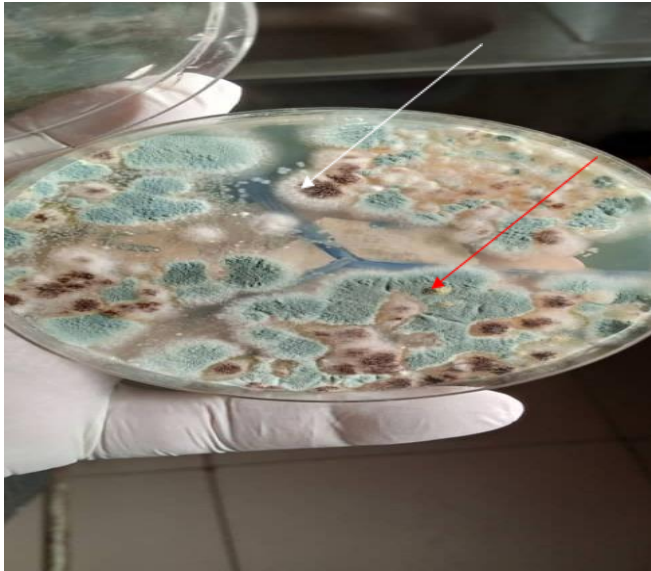


PLATE 2: Colonies of *Aspergillus fumigatus* (red arrow) and *Aspergillus niger* (white arrow) growing from tissue inocula on Sabouraud dextrose agar.

Plate 3 also shows the microscopy of *Aspergillus* spp with its prominent globose vesicle stained with lactophenol cotton blue.

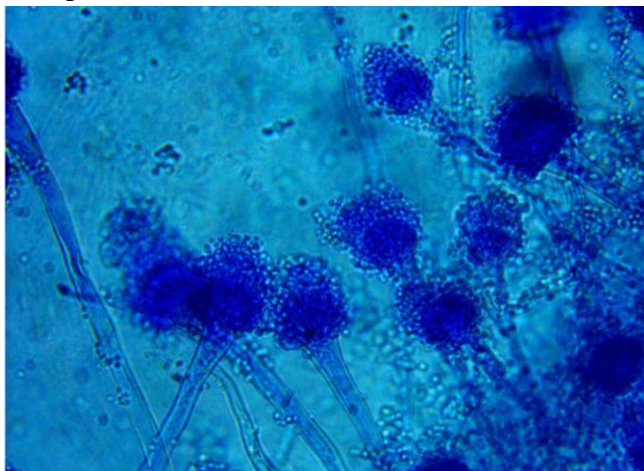


Plate 3: Morphology of fungal organism (*Aspergillus fumigatus*) x 10 mag. (Lactophenol cotton blue)

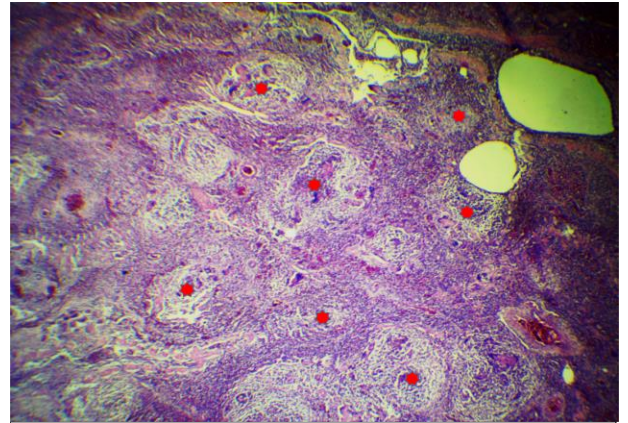


Plate 4: Photomicrograph of lungs showing chronic severe diffuse pyogranulomatous pneumonia (red asterisk) x4, H&E.

Histologically, in the liver, there were numerous multinuclear giant cells, macrophages and heterophils (Plate 5).

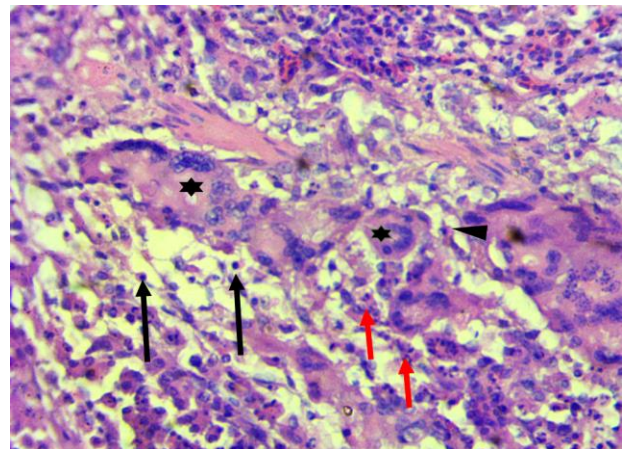


Plate 5: Photomicrograph of liver showing necrosis of the hepatocytes with numerous multinuclear giant cell (asterisk), macrophages (arrowhead), heterophils (red arrows) and plasma cells (black arrow) x40 H&E.

The lung showed fungal hyphae and inflammatory cells (Plate 6).

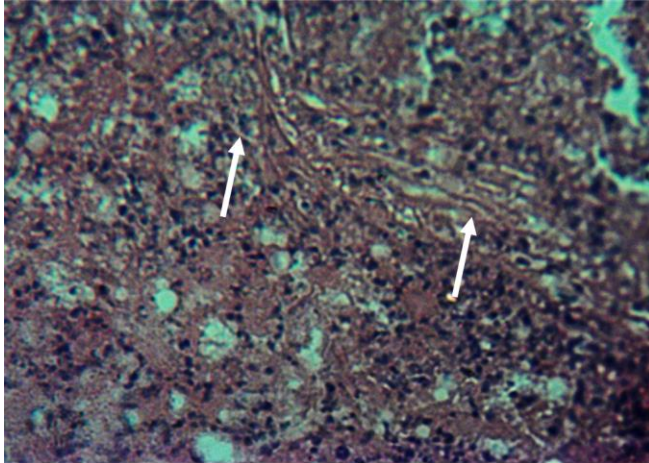


PLATE 6: Photomicrograph of Chicken lungs showing fungal hyphae (arrow), inflammatory cells ×10 H&E

The kidney showed severe tubular epithelial necrosis indicated by the pyknotic nuclei, mononuclear infiltrates and haemorrhages (Plate 7).

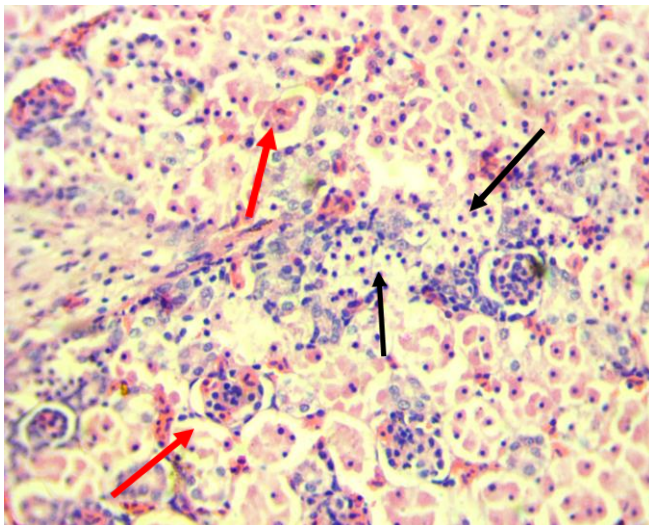


Plate 7: Photomicrograph of kidney showing severe tubular epithelial necrosis indicated by the pyknotic nuclei (red arrow) and mononuclear infiltrates (black arrow), and haemorrhages ×40 H&E

From the laboratory findings, acute Aspergillosis and Colibacillosis were the conditions diagnosed. The *Aspergillus* pathogens were however very resistant to Copper sulphate medication which was earlier administered with Penprovit® (Penicillin G procaine +Streptomycin sulphate + Vitamins) through drinking water from a day after first necropsy was done. This resistance to copper sulphate had not been seen in other cases earlier handled (Ameji *et al.*, 2020). This resistance of the *Aspergilli* to copper sulphate was shown from the farm records in which daily mortality from day 2 of age, increased from 75 chicks to 174 on day 5 (Table III).

TABLE III Mortality pattern and medications used on sick chicks.

Age (day)	Medication	Mortality	Age (day)	Medication	Mortality
1		18	15	Nystatin + Penprovit®	11
2	Penprovit® +CuSO ₄	75	16	Nystatin + Penprovit®	3
3	Penprovit® +CuSO ₄	53	17	Nystatin + Penprovit®	7
4	Penprovit® +CuSO ₄	116	18	Nystatin + Penprovit®	5
5	Penprovit® +CuSO ₄	174	19	Nystatin + Penprovit®	4
6	Nystatin	74	20	Nystatin + Penprovit®	2
7	Nystatin	73	21	Nystatin + Penprovit®	2
8	Nystatin	30	22	-	0
9	Nystatin	36	23	-	0
10	Nystatin	21	24	-	0
11	-	7	25	-	0
12	-	27	26	-	0
13	-	9			
14	-	16			

This pattern of mortality only started declining when Restatin® (500,000 UI/tablet Nystatin) was commenced via drinking water at 4 tablets of oral Nystatin (500,000 I.U./tablet) dissolved in drinking water for every 1,000 chicks (50,000 IU/kg) for 5 days in which mortality reduced from 174 in a day to 21 on the 5th day of Nystatin administration. A second phase of Nystatin (500,000 I.U./tablet) administration was commenced when lingering mortalities were still observed after stopping the first phase. The 2nd phase was for 7 full days from day 15 of age at a higher dose of 8 tablets dissolved in water per 1,000 chicks. The increased dose was because of the expected increase in body weight.

This 2nd phase treatment reduced mortality from 11 a day to 2 a day and for 5 consecutive days after stopping the drug, no mortality occurred. The cumulative mortality within 21 days was 757 chicks (34.37%). This would have been much higher if not for the intervention. Aryse *et al.*, (2020) had mentioned that Aspergillosis in birds could result in as high as 90% mortality. It is important to say that while managing the fungal disease, the complicating bacterial infection was also controlled even as the bacterial isolate was also found to be highly resistant to 8 antibiotics, but susceptible to just one (Table I). Nystatin is reportedly not absorbed from the gastro-intestinal tract (Yoland, 2005) and pharmacokinetic study indicates 0% bioavailability in plasma after oral administration. It kills fungi by binding to the ergosterol in the fungal cell membrane and in sufficient concentration, creates pores in the membrane that leads to leakage of potassium ions, acidification and death of the fungus (Hammond, 1977). The efficacy of orally administered Nystatin in the control of this systemic aspergillosis brings to the fore, a need to investigate the claim of ‘no absorption’ from the gastro-intestinal track as this infection from necropsy, microbial isolation and histopathology findings was not limited to the gastro-intestinal track, but cut across organs like lungs, liver, spleen, and kidneys. The probable explanation to the observed efficacy of this drug in control of aspergillosis may be the possible occurrence of inflammation of the intestine as this may enhance drug absorption. For a better and faster control of Aspergillosis in chicks, it is suggested that early conduction of anti-fungal susceptibility test be done routinely as described by Hassan *et al.* (2018) as soon as the fungi are isolated from tissues of birds.

REFERENCES

- ABDU P.A. and MUSA U. (2019) ‘Aspergillosis’ in Textbook of Avian medicine (2nd Edition), Saniez Press, Jos Plateau state. pp 281.
- ABDULRAHMAN N.R. (2014) Clinical and histopathological study of brooder pneumonia in broiler farms. *Al-Qadisiyah Journal of Veterinary Medicine Sciences* 13(1):75 DOI:10.29079/vol13iss1art281.
- AKPAVIE, S.O.,(2014): “Technical aspect of histopathology” in General Veterinary Pathology(2nd edition). Stirling-Horden publishers, Ibadan Nigeria, pp 9-10.
- AMAL F.A.M., AMANY, F.Z. and OLA, A.A.B. (2015) Contamination of the shell and internal content of table eggs with some pathogens during storage periods. *Assiut Vet. Med. J.* 61:146.
- AMEJI, N.O., OLADELE, O.O., BAMAIYI, P.H. and LOMBIN, L.H. (2020). Clinicopathological Features and Management of Aspergillosis in some poultry farms in Jos Metropolis, Nigeria. *Sokoto Journal of Veterinary Sciences*, 18(4):230-238.
- ARNÉ, P., THIERRY, S., WANG, D., DEVILLE, M., LOC'H, L., DESOUTTER, A. and GUILLOT, J. (2011). *Aspergillus fumigatus* in poultry. *International journal of microbiology*, DOI: [10.1155/2011/746356](https://doi.org/10.1155/2011/746356)

- ARYSE, M.M., DAVID A.S., LISA, A.T., CRISTINA, V., RAQUEL, S and MELISSA, O.X. (2020) Aspergillosis, Avian species and the One Health Perspective: The Possible importance of birds in Azole resistance. *Microorganisms* 8(12):2037. doi: 10.3390/microorganisms8122037.
- BRIAN D.F. (2012) Environmental Factors to Control when Brooding Chicks. UGA Cooperative Extension Bulletin 1287. Available online @ https://secure.caes.uga.edu/extension/publications/files/pdf/B%201287_5.PDF Retrieved in November 2022.
- CHAUHAN H.V.S. and ROY S. (2007) 'Aspergillosis' in Poultry Diseases, Diagnosis and Treatment (3rd Edition), New age International Ltd, Publishers pp 127-129.
- DELLA V.R., HEVIA A, VIVOT W, FERNÁNDEZ J, CÓRDOBA S.B. and REYNALDI, F.J. (2019) Aspergillosis in domestic and wild birds from Argentina. *Braz. J. Vet. Res. Anim.Sci.*, 56, e152460
- HAMET, N., SEIGLE-MURANDI, F and STEIMAN R (1991) Contribution to the prophylaxis of chicks Aspergillosis: Study of the contamination of a hatchery by *Aspergillus fumigatus*. *Zentralbl Veterinarmed B* 38(7):529-37. doi: 10.1111/j.1439-0450.1991.tb00907.x.
- HAMMOND, S.M.(1977). *Biological activity of polyene antibiotics. Progress in Medicinal Chemistry*. Vol. 14.pp. 105–79. doi:10.1016/S0079-6468(08)70148-6. ISBN 9780720406450. PMID 345355.
- HASSAN, R.M., KADRY, I.D. and SAMY, E.Y. (2018) Comparison of E Test and Disc Diffusion Methods for susceptibility testing of filamentous fungi: Experience of a routine lab. *Arch Clin Infect Dis*. 13(3):e57889.doi: 10.5812/archid.57889.
- KANNOJU, A., VELDI, P., and KUMAR, V. (2021). An overview of aspergillosis in poultry: A review. *Journal of Entomology and Zoology Studies*, 9, 685-688.
- MARTINS, M.A., STEVENS D.A., TELL L.A., VERÍSSIMO C., SABINO R. and ORZECZOWSKI X.M.(2020) Aspergillosis, avian species and the One Health perspective: The possible importance of birds in azole resistance. *Microorganisms* 8, 2037.
- MICHELLE, K and MEGAN L.(2020) Aspergillosis in poultry. MSD Veterinary manual. Available online @ <https://www.msdsvetmanual.com/poultry/aspergillosis/aspergillosis-in-poultry>.
- NYSTATIN on Wikipedia available online @ <https://en.wikipedia.org/wiki/Nystatin>. Retrieved on August 25th 2022.

ROSEMARY C.S.(2019) Direct from specimen antimicrobial susceptibility testing: state of the art in 2019. Clinical microbiology Newsletters 41(8) 65-71.

YOLAND B. (2005) “Antifungal drugs” in The Veterinary Formulary (6th Edition) Pharmaceutical press of Royal pharmaceutical society of Great Britain Pp 566.