



Gross And Histopathological Diagnosis Of Intra-Luminal Vaginal Leiomyoma In An 8-Year-Old Caucasian Bitch: Case Report

Gurumyen, G.Y.^{1*}; Omadevuaye, T.O.²; Polycarp, T.N.¹; Tizhe, E.V.¹; Adekunle, L.A.²; Usman, A.A.²; Jubril, A.J.²; Antia, R.E.²; Taiwo, V.O.²

¹Department of Veterinary Microbiology and Pathology, Faculty of Veterinary Medicine, University of Jos, Jos, Plateau State, Nigeria. ²Department of Veterinary Pathology, Faculty of Veterinary Medicine, University of Ibadan, Ibadan, Oyo State, Nigeria. *Corresponding author: gurumyeng@unijos.edu.ng; +2348030639783

SUMMARY

Vaginal leiomyomas are uncommon tumours and they may originate from vaginal smooth muscles, local arterial musculature, bladder or urethral smooth muscles. An 8-year-old Caucasian bitch was presented with a round pendulous smooth solid mass of about 5cm in diameter at the junction between the vestibule and vagina. Two other similar smaller masses were seen on the vaginal wall (0.4-0.6cm in diameter). Histopathologically, abundant densely packed spindle cells of uniform size, indistinct cellular borders, eosinophilic cytoplasm, and elongate, blunt-ended (cigar shaped) nuclei were seen. The cells appeared grouped in broad interlacing fibres at angles of 90 degree in a herringbone pattern, typical of smooth muscle tissue. In-depth examination of the reproductive tract should be carried out to avoid missing valuable diagnostic information that could help in proper intervention.

Key words: Intraluminal vaginal leiomyoma, canine, caucasian, leptospirosis, tumour

INTRODUCTION

Neoplasms of the canine reproductive tract are the second most common canine reproductive tumours and they account for three percent of all canine tumours, out of which 85 to 90 percent occur in the vagina and vulva (Thacher and Bradley, 1983; Herron, 1983). Benign smooth muscle tumours like leiomyomas, fibroleiomyomas

and fibromas occur most commonly in dogs (Baker and Lumsden, 1999) while leiomyosarcomas, lipomas, mastocytomas, adenocarcinomas, squamous cell carcinomas and transmissible venereal tumours occur much less frequently (Hill *et al.*, 2000). The incidence of leiomyomas is highest in dogs aged of 5 to 16 years

(McEntee, 2002). Vaginal leiomyomas are uncommon tumours and they may emerge from the vaginal smooth muscles, local arterial musculature, bladder or urethral smooth muscles. The anterior vaginal wall has been reported to be the most common site for vaginal leiomyomas (Tsili, 2017). Majority of leiomyomas arise from vestibule of the vulva rather than the vagina. There are two forms of leiomyoma namely extra-luminal and intra-luminal (Herron, 1983). Extra-luminal leiomyomas are generally slow growing tumours and they occur as perineal mass, while intra-luminal are pedunculated tumour that are attached to vestibular or vaginal wall and they may be found in multiple sites (Herron, 1983). While in the latter, the mucosa is generally intact, ulcerations may occur with exposure and irritation. Leiomyoma may be hormone dependent as it has not been diagnosed in ovariectomized dog of less than 2 years. The incidence of leiomyoma is reported to be higher in nulliparous bitches (Lee *et al.*, 2014). Vaginal leiomyomas may be single or multiple, intra-luminal or extra luminal. The tumour is usually round or oval, well defined and encapsulated. The size and consistency may vary depending on the duration of growth, usually becoming firmer with increase in connective tissue. Large intraluminal tumours may protrude through the vulva, while extra luminal tumours tend to cause perineal swelling. The perineal swelling may impinge on the urethra, consequently causing the animal to show signs of dysuria, constipation and tenesmus (Klein, 2007).

Leiomyomas of the reproductive tract in the bitch are frequently associated with oestrogen secreting tumours and or ovarian follicular cysts (Kydd and Burnie, 1986). Even though the role of oestrogen in the

aetiology of leiomyomas is unclear; there has been speculation that the transition of tissue from hyperplastic to neoplastic tissue may constitute stages in reproductive tract tumorigenesis in the female, in which oestrogen act as the stimulating factor (Bodinga *et al.*, 2019).

There has been no report on intraluminal vaginal Leiomyoma in Caucasian bitch. Hence, any information on clinical presentation and post mortem diagnosis of intraluminal vaginal Leiomyoma in Caucasian Dogs will be of great value to clinicians all over the world. In this case report, we present gross and histopathological lesions of intraluminal vaginal Leiomyoma in an 8-year-old Female Caucasian Dog.

CASE PRESENTATION

An eight (8) year old Caucasian bitch was presented to the Veterinary Teaching Hospital, University of Jos on the 19/9/2020 with the complain of not being able to conceive after several years of mating. The dog was on heat as at the time of presentation. Vaginal cytology was carried out and revealed a dysplastic vagina. On the 6/11/2020, the bitch was presented again for vaginal cytology due to observed bleeding and it was established that the bitch was on the oestrus stage of oestrous cycle. Ten days later, the bleeding was observed to have persisted and on the 4/1/2021, the vagina was examined and a solid mass was felt on palpation. Surgical intervention was advised and the bitch was booked for March, 2021 for surgery but the client did not show up until October 2021. Later, on the 11/11/2021, the owner brought the bitch for the surgery but the bitch died while waiting for the surgical intervention. The whole carcass was submitted for post mortem

examination where leptospirosis was suspected.

Post Mortem Examinations

The carcass had considerable emaciation and the visible mucous membranes were pale at necropsy. Anaemia was also indicated by the paleness of the tracheal wall. The mucosae of the intestines displayed ecchymosis, which was more severe in the duodenum and jejunum. The kidneys were moderately reduced. The cortical surfaces were rough with some depressed areas (necrosis). Fibrous tags were seen on the sliced surfaces of the renal cortex. A round pendulous smooth solid mass of about 5cm in diameter (Fig 1) was seen at the junction between the vestibule and vagina. Two other similar smaller

masses were seen on the vaginal wall (0.4-0.6cm in diameter). The following lesions led to the post-mortem diagnosis of leptospirosis: anaemia, haemorrhagic enteritis, and chronic nephritis. On a regular basis, sections of the mass on the vagina were kept in a 10% buffered formalin solution and prepared for paraffin embedding. Histological sections (4 mm thick) were stained with haematoxylin and eosin and viewed under a light microscope. Histopathologically, there were abundant densely packed spindle cells of uniform size, indistinct cellular borders, eosinophilic cytoplasm, and elongate, blunt-ended (cigar shaped) nuclei (Fig 3). The cells appeared grouped in broad interlacing fibres at angles of 90 degree in a “herringbone pattern” typical of smooth muscle tissue (Fig 2).

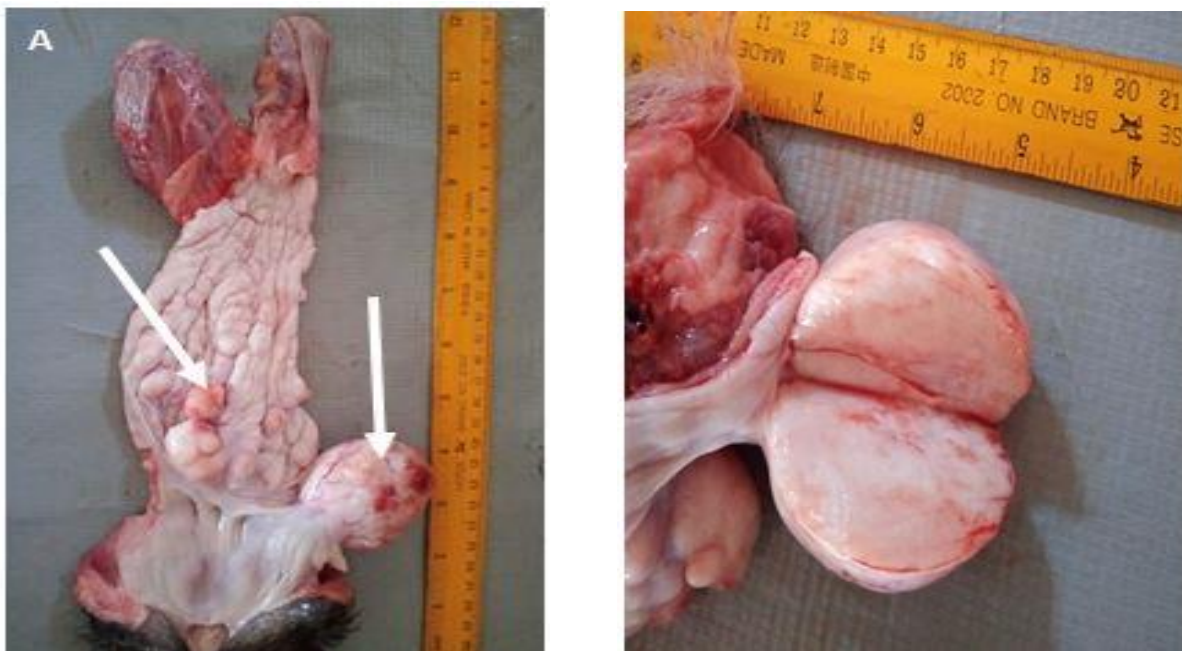

Figure 1: **A.** The vaginal cut open showing tumour masses measuring 0.4-0.6cm in diameter (arrows). **B** Crosssectional view of the vaginal mass

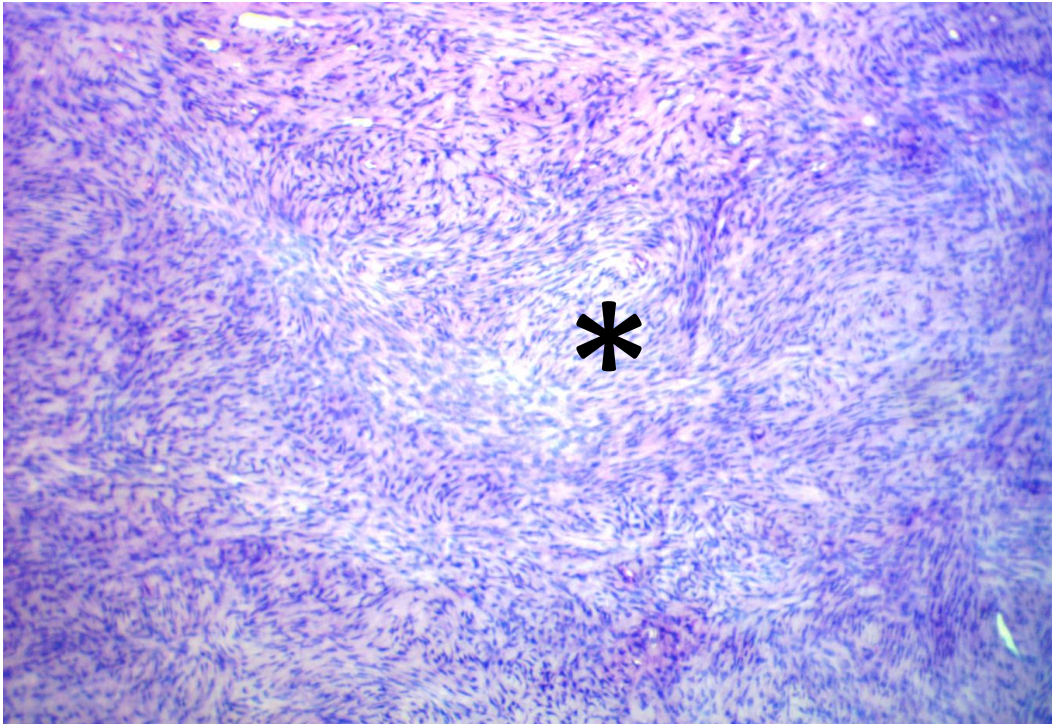


Figure 2: Photomicrograph of vaginal mass showing interlacing fascicles with eosinophilic cytoplasm forming a herringbone pattern (asterisk) H&E x100

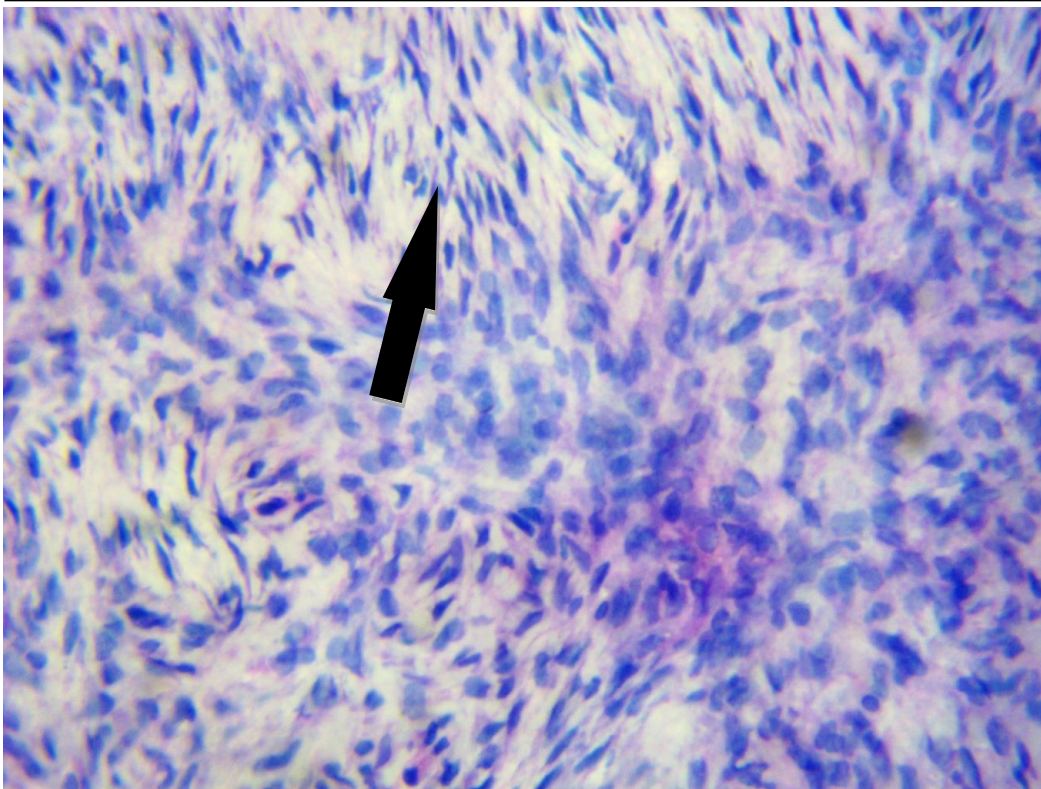


Figure 3: Photomicrograph of vaginal mass showing spindle-shaped cells with blind-ended nuclei (arrow) H&E x400

DISCUSSION

With the exception of transmissible venereal tumours, the cause of canine vaginal tumours is unknown. However, due to the high incidence of these categories of tumour in intact bitches, steroid hormones may play a role in aetiology of these tumours. In human genital neuro-fibromas, the expression of steroid hormone receptors, primarily progesterone receptors, have been incriminated (Umamageswari *et al.*, 2016). This may not be the different from the findings in this study where the vaginal cytology initially showed a dysplastic vagina when the dog was presented for staging of oestrous. There is strong evidence that steroid hormones, particularly oestrogens, play a key role in influencing target tissue development, differentiation, and functioning (Benassayag *et al.*, 1999). In a study by Howe *et al.*, (1995), leiomyoma cell line ELT3 was reported to have a proliferative response to oestrogen dose dependent increase in cell numbers following in-vitro administration of estradiol. The authors of the said study then compared the response to nearly 2-fold increase in anoestrogen-responsive MCP7 breast cancer cell line and the 2.2-fold increase in human ovarian adenocarcinoma cell line PEO4 (Lippman *et al.*, 1976; Langdon *et al.*, 1993). According to a theory, elevated oestrogen and progesterone levels are capable of inducing increase in

mitotic rate, which may lead to myoma formation by raising the risk of somatic mutation (Rein, 2000). Therefore, any drug that can suppresses the effect of oestrogen can be of therapeutic value in the management of leiomyomas. Here, we report multiple intraluminal encapsulated vaginal and vestibular leiomyoma in an 8-year-old Caucasian bitch which is consistent with those reported in dogs within the age of 5-15 years (Kang and Holmberg, 1983, Tanaka *et al.*, 2001; Sathya and Linn, 2014). This appears to be the first report of this tumour in the vagina of an intact Caucasian dog, even though it has been reported in beagle dog (Weller and Park, 1983), Blue Heeler bitch (Kang and Holmberg, 1983), mixed-breed Siberian husky (Sathya and Linn, 2014), crossbred bitch (Tanaka *et al.*, 2001), Doberman dog (Ferreira and Pinto, 2008) and Crossbred Rottweiler (Bodinga *et al.*, 2019). Although leiomyoma can be treated by surgical excision, the dog in this case might have died of suspected leptospirosis which is associated with high fatality in Jos, Plateau state and has been responsible for the death of dogs with tumour complications (Gurumyen *et al.*, 2022).

CONCLUSION

This case report appears to be the first report of intraluminal vaginal leiomyoma in an intact caucasian bitch which died of suspected leptospirosis. The findings

documented in this case is valuable to clinicians as it provides an alternative differential to Transmissible Veneral Tumour (TVT), a common reproductive tumour of dogs. In-depth examination of the reproductive tract should be carried out to avoid missing valuable diagnostic information that could help in proper intervention.

REFERENCES

- BAKER, R.H. and LUMSDEN J.H. (1999). Color Atlas of Cytology of the Dog and Cat, St. Louis, Mosby: Pp. 235-262.
- BENASSAYAG, C., LEROY, M.J., RIGOURD, B., ROBERT, J.C., HONORE, T.M., MIGNOT, M.C., VACHER-LAVENU, C. CHAPRON, C. and FERRE, F. (1999). Estrogen receptors (ER α /ER β) in normal and pathological growth of the human myometrium: pregnancy and leiomyoma. *American Journal of Physiology- Endocrinology and Metabolism*, **276**(6): E1112-E1118.
- BODINGA, H.A., ABUBAKAR, N., ABDULLAHI, N. and HASSAN, T. (2019). Vaginal Leiomyoma in a Crossbred Rottweiler Female Dog-a Case Report. *Asian Journal of Research in Animal and Veterinary Sciences*, **3**(3):1-4.
- FERREIRA, M. I. C. and PINTO, L. F. (2008). Homeopathic treatment of vaginal leiomyoma in a dog: case report. *International Journal of High Dilution Research-ISSN 1982-6206*, **7**(24):152-158.
- GURUMYEN, G.Y, AVAZI, D.O., JAMES, A.A., POLYCARP, T.N., TIZHE, E.V., BUBA, M.D., ADEKUNLE, L.A., USMAN, A.A., JARIKRE, T.A., JAGUN, A.J., ANTIA, R.E. and TAIWO, V.O. (2021). High grade tibiofibular canine osteosarcoma in a 5- year-old female rottweiler. *Savannah Veterinary Journal*, **4**(2):56–60.
- HERRON, M.A. (1983). Tumors of the canine genital system, *Journal of the American Animal Hospital Association*, **19**:981-994.
- HILL, T.P., LOBETTI, R.G. and SCHULMAN, M.L. (2000). Vulvo-vaginectomy and neo-urethrostomy for treatment of haemangiosarcoma of the vulva and vagina. *Journal of the South African Veterinary Association*, **71**:256-259.
- HOWE, S.R., GOTTARDIS, M.M., EVERITT, J.I. and WALKER, C.H.E.R.Y.L.(1995). Estrogen stimulation and tamoxifen inhibition of leiomyoma cell growth invitro and in vivo. *Endocrinology*, **136**(11):4996-5003.
- KANG, T.B. and HOLMBERG, D.L. (1983). Vaginal leiomyoma in a dog. *The Canadian Veterinary Journal*, **24**(8):258.
- KLEIN, M.K. (2007). Tumors of the female reproductive system. In Withrow, S.J, Vail, D.M (eds): Withrow & MacEwen's Small Animal Clinical Oncology. St. Louis, Saunders:pp. 610-618.
- KYDD, D.M. and BURNIE, A.G. (1986). Vaginal neoplasia in the bitch: a review offorty clinical cases. *Journal of Small Animal Practice*, **27**(4):255-263.
- LANGDON, S.P., RITCHIE, A., YOUNG,

- K., CREW, A.J., SMYTH, J.F., MILLER, W.R. and TESDALE, L. (1993). Contrasting effects of 17 β -estradiol on the growth of human ovarian carcinoma cells in vitro and in vivo. *International Journal of Cancer*, **55**(3):459-464.
- LEE, S.H., PARK, C.H., PARK, J.T., KIM, Y.M., OH, K. S. and SON, C. H. (2014). Extraluminal form of vaginal leiomyoma: two case reports. *Journal of Veterinary Clinics*, **31**(6):539-543.
- LIPPMAN, M., BOLAN, G. and HUFF, K. (1976). The effects of estrogens and Antiestrogen hormone-responsive human breast cancer in long-term tissue culture. *Cancer Research*, **36**(12):4595-4601.
- MCENTEE, M.C. (2002). Reproductive oncology. *Clinical Techniques in Small Animal Practice*, **17**:133-149.
- REIN, M.S. (2000). Advances in uterine leiomyoma research: the progesterone hypothesis. *Environmental Health Perspectives*:791-793.
- SATHYA, S. and LINN, K. (2014). Regression of a vaginal leiomyoma after ovariohysterectomy in a dog: a case report. *Journal of the American Animal Hospital Association*, **50**(6):424-428.
- TANAKA, R., HOSHI, K. and YAMANE, Y. (2001). Partial bladder resection in a bitch with urinary retention following surgical excision of a vaginal leiomyoma. *Journal of Small Animal Practice*, **42**(6):301-303.
- THACHER, C. and BRADLEY, R.L. (1983). Vulva and vaginal tumors in the dog: a retrospective study. *Journal of the American Animal Hospital Association*, **183**(6):690-692.
- TSILI, A. C. (2017). Vagina and vulva. In MRI and CT of the Female Pelvis. Springer, Cham: Pp. 343-368.
- UMAMAGESWARI, J., SRIDEVI, P., RANGASAMY, S. and SRIDHAR, R. (2016). Vaginal Leiomyoma in a pregnant bitch. *The Indian Journal of Animal Reproduction*, **37**(2).
- WELLER, R. E. and PARK, J. F. (1983). Vaginal leiomyoma and polyps in a beagle dog. *California Veterinarian*, **12**:6-9.