



## Epidemiological and Pathological Screening of Suspected Cases of Contagious Bovine Pleuropneumonia in Yola Modern Abattoir, Adamawa State Nigeria

Markus, I. F.<sup>1\*</sup>; Adamu, J.<sup>1</sup>, Allam, L.<sup>2</sup>, Kwanashie, C.N.<sup>1</sup>, Raji, M.A.<sup>3</sup>, Mohammed B.<sup>4</sup>

<sup>1</sup>Department of Veterinary Microbiology, Faculty of Veterinary Medicine, Ahmadu Bello University Zaria, Nigeria. <sup>2</sup>Veterinary Teaching Hospital, Faculty of Veterinary Medicine, Ahmadu Bello University Zaria, Nigeria. <sup>3</sup>Department of Veterinary Microbiology, Faculty of Veterinary Medicine, University of Ilorin, Nigeria. <sup>4</sup>Department of Veterinary Pathology, Faculty of Veterinary Medicine, Ahmadu Bello University Zaria, Nigeria. \*Corresponding author. Email: markusfrancisisa@yahoo.com. Mobile: +234 8055061010

### SUMMARY

Contagious bovine pleuropneumonia is an important infectious disease of cattle caused by *Mycoplasma mycoides* subsp. *mycoides* and a major constraint to cattle production in sub-Saharan Africa. This study was aimed to identify pathological and histopathological lesions identified in cattle tentatively diagnosed with CBPP at Yola Modern Abattoir, Adamawa State. A total of 9,750 cattle were examined at post-mortem for a period of six months, 110 (1.13%) had lesions suggestive of CBPP out of which seventeen (17) were randomly selected and processed for histopathology based on standard laboratory protocols. Based on sex, CBPP lesion was observed more in female 63 (1.06%) than in the male 47 (1.24%). Whereas, CBPP lesions was observed highest in White Fulani breed 68 (1.14%) followed by Cross breeds 23 (91.16%) and Sokoto Gudali 19 (1.74%) and lowest in Red Bororo 10 (1.36%). There was insignificant statistical association ( $P>0.05$ ) between CBPP lesions and sex and breed of cattle sampled. Age distribution of CBPP lesion was observed higher in cattle between ages of 4-7 years 79 (1.16%), followed by cattle of 1-3 years 28 (1.15%) and least in cattle less than 1 year 3 (0.60%) with significant statistical difference ( $P<0.05$ ) between the age groups. Histopathology lesions observed include severe congestion of pulmonary blood vessel in all the lung tissues and fibrin exudation into inter-alveolar spaces with almost all the alveoli collapsed. The bronchiolar epithelium was observed to be thickened, hyperplastic and folded, with a considerable quantity of edematous fluid and numerous inflammatory cells seen in the lumen. In conclusion, this study had demonstrated the presence of CBPP lesions in cattle in the study area. Therefore, serological screening of all cattle, stamping out policies and aggressive annual vaccination campaigns are thus recommended in the study area.

**Keywords:** Adamawa State; Cattle; CBPP; Histopathology lesions; Neutrophil erythrophagocytosis

## INTRODUCTION

Contagious bovine pleuropneumonia (CBPP) is an economically important and highly infectious disease of cattle characterized by localization in the lungs and pleura, caused by *Mycoplasma mycoides* subspecies *mycoides* (*M. mycoides* subsp. *mycoides*) and a major constraint to cattle production in sub-Saharan Africa (Manso-Silvan *et al.*, 2009; Fischer *et al.*, 2015). In Nigeria, CBPP has been reported causing consolidation, marbling of lung tissues and accumulation of pleural fluid in the thoracic cavity (Olorunshola *et al.*, 2020). It causes pulmonary disease that ranges from persistent, sub-clinical infection to an acute, sometimes fatal disease (Ikpa *et al.*, 2020; Ola *et al.*, 2020). Naive herds can experience losses up to 80%, and cattle that survive remain chronic carriers which may suffer from recurrent low-grade fever, loss of condition, and respiratory signs upon exercise, and might introduce the causative agent into uninfected herds (Campbell, 2015).

Post-mortem (PM) evaluation of lesions provides important information in the management of the health status of vulnerable animals (Di Provvido *et al.*, 2018). Pathological lesions during CBPP infections are generally restricted to the thoracic cavity, usually one lung and pleura are affected and a large volume of pleural exudates containing clots of fibrin (Fischer *et al.*, 2012; OIE, 2018). Large fibrin deposits make the lung adhere to the chest wall and at these sites, the pleura is thickened and opaque (Gull *et al.*, 2013). The interlobular septa of affected lung regions are also thickened due to adsorption of the exudates and “frame” the

lung lobules, which vary in colours of red, grey and yellow due to different stages of inflammatory lesions giving the characteristic “marbled” appearance (Olorunshola *et al.*, 2020). Necrotic lesions in the lung are enclosed by capsules of fibrous connective tissue forming structures called sequestra with varying sizes from 1-30 cm in diameter (Nicholas *et al.*, 2008; OIE, 2018). A sequestrum is believed to be a source of infection if it is ruptured or drained by a bronchus, but no evidence of this has been published (Egwu *et al.*, 1996; Ola *et al.*, 2020).

Perivascular organisation foci or 'organising centers', found in the interlobular septa, are considered pathognomonic for CBPP (Nicholas *et al.*, 2008). They consist of a center occupied by a blood vessel with proliferation of connective and inflammatory cells surrounded by a peripheral zone of necrotic cells (Nicholas *et al.*, 2008; AU-IBAR, 2013). The thoracic cavity may contain up to 10 litres of clear yellow or turbid fluid mixed with fibrin flakes and the organs covered by thick deposits of fibrin (Weldearegay *et al.*, 2015). The disease is largely unilateral, with more than 80-90% of cases affecting only one lung and the affected portion is enlarged and solid (OIE, 2015).

Microscopically, there was severe, acute, fibrinous pneumonia with fibrinous pleurisy, thrombosis of pulmonary blood vessels, and areas of necrosis of lung tissue; the interstitial tissue is markedly thickened by edema fluid containing much fibrin. In chronic cases, the lesion has a necrotic center sequestered in a thick, fibrous capsule, and there may be fibrous pleural adhesions. Organisms may survive only

within the inner capsule of these sequestra, and these animals may become carriers (Campbell, 2015).

The present study aimed to confirm various pathological changes induced by CBPP in cattle at slaughter, identify the lesions in lung samples collected in the study area for the understanding of lesions and associated pathogenesis.

## MATERIALS AND METHODS

### Sample Collection

A total of seventeen (17) lung tissues (Figure 1) of slaughtered cattle were randomly collected from 110 lung lesions suggestive of CBPP for a period of 6 months at Yola Modern Abattoir, Adamawa State. A tissue sample of about 5 gram was cut at the junction between normal and affected area, placed directly into a sample bottle containing 10% neutral buffered formalin and labelled appropriately for histopathology processing. The cattle sampled were indigenous breeds normally presented for slaughter in the study area and comprised of White-Fulani, Red Bororo, Adamawa Gudali and their crosses. The animals were aged 3-7 years using standard procedure for aging described by Lasisi *et al.*, (2002).

### Histopathological Examination

Seventeen (17) positive lung tissues were processed at the Histopathology laboratory,

Department of Veterinary Pathology, Ahmadu Bello University Zaria for histopathological lesions according to the method described by Baker *et al.* (2000). The fixed samples were processed for histopathological assessment by dehydration in graded concentrations of alcohol (70%, 80%, 95% and 100%), cleared using Xylene, impregnated in plastic embedding rings and sectioned at 5µm using microtome. The tissues were then depolarized with Xylene, rehydrated in graded concentrations of alcohol (100%, 95%, 80% and 70%), stained with Haematoxylin and Eosin (H&E) stain and viewed under light microscope (Bancroft and Layton, 2018)

### Statistical Analysis

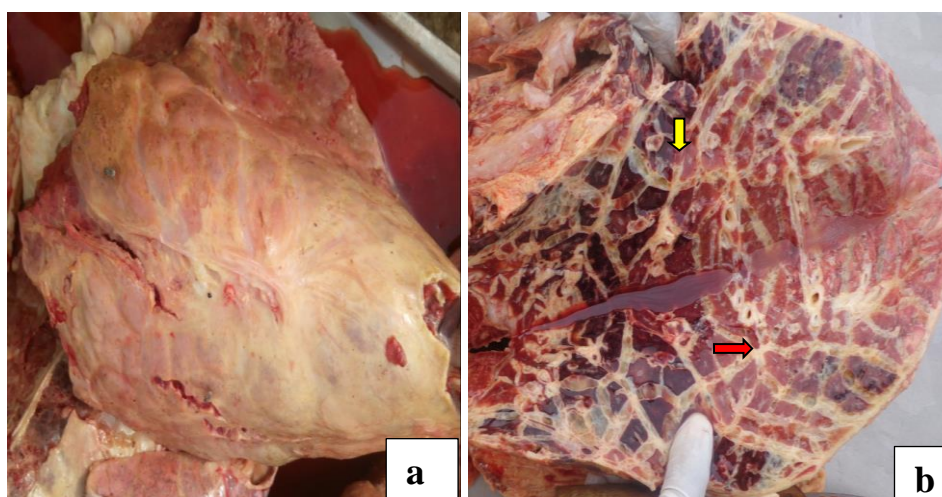
Data collected were analyzed using simple percentage, while Fisher's Exact test was used to test the level of significance between sex, age and breeds of cattle, and the value of  $P < 0.05$  was considered statistical significant.

## RESULTS

Distribution of cattle examined for lung lesions in Yola Modern Abattoir is shown in Table I. A total of 9,750 cattle were examined at post-mortem, 110 (1.13%) had lesions of extensive fibrosis, hepatisation with marble appearance pathognomonic of CBPP (Plate 1), out of which seventeen (17) were randomly selected for histopathology.

**TABLE I: Distribution of cattle examined for lung lesions at Yola Modern Abattoir**

Variables	No. examined at PM	No. with lesions (Prevalence %)	No. selected for histopathology	P-value
<b>Sex</b>				
Male	3,802	47 (1.24)	5	0.4596
Female	5,948	63 (1.06)	12	
<b>Age (years)</b>				
<1	497	3 (0.60)	1	0.001
1-3	2,438	28 (1.15)	4	
4-7	6,815	79 (1.16)	12	
<b>Breed</b>				
White Fulani	5,948	68 (1.14)	10	0.999
Red Bororo	735	10 (1.36)	2	
Sokoto Gudali	1,093	19 (1.74)	2	
Cross breed	1,974	23 (1.16)	3	
<b>TOTAL</b>	<b>9,750</b>	<b>110 (1.13)</b>	<b>17</b>	



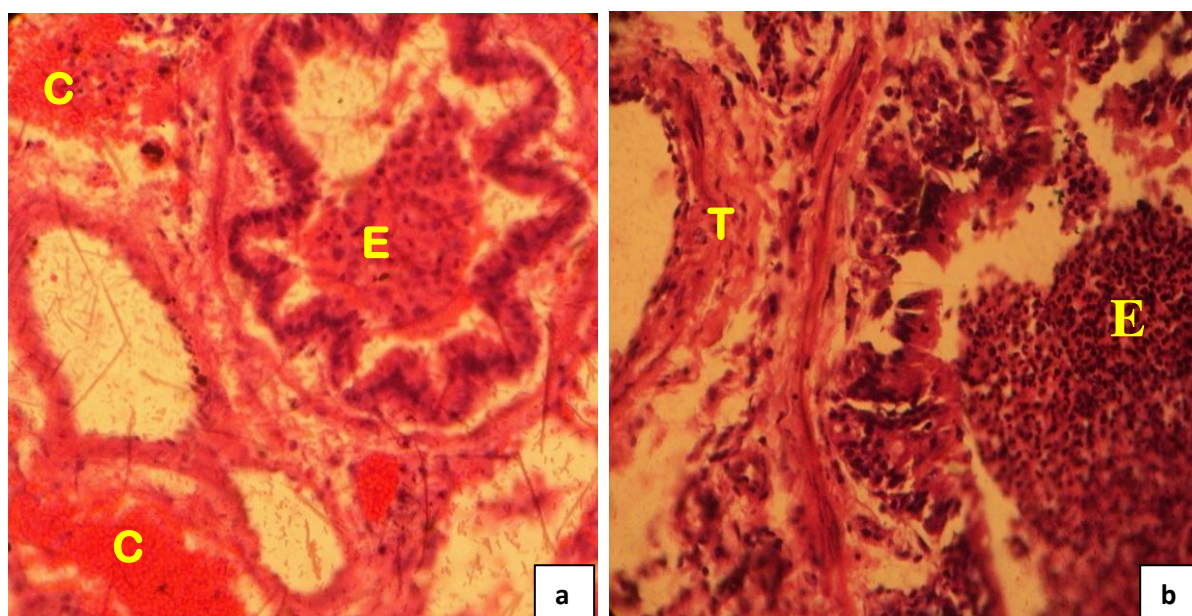
**Plate 1: Typical gross appearance of suspected pneumonic lungs at Yola Modern Abattoir, Adamawa State. A condemned CBPP lung (a) and an opened lung (b) showing gross lesions of extensive fibrosis (red arrow), hepatisation (yellow arrow) with marble appearance pathognomonic of CBPP**

Based on sex, CBPP lesion was observed more in female 63 (1.06%) than in the male 47 (1.24%). Whereas, CBPP lesions was

observed highest in White Fulani breed 68 (1.14%) followed by Cross breeds 23 (1.16%) and Sokoto Gudali 19 (1.74%)

and lowest in Red Bororo 10 (1.36%). There was insignificant statistical association ( $P>0.05$ ) between CBPP lesions and sex and breed of cattle sampled. Age distribution of CBPP lesion was observed higher in cattle between ages of 4-7 years

79 (1.16%), followed by cattle of 1-3 years 28 (1.15%) and least in cattle less than 1 year 3 (0.60%) with significant statistical difference ( $P<0.05$ ) between the age groups.



**Plate 2: Photomicrograph of a lung tissue positive for *Mmm* in Adamawa State showing congestion (C), exudation (E) of fluid into the bronchiole, thickened pulmonary blood vessel (T) with alveolar spaces filled with pinkish fluid. H&E X200 (a), X400 (b)**

Histopathology showed severe congestion of pulmonary blood vessel (Plate 2a) and fibrin exudation into inter-alveolar spaces with almost all the alveoli collapsed. There was interstitial pneumonia accompanied by mononuclear cellular infiltration with numerous macrophages, few lymphocytes and neutrophils many of which have engulfed erythrocytes (erythrophagocytosis). The bronchiolar epithelium was observed to be thickened, hyperplastic and folded, with a considerable quantity of edematous fluid and numerous inflammatory cells seen in the lumen (Plate 2b).

## DISCUSSION

Contagious bovine pleuropneumonia has been reported as a most important cause of lung condemnation in slaughtered cattle (Attoh-Kotoku *et al.*, 2018), and the most common type of pneumonia prevalent in cattle in Nigeria (Francis *et al.*, 2018; Ola *et al.*, 2020). In CBPP infected animals, high proportion of lung samples were reported to have aggregates of pathological lesions which can be ascribed to cranio-ventral pattern of the disease with most lobes of the lung affected (Di Provvio *et al.*, 2018). Infected animals has previously been reported to had pulmonary

haemorrhages, thickening of interlobular septa, pulmonary edema, bronchiolitis and alveolitis as described by Anjum *et al.* (2020). The gross pathological lung lesions observed in the tissues collected such as fibrosis, hepatisation with marble appearance reflected the typical pathological patterns previously described for CBPP (Caswell and Williams, 2007). Histopathology examination revealed lesions of interstitial pneumonia accompanied by perivascular and peribronchiolar lymphoid cell infiltration of mostly macrophages with few lymphocytes and neutrophils. Accumulation of cells and serous exudates in bronchioles and inter-alveolar spaces with catarrhal pneumonia, seen in this study were comparable to the earlier reports (Rodriguez *et al.*, 1996; Ajuwape *et al.*, 2003; Gagea *et al.*, 2006; Kumar *et al.*, 2012). The present study also reported accumulation of inflammatory cells in alveoli, bronchioles as well as necrotic debris in bronchiolar lumen and pulmonary congestion and this buttressed previous findings of Li *et al.* (2016).

## CONCLUSIONS AND RECOMMENDATIONS

This study had demonstrated the presence of CBPP in cattle with gross lesions evident in most of the lobes and various hepatisation of the lung. Based on histopathology, there was congestion of affected lungs, exudation of fluid with high number of inflammatory cell in the bronchiole. Therefore, serological screening of all cattle, stamping out policies and aggressive annual vaccination campaigns are recommended in the study area.

## ACKNOWLEDGEMENTS

The authors wish to acknowledge all staff of Ministry of Livestock Production Yola for assistance and cooperation and Mr. Bitrus Bako (Late) of Histopathology Laboratory, Department of Veterinary Pathology, Ahmadu Bello University Zaria for processing the histopathology slides.

## REFERENCES

- AU-IBAR (African Union-Interafrican Bureau for Animal Resources) (2013). Panafican Animal Health Yearbook 2013 Contagious Bovine Pleuropneumonia, pp. 1-45.
- AJUWAPE, A.T. P., IKHELOA, J. O., OJO, M. O., ALAKA, O. O and ADATOSOYE, A. J. (2003). Biochemical and serological identification of mycoplasmas isolated from pneumonic bovine lungs in Nigeria. *Israel J. Vet. Med. Microbiol. Parasitol*, 58: 2-8.
- ANJUM, A., ASLAM, A., AKHTAR, R., YAQUB, T., KHAN, M., SULTAN, R., USMAN, S., DURRANI, A. Z. and USMAN M. (2020). Molecular detection and pathological investigation of CBPP in selected Districts of Punjab, Pakistan. *Pakistan J. Zool*, 52(2): 797-800.
- ATTOH-KOTOKU, V., EMIKPE, B. O., OBUADEY, D., ISHOLA, O., OSAFO, E. K., DONKOH, A. and FOLITSE, R. (2018). Pattern and direct financial implications of

- contagious bovine pleuropneumonia in cattle slaughtered in Kumasi Abattoir, Ghana. *Anim. Res. Inter*, 15(1): 2937-2943.
- BAKER, J., SILVERTON, R. E. and PILLISTER, C. J. (2000). Dehydration, Impregnation, Embedding Techniue and Section Preperation. *Introduction to Medical Laboratory Technology*, 7<sup>th</sup> Edition, pp. 199-242.
- BANCROFT, J. D. and LAYTON, C. (2018). The haemotoxylins and eosin. In: Suvarna, S. K., Layton, C. and Bancroft, J. D (Editors). *Bancroft's theory and practice of histological techniques*. Elsevier, China, pp. 126-129.
- CAMPBELL, J. (2015). Contagious bovine pleuropneumonia. In: Kahn, C. M., Line, S. and Aiello S. E, (Eds). *The Merck veterinary manual* [online]. Whitehouse Station, NJ: Merck and Co. Available at: [http://www.merckvetmanual.com/mvm/respiratory/system/respiratory\\_diseases\\_of\\_cattle/contagious\\_bovine\\_pleuropneumonia.html](http://www.merckvetmanual.com/mvm/respiratory/system/respiratory_diseases_of_cattle/contagious_bovine_pleuropneumonia.html). Accessed 4th November, 2015.
- CASWELL, J. L. and WILLIAMS, K. J. (2007). Respiratory System. In: Maxie, M. G. (Editors). *Jubb, Kennedy and Palmer's Pathology of domestic animals*. Elsevier Saunders, New York, pp. 610-612.
- DI PROVVIDO, A., DI TEODORO, G., MUUKA, G., MARRUCHELLA, G. and SCHACCHIA, M. (2018). Lung lesions score system in cattle: proposal for contagious bovine pleuropneumonia. *Trop. Anim. Hlth. Prod*, 50(1): 223-228.
- EGWU, G. O., NICHOLAS, R. A. J., AMEH, J. A. and BASHIRUDDIN, J. B. (1996). Contagious bovine plueropneumonia: An update. *Vet. Bull*, 66: 875-888.
- FISCHER, A., SHAPIRO, B., MURIUKI, C., HELLER, M. and SACHSE, C. (2012). The origin of the *Mycoplasma mycoides* clusters coincides with domestication of ruminants. *PLOS ONE*, 7(4): e36150. doi:10.1371/journal.pone.0036150
- FISCHER, A., SANTANA-CRUZ, I., HEGERMAN, J., GOURLE, H., SCHIECK, E., LAMBERT, M., NADENDLA, S., WESONGA, H., MILLER, R. A., VASHEE, S., WEBER, J., MEENS, J., FREY, J. and JORES, J. (2015). High quality draft genomes of the *Mycoplasma mycoides* subsp. *mycoides* challenge strains Afade and B237. *Stand. Gen. Sci*, 10:89-98.
- FRANCIS, M. I., ORAGWA, A. O., ANKELI, P. I., LIBA, J. W., EJEH, E. F., RAJI, M. A., AMEH, J. A. and EGWU, G. O. (2018). Prevalence of contagious bovine pleuropneumonia based on gross lesions in cattle at slaughter in

- Adamawa State, Nigeria. *Sokoto J. Vet. Sci*, 16(1): 31-37.
- GAGEA, M. I., BATEMAN, K. G., SHANAHAN, R. A., VAN DREUMEL, T., MCEWEN, B. J., CARMAN, S., ARCHAMBAULT, M. and CASWELL, J. L. (2006). Naturally occurring *Mycoplasma bovis*-associated pneumonia and polyarthritis in feedlot beef calves. *J. Vet. Diagn. Invest*, 18: 29-40.
- GULL, T. B., FRENCH, R. A., GORTON, T. S., BURRAGE, T. G., PROZESKY, L., GEARY, S. J. and ADAMS, G. L. (2013). Models of Contagious Bovine Pleuropneumonia: Evaluation of Two Novel Strains. *Open Vet. Sci. J*, 7: 23-33.
- IKPA, L. T., BWALA, D. G., ANKELI, P. I., KAIKABO, A. A., MAICHIBI, M. S., MURIANA, I. A., ABENGA, J. N., NWANKPA, N. D. and ADAH, M. I. (2020). Isolation and molecular characterization of *Mycoplasma mycoides* subspecies *mycoides* in three agro-ecological zones of Nassarawa State, Nigeria. *Open J. Vet. Med*, 10: 15-26.
- KUMAR, A., VERMA, A. K., GANGWAR, N. K. and RAHAL, A. (2012). Isolation, characterization and antibiogram of *Mycoplasma bovis* in sheep pneumonia. *Asian J. Anim. Vet. Adv*, 7(1): 149-157.
- LASISI, O. T., OJO, N. A. and OTESILE, E. B. (2002). Estimation of age of cattle in Nigeria using rostral dentition. *Trop. Vet*, 20(4): 204-208.
- LI, Y., WANG, Y., WANG, R., ZHU, Y., LIU, S., WANG, Q., SHAO, J., CHEN, Y., GAO, L., ZHOU, C., LIU, H., WANG, X., ZHENG, H. and XIN, J. (2016). Changes in pathogenicity and immunogenicity of *Mycoplasma mycoides* subsp. *mycoides* strains revealed by comparative genomics analysis. *Sci. Rep*, 6: 19081-19090.
- MANSO-SILVÁN, L., VILEI, E. M., SACHSE, K., DJORDJEVIC, S. P., THIAUCOURT, F. and FREY, J. (2009). Proposal to assign *Mycoplasma leachii* sp. nov. as a new species designation for *Mycoplasma* spp. bovine group 7 of leach, and reclassification of *Mycoplasma mycoides* subsp. *mycoides* LC as a serovar of *Mycoplasma mycoides* subsp. *capri*. *Int'l. J. Syst. Evo. Microbiol*, 59(6): 1353-1358.
- NICHOLAS, R. A. J., AYLING R. D. and MCAULIFFE L. (2008). Contagious bovine pleuropneumonia. In: *Mycoplasma Diseases of Ruminants*. Nicholas, R., Ayling, R. and L. McAuliffe (Editors.), CABI Publishing, Wallingford, UK, pp. 69-97.
- OIE (Office International des Epizooties) (2015). World animal health information database (WAHID)



- [database online]. Contagious bovine pleuropneumonia. Paris:OIE; 2015. Available at: <http://www.oie.int/wahis2/public/wahid.php/Diseaseinformation/statuslist>. Accessed 16th November, 2015.
- OIE (Office International des Epizooties) (2015). Manual for Diagnostic Tests and Vaccines for Terrestrial Animals Chapter 3.7.4. Pp, 1441-1455.
- OLA, O. O., ADENIRAN, G. A., OPOKU-AGYEMANG, T., BEDIAKO, E., ISHOLA, O., JARIKRE, T. A. and EMIKPE, B. O. (2020). Pathology and immunohistochemical evaluation of lungs of cattle slaughtered at metropolitan abattoirs in Nigeria and Ghana. *J. Immunoassay Immunochem*, [doi.org/10.1080/15321819.2020.1730889](https://doi.org/10.1080/15321819.2020.1730889).
- OLORUNSHOLA, I. D., DAODU, B. O., AJIBOYE, B., FOLARANMI, E. B., NICHOLAS, R. A. J. ADEGBOYE, D. S. and PETERS, A. R. (2020). Prevalence of contagious bovine pleuropneumonia and contagious caprine pleuropneumonia in the Middle-Belt of Nigeria. *Afr. J. Microbiol. Res*, 14(1): 25-31.
- RODRIGUEZ, F., BRYSON, D. G., BALL, H. J. and FORSTER, F. (1996). Pathological and immunohistochemical studies of natural and experimental *Mycoplasma bovis* pneumonia in calves. *J. Comp. Pathol*, 115: 151-162.
- WELDEAREGAY, Y. B., PICH, A., SCHIECK, E., LILJANDER, A., GICHERU, N., WESONGA, H., THIAUCOURT, F., KIIRIKA, L. M., VALENTIN-WEIGAND, P., JORES, J. and MEEMS, J. (2015). Proteomic characterization of pleural effusion, a specific host niche of *Mycoplasma mycoides* subsp. *mycoides* from cattle with CBPP. *J. Prot*, 131: 93-103.