



Pathological Changes in an Alsatian Dog following Amitraz and Sniper (Dichlorvos) Exposure

Abalaka, S.E.^{1*}, Ajagbe, O.A.², Mshelbwala, P.P.^{3,4}

¹Department of Veterinary Pathology, University of Abuja, Nigeria. ²Veterinary Teaching Hospital, University of Abuja, Abuja, Nigeria. ³Department of Veterinary Medicine, University of Abuja, Abuja, Nigeria. ⁴School of Veterinary Science, University of Queensland, Gatton, Australia. *Corresponding author: samson.abalaka@uniabuja.edu.ng. Mobile: +2348187384271

SUMMARY

Amitraz and Sniper (dichlorvos) are known ectoparasiticides of dogs in Nigeria. Although reports of their toxicosis exist, information on the pathological presentations of their combined toxicosis is scanty hence the present case report. Two dogs both had Amitraz bath with simultaneous fumigation of their immediate environment with Sniper (dichlorvos). Excessive salivation, staggering gait, and respiratory distress were observed shortly thereafter with the prompt administration of atropine sulphate which ameliorated it, but a particular dog progressively became weak, inactive and off feed. A vomitus, dark watery stool and blood spots were observed within its kennel before death. The post-mortem examination revealed emaciated, dehydrated and tick infested carcass with pale ocular and oral mucous membranes. There was also ileocolic intestinal intussusception characterized by anal intussusceptum protrusion, congested liver and pulmonary peribronchial haemorrhage with inter-alveoli cellular infiltration including haemorrhagic enteritis. Death might have been due to hypovolemic shock following the observed dehydration, pallor, haematochezia, peritoneal fluid exudation, hepatic congestion, pneumonia characterized by peribronchial haemorrhages, and haemorrhagic enteritis. The observed intussusception was a rare occurrence in a dog following Amitraz and Sniper poisoning in Abuja, Nigeria, which highlighted the need for their cautious and professional use.

Key words: Dog, Amitraz, Sniper (Dichlorvos), Intoxication,

INTRODUCTION

Amitraz is a formamidine family insecticide containing triazapentadiene [1,5 di- (2,4-

dimethyl phenyl)-3-methyl-1, 3,5-triazapenta- 1,4 diene] (Jorens *et al.*, 1997), which is a known insecticide and acaricide in veterinary practice and apiculture (Radakovic

et al., 2013). Amitraz poisoning in dogs is known to cause varying signs ranging from central nervous system depression to miosis and rarely, mydriasis, respiratory depression, bradycardia, hypotension, hypertension, hypothermia or fever, hyperglycaemia, polyuria, vomiting, decreased gastrointestinal motility, and intestinal distension (Jorens *et al.*, 1997). Sniper contains 1000 gL⁻¹ of dichlorvos or 2, 2-dichlorovinyl dimethyl phosphate (DDVP) as produced by Hubei Sanonda Co. Ltd., China. Dichlorvos is an organophosphate used to control insects on crops, household, and stored products, as well as in the treatment of external parasitic infections in farmed fish, livestock and domestic animals (Ben *et al.*, 2015). Snow & Watson (1973) have reported salivation, muscle fasciculation, involuntary urination, diarrhoea that may be bloody at times, tenesmus, and death in dichlorvos poisoning in dogs.

Both Amitraz and dichlorvos can become poisonous via the nasal, dermal, and oral routes (Clark, 2002). However, dermal absorption is relatively slower for Amitraz toxicosis in dogs following bathing at the recommended p doses (Paradis 1999). On the other hand, high environmental temperature or direct exposure to visible or UV light reportedly enhances dichlorvos toxicity (Clark, 2002). Amitraz toxicity in dogs has been reported (Gberindyer & Omotosho, 2015) just like dichlorvos poisoning in dogs (Snow & Watson, 1973). Nevertheless, reports of the pathological presentations of each or their combined intoxications are scarce, thereby necessitating this case report. Such reports will also highlight the inherent danger associated with the unprofessional application of these potentially toxic compounds as acaricides on dogs and within their environments, including poor

management of their intoxications by dog owners in terms of seeking prompt veterinary attention late in a developing country like Nigeria. Therefore, this report presents a case of pathological changes at post-mortem examination of a 17 month-old Alsatian dog following Amitraz and Sniper (dichlorvos) exposure in Abuja, Nigeria.

MATERIALS AND METHODS

A 17-month old Alsatian dog presented to the Veterinary Teaching Hospital, University of Abuja, Abuja, Nigeria, came with complaints of weight loss, alopecia and ticks infestation. Although the dog reportedly had an up-to-date vaccination history, that of the routine deworming was not available. The clinicians consequently administered Diminazene aceturate, Ivermectin and Prazi-Wormer^(R) to the dog following physical examination given the tick infestation and the apparent lack of deworming history. The client was also advised to de-tick both dogs and their immediate environment with appropriate acaricides by qualified personnel.

However, both dogs were reportedly bathed with Amitraz with simultaneous fumigation of their kennels with Sniper (dichlorvos) 18 days later by the owner. Shortly after that, both dogs reportedly started salivating excessively with dyspnoea and staggering gait necessitating atropine sulphate administration. This particular dog progressively became weak and anorexic while voiding some blood coupled with the protrusion of a reddish mass from its anus before death. There was also evidence of vomitus and watery dark stool in the kennel. The fresh carcass, which was in right lateral recumbency, was immediately presented to the Post-mortem Unit, Department of Veterinary Pathology, University of Abuja, Abuja, Nigeria for post mortem examination. Ticks were collected and sent to the laboratory of the Department

of Veterinary Parasitology and Entomology, University of Abuja, Abuja, Nigeria for parasitological identification. Liver, kidney, lung, and intestinal samples were promptly collected and fixed in 10% neutral buffered formalin for histopathological preparation and processing according to standard procedures (Bancroft and Cook 1994).

RESULTS AND DISCUSSION

The carcass was in poor body condition (body score of 4/9) with about 10% dehydration characterized by sunken eyes amongst others. Ocular and oral mucous membranes were pale with the presence of ticks within the inner ear pinna identified as *Rhipicephalus sanguineus*. Although pale mucous membranes are consistent with anaemia, pallor can also be seen in severe shock (Walton and Tappin, 2017). The ante-mortem anaemia in the presence of the tick infestation and emaciation could be indicative of haemoparasitism, especially in the absence of a follow-up treatment to the earlier one. The haemoparasitism was probably because the owner instead resorted to self medication/ectoparasiticide application only to call for veterinary attention when the prognosis of the case was became poor. Other gross lesions were pale lungs and currant jelly clots within heart chambers, including ecchymotic haemorrhages on the serosal surface of the the urinary bladder. The peritoneal cavity contained about 145 ml of blood-tinged fluid with a visibly swollen and congested distal ileum. Besides, the lower ileum telescoped into the colon at the ileocolic junction to protrude outside the anus (Plate 1). No noticeable histopathological changes occurred within the kidneys, but the liver showed moderate multifocal

congestion (Plate 2). There were generalized bronchial and peribronchial haemorrhages with inter-alveoli mononuclear cellular infiltration within the lung (Plate 3). The clinicians observed thickened ileac mucosa with diffuse mucosal haemorrhages and mononuclear cellular infiltrations, including diffuse sub-mucosal haemorrhages with marked reactive Peyer’s patches (Plate 4). The observed results consequently led to a diagnosis of ileocolic intussusception with protruding intussusceptum from the anus.

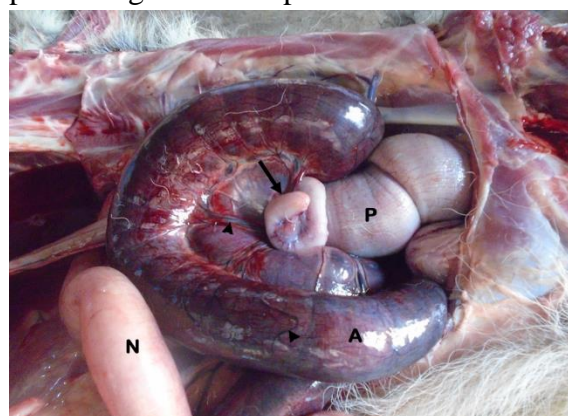


PLATE 1: The photograph of the intestine of a 17 month- old Alsatian dog following Amitraz and dichlorvos exposure. Note the normal intestine (N) with the swollen, markedly congested intestine (A) as well as engorged mesenteric veins (arrowheads) proximal to the intussusceptions ring (arrow) at the ileocolic junction with the enlarged hard intussusciptions to the anus (P).

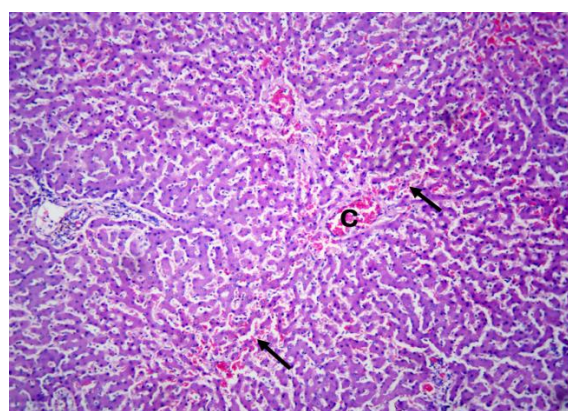


PLATE 2: The photomicrograph of the liver of a 17 month-old Alsatian dog following Amitraz and dichlorvos exposure. Note the congestion of the central veins (C) and hepatic sinusoids (arrows). H & E X 100

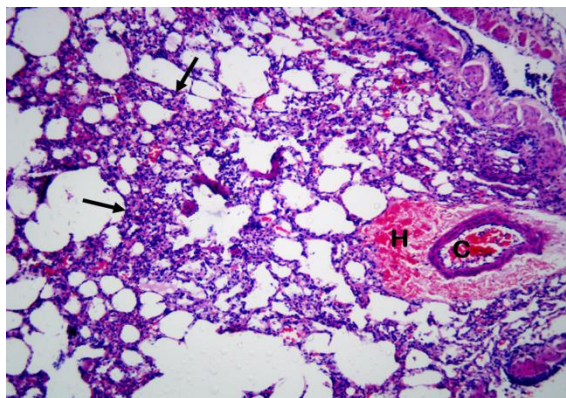


PLATE 3: The photomicrograph of the lung of a 17 - month old Alsatian dog following Amitraz and dichlorvos exposure. Note the peribronchial haemorrhage (H), bronchiolar haemorrhage (C), and moderately infiltrated alveolar interstitium with mononuclear cells (arrows). H & E X 100

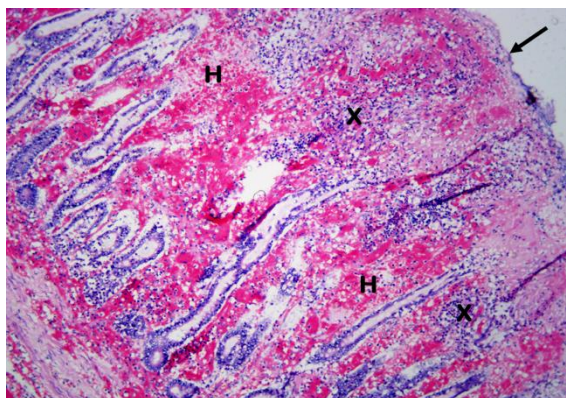


PLATE 4: The photomicrograph of the intestine of a 17 month-old Alsatian dog following Amitraz and dichlorvos exposure. Note the thickened mucosa (arrow) with generalized haemorrhages (H) and multifocal areas with mononuclear cellular infiltrates (X). H & E X 100

Although the exact causes of intussusception largely remain unknown (Garcia-Sancho *et al.*, 2012), hard straining associated with tenesmus occasioned by dichlorvos intoxication could have been responsible in the present case according to Ongom & Lukande (2013). The swollen and congested intestine and mesentery was attributable to vascular compromise occasioned by the venous return strangulation caused by the

muscular ring at the neck of the intussusception. The presence of a space between the rectum and the protruding mass precluded rectal prolapsed in the present case (Applewhite *et al.*, 2002). Similarly, the presence of haematochezia before death, the blood-tinged fluid within the peritoneum as well as haemorrhages and mononuclear cellular infiltration of the intestinal wall ruled out agonal intussusception occasionally seen at post-mortem examinations (Applewhite *et al.*, 2002).

The observed haemorrhages were due to the vascular compromise while the reactive Peyer's patches were part of the inflammatory responses in the affected part of the ileum. Intussusception is known to cause an obstruction as well as inflammatory and vascular changes ranging from mucosal thickening to ischaemia of the affected part of the gastrointestinal tract (Marinis *et al.*, 2009) as observed in this case. Hypovolemic shock, electrolyte disturbances, and acid-base imbalance are more characteristic of upper intestinal intussusceptions (Markowitz *et al.*, 1964). However, one cannot completely rule out hypovolemic shock-induced death in the present case due to the observed dehydration, pallor, intestinal and mesenteric congestion, peritoneal fluid exudation, haemorrhagic enteritis, and haematochezia. Individual idiosyncrasies and the extent of exposure, amongst others might be responsible for the survival of the second dog even though they were both exposed to the same chemicals and at the same time. This report is a pathological presentation of rare case of intussusception characterized by anal intussusceptum protrusion occurrence in an Alsatian dog following Amitraz and dichlorvos exposure in Abuja, Nigeria. The report also highlighted the inherent danger associated with unprofessional misapplication of these potentially harmful chemicals,

thereby calling for their cautious use, especially by unqualified personnel at each point in time.

ACKNOWLEDGEMENT

The authors appreciate the immense support of Mr Timothy Bulus during the post-mortem examination.

DECLARATION OF POTENTIAL CONFLICTING INTEREST

The authors privately sponsored the work and, therefore, declare no potential conflicts of interest.

REFERENCES

APPLEWHITE, A.A., CORNELL, K.K. and SELCER, B.A. (2002): Diagnosis and treatment of intussusceptions in dogs. *Compendium on Continued Education for the Practicing Veterinarian – North American Edition* 24:110-127.

BANCROFT, J.D. and COOK, H.C. (1994): *Manual of Histological Techniques and Their Diagnostic Application*. Churchill Livingstone; London: 289-305.

BEN, S., BOUSSABBEH, M., BACHA, H. and ABID, S. (2015): Dichlorvos-induced toxicity in HCT116 cells: Involvement of oxidative stress and apoptosis. *Pesticide Biochemistry and Physiology* 119:62-66. doi.10.1016/j.pestbp.2015.02.004.

CLARK, R.F. (2002): Insecticides: Organic phosphorus compounds and carbamates. *Goldfrank's*

Toxicological Emergencies. 7th Ed. McGraw-Hill Professional: New York: 1346-1360.

GARCIA-SANCHO, M., RODRIGUEZ-FRANCO, F., RODRIGUEZ-BERTOS, A., CARRASCO, V., VILLAESCUSA, A., SAINZ A. (2012): Transient ileocolic intussusception in a dog with histiocytic ulcerative tiflocolitis: a case report. *Veterinarni Medicina* 57(8):434–438.

GBERINDYER, F.A. and OMOTOSHO, O.O. (2015): A case of Amitraz poisoning in four adult Alsatian dogs. *International Journal of Livestock Research* 5(9):62-67. doi.10.5455/ijlr.2015091411063.

JORENS, P.G., ZANDIJK, E., BELMANS, L., SCHEPENS, P.J. and BOSSAERT, L.L. (1997): An usual poisoning with the unusual pesticide Amitraz. *Human and Experimental Toxicology* 16(10):600-601.

MARINIS, A., YIALLOUROU, A., SAMANIDES, L., DAFNIOS, N., ANASTASOPOULOS, G., VASSILIOU, I. and THEODOSOPOULOS, T. (2009): Intussusception of the bowel in adults: A review. *World Journal of Gastroenterology* 15(4):407-411.

MARKORWITZ, J., ARCHIBALD, J. and DOWNIE, H.C. (1964): *Experimental Surgery*. 5th Ed. The Williams and Wilkins: Baltimore: 185-192.

ONGOM, P.A. and LUKANDE, R.L. (2013):

Precipitous intussusceptions with anal protrusion and complete overt rectal prolapsed presenting with intestinal obstruction and an associated rectal adenoma: A case report. *BMC Research Notes* 6:401. doi.10.1186/1756-0500-6-401

PARADIS, M. (1999): New approaches to the treatment of canine demodicosis. *Veterinary Clinics of North America: Small Animal Practice* 29:1425.

RADAKOVIC, M., STEVANOVIC, J., DJELIC, N., LAKIC, N., KNEZEVIC-VUKCEVIC, J.,

VUKOVIC-GACIC, B., STANIMIROVIC, Z. (2013): Evaluation of the DNA damaging effects of amitraz on human lymphocytes in the Comet assay. *Journal of Biosciences* 38:53-62. <https://doi.org/10.1007/s12038-012-9287-2>

SNOW, D.H. and WATSON, A.D.J. (1973): The acute toxicity of Dieldrin in the dog: 1. Clinical observations and clinical pathology. *Australian Veterinary Journal* 49(3):113-119.

WALTON J., TAPPIN S. (2017): Red blood cell transfusions – when, what and how to do it! *VETcpd* 4(4):29-38.