



## Ultrasonographic Diagnosis of Simultaneous Pyometra with Gestation in a Bitch: A Diagnostic Challenge

Bappah, M.N.<sup>1\*</sup>; Bada, A.A.<sup>1</sup>; Muhammad, S.T.<sup>2</sup>; Lawal, M.<sup>1</sup>; Mustapha, R.A.<sup>3</sup>; Aminu, G.A.<sup>1</sup>; Muhammad, S.<sup>1</sup>

<sup>1</sup>Department of Veterinary Surgery and Radiology, Ahmadu Bello University, Zaria. <sup>2</sup>Veterinary Teaching Hospital, Ahmadu Bello University, Zaria. <sup>3</sup>Department of Theriogenology, Ahmadu Bello University, Zaria\*Corresponding author: Email: mnbappah.88@yahoo.com; Mobile:+23408184337799

### SUMMARY

A 1-year-old German Shepherd cross-bred bitch was diagnosed with cystic endometrial hyperplasia - pyometra complex and commenced treatment without detection of gestational sacs using ultrasound, until the bitch aborted two stillbirths and one live preterm puppies 12 hours after ultrasonographic examination and 36 hours after commencement of treatment. Gestation should not be ruled out immediately after ultrasonographic diagnosis of pyometra in bitches.

**KEYWORDS:** Cystic endometrial hyperplasia - pyometra complex, Diagnosis, Gestation, Ultrasonography

### INTRODUCTION

Cystic endometrial hyperplasia - pyometra complex (CEH – pyometra complex) is one of the common gynaecological problems in bitches that are usually seen in middle to old age, but it has been reported in a juvenile after the first heat (Porowska *et al.*, 2018). It can be classified as open and closed cervix pyometra (Kumara-Baithalu *et al.*, 2010). Pathogenesis of CEH - pyometra complex is not well understood but it is assumed to be caused by hormonal imbalance in the endometrium combined with bacterial infection (Schlafer and Gifford, 2008). Pyometra is a sequela of cystic endometrial hyperplasia preceded by simple endometrial hyperplasia (Hartzband, 1994).

Open cervix pyometra show signs such as fever, mucopurulent discharge, lethargy, depression, inappetence, polyuria, polydipsia, vomiting and diarrhoea, while bitches with closed cervix pyometra may be very ill and die due to toxemia or peritonitis as a result of uterine rupture (Hagman, 2018). Diagnostic imaging such as ultrasonography and radiography are mostly used modalities to confirm CEH - pyometra complex in bitches (Mattei *et al.*, 2018). Medical treatment can be employed (Fieni *et al.*, 2014) but ovariohysterectomy is considered as the best option (Galadima *et al.*, 2013).

There is a connection between CEH - pyometra complex and pseudo-pregnancy (Gobello *et al.*, 2001; Razzaque *et al.*, 2008), because both are characterized by luteal phase (Gobello *et al.*, 2001). The

aim of this case report is to point out a major challenge associated with ultrasonographic diagnosis of simultaneous CEH - pyometra complex with gestation in bitches.

## CASE REPORT

A 1-year-old 15 kg German Shepherd cross-bred bitch was referred to the Diagnostic Imaging Center of Veterinary Teaching Hospital, Ahmadu Bello University, Zaria for ultrasonographic examination due to suspected pyometra. Referral notes stated that the condition was noticed 2 weeks prior to presentation, and the bitch was previously treated unethically against ticks with 9 mg of Ivermectin tablets (Mectizan™ MSD France, Courbevoie, France) at 3 days interval for 3 weeks. Other clinical information included; smelly mucopurulent vulvar discharges, tenderness at caudal abdomen upon palpation.

Transabdominal ultrasound was performed with 5 MHz curvilinear transducer (Sonostar S10™, Sonostar Technologies Company, Guangzhou, China) to examine the uterus via bladder as acoustic window, that revealed hypoechoic tubular of the right uterine horn with thickened and irregular hyperechoic wall (Plate 1), and CEH - pyometra complex was confirmed.

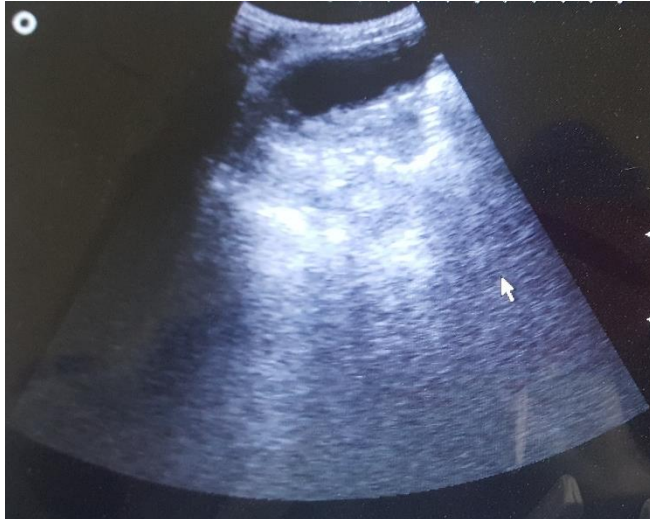
Antibiotic therapy using Enrofloxacin (Floxinor™, Hebei Hope Harmony Pharmaceutical Co. Ltd, Shijiazhuang city, Hebei, China) at 5 mg/kg has already commenced tentatively a day prior to the referral, and after the ultrasonographic examination, the antibiotic therapy was advised to be continued for that day and subsequent 8 days. Abortion of two stillbirths and one live preterm puppies was observed 12 hours post ultrasonographic examination and 36 hours after commencement of antibiotic therapy.

## RESULTS AND DISCUSSION

*Escherichia coli* and *Staphylococcus spp* was isolated from vulvar discharges, and similar findings were also reported in some cases of canine pyometra (Bassessar *et al.*, 2013; Sant'Anna *et al.*, 2014; Hagman, 2018). Leucocytes counts revealed leucocytosis due to neutrophilia, which this could be considered as a usual clinical findings of pyometra (Kumara-Baithalu *et al.*, 2010; Emanuelli *et al.*, 2012).

Cystic endometrial hyperplasia - pyometra complex was suspected following the smelly mucopurulent vulvar discharges, which was confirmed by the isolation of the microbial agents from the discharges, and detection of a hypoechoic tubular of the right uterine horn with thickened and irregular hyperechoic wall during ultrasonographic examination as reported by Barr (2011). Major challenge encountered in this case was the fact that ultrasonographic examination of the uterus was conducted, only CEH – pyometra complex was confirmed but cyesis were not detected. Furthermore, the ultrasonographic image revealed a hypoechoic tubular of the right uterine horn with thickened and irregular hyperechoic wall (Plate 1). To the best of our knowledge, simultaneous pyometra with pregnancy is uncommon. There were only three reported cases of simultaneous pyometra with pregnancy (Orozco *et al.*, 2005; Risso *et al.*, 2014; Sperling *et al.*, 2018). However, two of the reported cases had similar radiological presentation like the present case, but gestational sac which is an evidence of pregnancy during first ultrasonographic examination were not observed. A case reported by Risso *et al.* (2014) detailed that the first ultrasonographic examination revealed small to moderate anechoic fluid in the left uterine horn where pyometra was suspected, but the second ultrasonographic examination after five days treatment with cabergoline and amoxicillin-clavulanate

revealed two gestational sacs in the right uterine horn and anechoic fluid in the left uterine horn. Radiography was used to confirm the two foetuses a week prior to the caesarean section for delivery. Another case reported by Sperling *et al.* (2018) documented that the primary care veterinarian performed the first ultrasonographic examination and was worried by the ultrasonographic



appearance of the uterus concurrent with bloody vaginal discharge, but suspected pregnancy based on presumptive luteinizing hormone (LH) peak at 40 days of gestation. The second ultrasonographic examination revealed a moderate intrauterine fluid in the right uterine horn and a singleton viable puppy in the left uterine horn.

**Plate 1:** Hypoechoic tubular right uterine horn with thickened and irregular hyperechoic wall.

Unfortunately, no documents tried explaining the reason why gestational sac were not able to be detected in the first ultrasonographic examinations and this may pose a strong challenge in the ultrasonographic diagnosis of simultaneous pyometra with gestation in bitches. However, Orozco *et al.* (2005) lamented that the very little knowledge on simultaneous pyometra with gestation in bitches was due to lack of reporting of such condition. It was suggested that in the first reported case, detection of the gestational sacs were possible on the second ultrasonographic examination because of the cabergoline and amoxicillin-clavulanate treatment for 5 days which may have alleviated the pyometra (Corrada *et al.*, 2006). While, the primary care veterinarian in the second reported case confirmed pregnancy through radiography following detection of LH peak but not ultrasonography (Feldman and Nelson, 2004). Such case can be confusing and challenging if only

ultrasonography will be available, considering the association of pyometra with pseudo-pregnancy where LH peak can also be detected (Chakraborty, 1987).

Influence of progesterone promotes morphological and functional changes in the endometrium including excessive activity of the endometrial glands, which can create a favourable scenario for both pyometra and pregnancy to occur (Risso *et al.*, 2014). Though, Orozco *et al.* (2005) stated that the condition is not sparse but lack of publication of such cases makes awareness and knowledge on the reason for simultaneous pyometra with gestation very limited. Orozco *et al.* (2005) and Risso *et al.* (2014) postulated that infection can occur during mating and subsequent production of progesterone favours both hyperplasia of the endometrial glandular structures and gestation to thrive.

In conclusion, the challenge that may be encountered during ultrasonographic diagnosis of simultaneous pyometra with gestation can somehow be abated, if a second ultrasonographic examination few days after medical treatment should be recommended (Risso *et al.*, 2014), or radiography should be combined in the diagnosis of CEH - pyometra complex to rule out gestation (Feldman and Nelson, 2004; Risso *et al.*, 2014) even though the

effects of irradiation of live foetus is quite controversial (Valentin, 2003).

### ACKNOWLEDGMENTS

Authors have recognized the efforts of clinical students especially Abubakar

### REFERENCES

- BARR, F. (2011): BSAVA Manual of
- BASSESSAR, V., VERMA, Y. and SWAMY, M. (2013). Antibiogram of bacterial species isolated from canine pyometra. *Vet. World*, **6**(8): 546.
- EMANUELLI, M.P., MARTINS, D.B., WOLKMER, P., ANTONIAZZI, A.Q., EMANUELLI, T., DE VARGAS, A.C. and DOS ANJOS LOPES, S.T. (2012). Complete blood count, total plasma protein, neutrophil oxidative metabolism, and lipid peroxidation in female dogs with pyometra associated with *Escherichia coli*. *Comp. Clin. Pathol.*, **21**(3): 309-313.
- FIENI, F., TOPLE, E. and GOGRY, A. (2014). Medical treatment of pyometra in dogs. *Reprod. Domest. Anim.*, **49**(suppl 2): 28-32.
- GALADIMA, M., OGWU, D., OGUNKOYA, A.B. and HASSAN, A.Z. (2013). Case Report: An incidence of cystic endometrial hyperplasia - pyometra complex in a Nigerian local breed bitch treated with medroxyprogesterone acetate (MPA) as a contraceptive. *J. Vet. Med. Anim. Health*, **5**(5): 129-132.
- GOBELLO, C., DE LA SOTA, R.L. and GOYA, R.G. (2001). A review of canine pseudocyesis. *Reprod. Domest. Anim.*, **36**(6): 283-288.
- HAGMAN, R. (2018). Pyometra in small animals. *Vet Clin N Am-Small*, **48**(4): 639-661.
- HARTZBAND, L.E. (1994). Case of the
- Abdulrashid, Basirat Idris and Faith Kaka, and appreciated the support of the Veterinary Teaching Hospital, Ahmadu Bello Univerisity, Zaria.
- Canine and Feline Ultrasonography. Replika Press Ltd, India: 172-176.
- day 2 diagnosis: pyometra. *J. Ultrasound Med.*, **13**(4): 330-343.
- KUMARA-BAITHALU, R., MAHARANA, B.R., MISHRA, C., SARANGI, L. and SAMAL, L. (2010). Canine pyometra. *Vet. World*, **3**(7): 340.
- MATTEI, C., FABBI, M. and HANSSON, K. (2018). Radiographic and ultrasomographic findings in a dog with emphysematous pyometra. *Acta Vet. Scand.*, **60**(1): 67.
- OROZCO, P., QUIROZ, H. and GOMEZ, G. (2005). Pyrometer and simultaneous pregnancy in a female dog: a case report. *Rev. Colomb. Cienc. Pecua.*, **18**: 176-181.
- POROWSKA, E., KULUS, M., JANKOWSKI, M., KOCHEROVA, I., JESETA, M., CHAMIER-GLISZCZYŃSKA, A., STEFAŃSKA, K., BOROWIEC, B., BUKOWSKA, D., BRÜSSOW, K.P., KEMPISTY, B. AND ANTOSIK, P. (2018). Selected aspects of endometritis-pyometra complex in dogs-current troubles and treatment perspectives. *Med. J. Cell Biol.*, **6**(3): 108-113.
- RAZZAQUE, W.A., HUSAIN, K., AGARWAL, S. and KUMAR, S. (2008). False pregnancy in bitch. *Vet. World*, **1**(3): 92-95.
- RISSO, A., PELLEGRINO, F.J. and CORRADA, Y. (2014). Simultaneous pyometra and viable puppies' gestation in a bitch. *Open Vet. J.*, **4**(2): 82-84.

- SANT'ANNA, M.C., GIORDANO, L.G.P., FLAIBAN, K.K.M.C., MULLER, E.E., and MARTINS, M.I.M. (2014). Prognostic markers of canine pyometra. *Arq. Bras. Med. Vet. Zootec*, **66**(6): 1711-1717.
- SCHLAFER, D.H. and GIFFORD, A.T. (2008). Cystic endometrial hyperplasia, pseudoplacental endometrial hyperplasia, and other cystic conditions of the canine and feline uterus. *Theriogenology*, **70**(3): 349-358.
- SPERLING, S., MITCHELL, A., CHEONG, S.H. and DIEL DE AMORIM, M. (2018). Singleton pregnancy with concurrent pyometra in the contralateral horn in a bitch with a live puppy outcome. *Reprod. Domest. Anim.*, **53**(6): 1609-1612.
- CORRADA, Y., ARIAS, D., RODRÍGUEZ, R., TORTORA, M. and GOBELLO, C. (2006). Combination dopamine agonist and prostaglandin agonist treatment of cystic endometrial hyperplasia-pyometra complex in the bitch. *Theriogenology*, **66**(6-7): 1557-1559.
- FELDMAN, E.C. and NELSON, R.W. (2004): *Endocrinology and Reproduction in Dogs and Cats*. Saunders, St. Louis, USA: 852.
- CHAKRABORTY, P.K. (1987). Reproductive hormone concentrations during estrus, pregnancy, and pseudopregnancy in the Labrador bitch. *Theriogenology*, **27**(6): 827-840.
- VALENTIN, J. (2003). Biological effects after prenatal irradiation (embryo and fetus). *Annals of ICRP*, **33**: 1-206.