



Hypospadias in a German Shepherd Dog

Muhammad, S. T.^{1*}; Bada, A. A.²; Audu, S. W.³; Lawal, M.². Bappah, M. N.²; Awasum, C. A.²; Mustapha, R. A.⁴; Mohammed, B.⁵; Jahun, B. M.¹. and Suleiman, M. H.⁶

¹Veterinary Teaching Hospital, Ahmadu Bello University, Zaria, Nigeria. ²Department of Veterinary Surgery and Radiology, Ahmadu Bello University, Zaria, Nigeria. ³Department of Veterinary Medicine, Ahmadu Bello University, Zaria, Nigeria. ⁴Department of Theriogenology and Production, Ahmadu Bello University, Zaria, Nigeria. ⁵Department of Veterinary Pathology, Ahmadu Bello University, Zaria, Nigeria. ⁶Department of Veterinary Anatomy, Ahmadu Bello University Zaria, Nigeria; *Corresponding author: Email: tmsaidu@abu.edu.ng; Tel No: +2348135989887.

SUMMARY

A three-year-old, male German Shepherd dog previously (five months ago) managed for anorexia and bleeding from the perineum was re-presented with similar complaints in addition to abnormal gait observed on the day of the presentation. The dog was born with congenital urethral defect and urinates without problem via the defective urethra around the perineum. Physical examination revealed weakness, arched back, scald dermatitis, haematuria, perineal urethral opening, cleft scrotum, hypoplastic penis and prepuce, urinary incontinence, and abdominal tenderness. Transabdominal ultrasound revealed pyelonephritis and contrast cystograph showed evidence of urinary bladder diverticulum. Haematuria, bacteriuria, hyperproteinaemia and leucocytosis were also evident from laboratories. Physiologic saline solution, enrofloxacin and streptomycin sulphate were used to flush the urinary bladder (intracystic instillation) daily for 5 consecutive days. Enrofloxacin injection at 5 mg/kg was administered intramuscularly daily for 1 week and paracetamol injection at 10 mg/kg was administered daily intramuscularly for 5 days. The management was purely that of urinary tract infection as the owner turned down the possibility of surgical intervention. Eventually, the patient responded positively as the presented clinical signs disappeared, became lively and demanding of outdoor activities.

Key words: Hypospadias, cleft scrotum, urinary bladder diverticulum, German shepherd dog

INTRODUCTION

Hypospadias is a congenital urethral opening along the ventrum of the penis, caudal to the supposed normal urethral orifice, resulting from the partial or complete failure of the two urethral folds to fuse to form the extrapelvic urethra and the failure of the median raphe of the perineum,

scrotum, penis and prepuce to develop (Hedlund, 2002; Yamada *et al.*, 2003). The condition is due to incomplete masculinization during development and it can be associated with an underdeveloped penis and/or with preputial malformations (Thomas, 2006). The three clinical

manifestations as described by Vnuk *et al.* (2014) are the penile (urethra opens ventrally caudal to the glans penis and cranial to the scrotum); scrotal (urethra opens at the scrotum or between the halves of a divided scrotum); and perineal (urethra opens on the perineum) hypospadias (Tim, 2009). The urethral orifice appears to resemble a vulva in the perineal form, which can be mistaken for hermaphroditism due to presence of scrotum and penis on such animal. Cleft scrotum may also accompany hypospadias (Tim, 2009). Hypospadias have been reported in small animals (Hayes and Wilson, 1986; King and Johnson, 2000) and ruminants (Rajankutty *et al.*, 1994; Smith *et al.*, 2006).

Treatment of hypospadias can be medical or surgical and depends on the location and severity of the defect (Hedlund, 2002; Adelsberger and Smeak, 2009). Surgery is aimed at correcting the anatomical abnormality to minimize the risks of recurrent urinary tract infections, urethral stricture, urine scald dermatitis, or penile and urethral irritation (Adelsberger and Smeak, 2009).

Case History

A 3-year-old male German shepherd dog weighing 30 kg was presented to

the Veterinary Teaching Hospital of Ahmadu Bello University, Zaria because of sudden anorexia, abnormal gait and bleeding from the perineum observed on the day of the presentation. The dog was born with congenital urethral defect and urinates without problem via the defective urethra around the perineum. The dog was successfully treated for similar clinical condition five months earlier. Upon clinical examination the vital parameters were 39.1 °C for body temperature, 100 beats/min for pulse rate and 21 cycles/min for respiratory rate. Clinical signs observed were weakness and arched back, urine burns (scald dermatitis), haematuric matted perineum and ventral urethral opening at the perineum (Plate I), cleft scrotum, hypoplastic penis and prepuce (Plate II), urinary incontinence, and tenderness of the caudal abdomen.

Laboratory investigation

A number of investigations involving ultrasonographic and radiographic examinations, urinalysis, routine faecal examination, and complete blood cell count were conducted to ascertain the problem of the dog. The results of the investigations were: transabdominal ultrasonographic scan

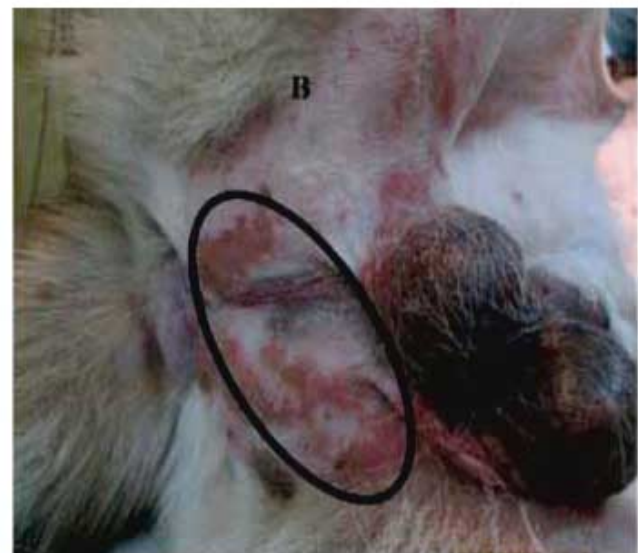
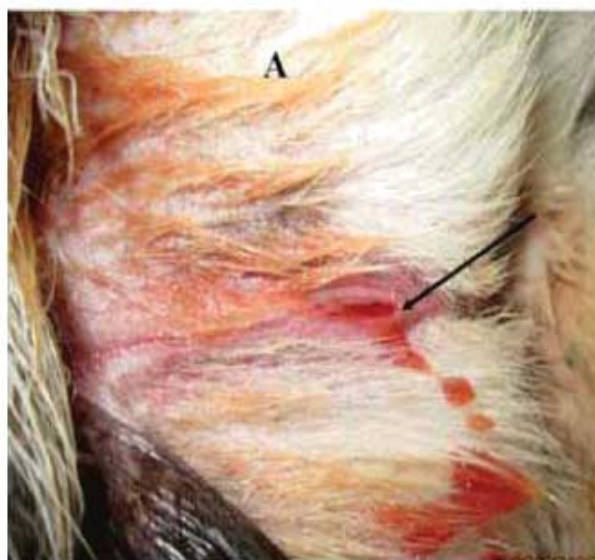
Plate I: A, Matted perineum with blood through the ventral urethral opening at the perineum (arrowed) and B, scald dermatitis (circled)

revealed pyelonephritis. ventro-dorsal and lateral contrast radiographs (retrograde cystography) revealed evidence of urinary bladder diverticulum at the ventral aspect (Plate III). Urinalysis result yielded specific gravity of 1.030 and pH of 8.0, proteinuria, haematuria and bacteriuria (*Corynebacterium*spp and α -haemolytic *Staphylococcus*spp) with antibiogram of Ciprofloxacin +, Streptomycin ++ and Gentamycin +++. Helminthology result revealed no evidence of parasite. Clinical pathology results revealed hyperproteinaemia and leucocytosis due to neutrophilia (Table 1).

Case Management

Five hundred milliliter solution containing 480 ml of normal physiologic saline, 10 ml of 5 % enrofloxacin and 10 ml of streptomycin sulphate (5 g) was used to flush the catheterized urinary bladder (intracystic instillation) through the ventral urethral opening at the perineum over a period of 30 minutes. The solution was allowed to stay in the bladder for 30 minutes before it was evacuated through the same route of instillation (Plate IV). This procedure was repeated for 5 consecutive days. Enrofloxacin injection at 5mg/kg was administered intramuscularly daily for

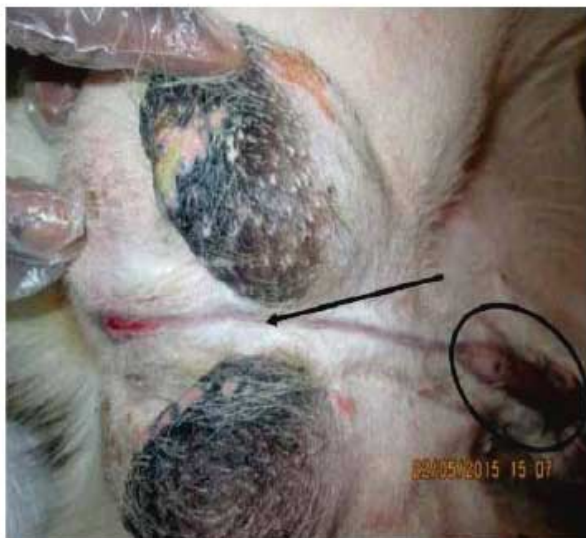

Plate II: Cleft scrotum (arrowed), hypoplastic penis and prepuce (circled)

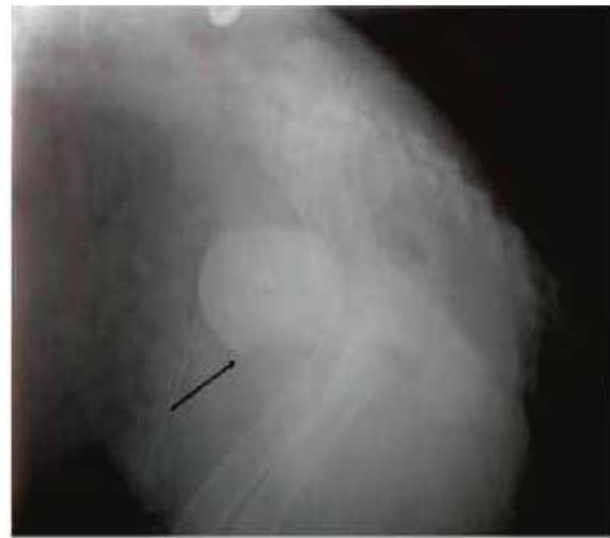


Plate III:Lateral contrast radiograph showing evidence of urinary bladder diverticulum (arrowed) at the ventral aspect

Table 1: Haematology results

Parameters	Patient's values	Reference values #
HB(g/dl)	12.7	12-18
PCV (%)	38	37-55
WBC ($\times 10^9/L$)	18.40	6.0-17.0
Neutrophils ($\times 10^9/L$)	14.72 (80)*	3.6-13.1(60-77)*
Lymphocytes($\times 10^9/L$)	2.76 (15)*	0.72-5.1(12-30)*
Monocytes($\times 10^9/L$)	0.00 (0)*	0.18-1.7(3-10)*
Eosinophils($\times 10^9/L$)	0.92 (5)*	0.12-1.7(2-10)*
Basophils($\times 10^9/L$)	-	Rare
Total Protein(g/dL)	8.2	5.4-7.7

*Relative differential leukocyte counts in parenthesis

#Source: Sastry, 1983

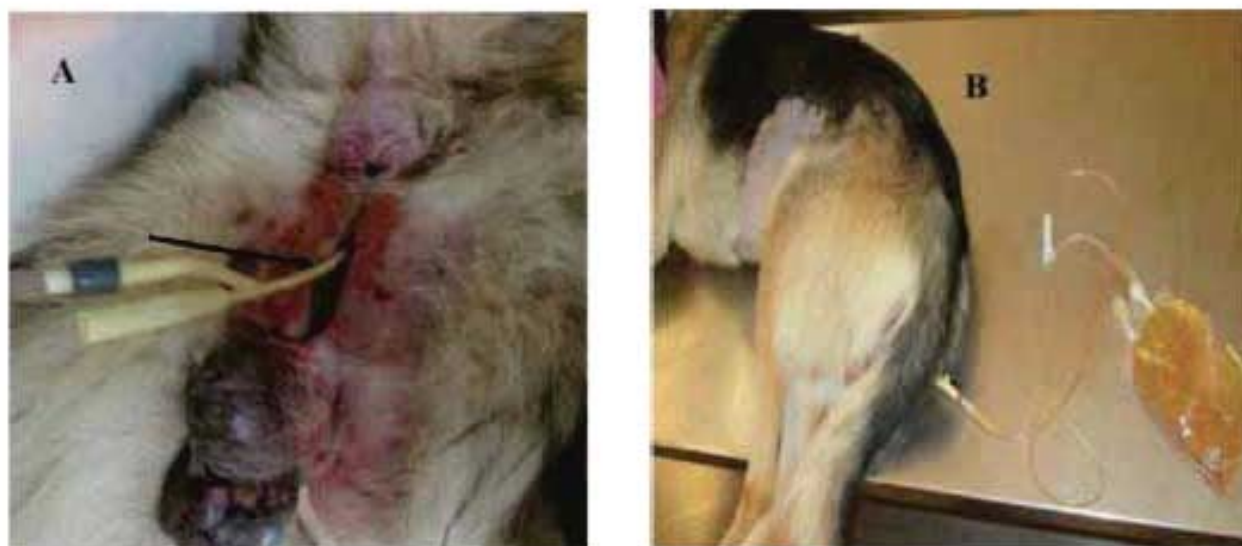

Plate IV: A, Transurethral catheterization through the ventral urethral opening at the perineum (arrowed) for antibiotic/antiseptic instillation and B, flushing/evacuation procedure

1 week; paracetamol injection at 10mg/kg was administered daily intramuscularly for 5 days. As the owner turned down surgical intervention of the condition despite history of recurrent urinary tract infection, urine scald dermatitis, and misdirection of the urine stream, the management ended at treating only the urinary tract infection. There was clear evidence of gradual improvement during the course of the management due to disappearance of the observed clinical signs. Eventually, the patient regained its strength and relatively became more active.

DISCUSSION

Hypospadias is an uncommon developmental defect though, most often seen in dogs, resulting from the failure of fusion of urogenital folds during foetal development, causing incomplete closure of the penile urethra (Kluft *et al.*, 1988; Boothe, 2003; Thomas, 2006). Clinical signs associated with hypospadias include urine scald dermatitis, misdirection of urine stream, pollakiuria, stranguria, and penile tissue irritation (Hedlund, 2002). The exact cause of this defect is not known but is believed to be hormonal and/or genetic in

origin, as explained by several hypotheses in the human and animal studies (Baskin, 2000; Hardy and Kustritz, 2005). The hormonal factor is related to abnormalities of androgen metabolism and timing of its receptor function during early embryonic period of male sexual differentiation (Uda *et al.*, 2004). In canine species, exposure of the male foetus to progesterone or anti-androgens during gestation, particularly between day 30 and day 44 of pregnancy, may be responsible (Boothe, 2003) for the defect. This is because the affected foetus may secrete inadequate quantities of testosterone or there may be inadequate conversion of testosterone to dihydrotestosterone in the target tissues of the urogenital sinus and external genitalia, thereby disrupting the fusion of the urogenital folds at different sites along the urogenital tract (Meyers-Wallen and Patterson, 1986; Jason, 2005). The condition can range from mild hypospadia, in which the urinary orifice is located in the glans penis to severe hypospadias where the orifice is at the peno-scrotal junction, scrotum, or the perineum (Meyers-Wallen and Patterson, 1986; Hobson, 1998). Failure

of ventral midline fusion of the prepuce (underdeveloped prepuce) and/or scrotum, the penis may be hypoplastic and non-functional in the patients as well (Hedlund, 2002; Hardy and Kustritz, 2005), similar to this reported case. Affected animals may also have other urogenital anomalies like cryptorchidism, hermaphroditism or pseudohermaphroditism and renal aplasia (McFarland *et al.*, 1961; Hardy and Kustritz, 2005). However, the dog in this report had no evidence of these associated conditions based on physical and radiological evaluations, although there was evidence of urinary bladder diverticulum, believed to be congenital. Other hypotheses include the lack of urethral fusion due to the failure of epithelial to mesenchymal transformation of the urethra (Baskin, 2000). Endocrine disrupters, such as estrogenic contaminants in the environment may be responsible for this malformation (Baskin, 2000). The genetic predisposition that have been suggested to be a contributing factor is seen in Boston terriers to have a disproportionately higher prevalence of hypospadias (Ader and Hobson, 1978; Hayes and Wilson, 1986). Bacteriuria observed in this case may probably be attributable to the close proximity of the

urethral meatus to the anus as well as the shorter length of the urethra paving way for ascending bacterial infections (Delisser, *et al.*, 2012), leading to bacterial cystitis with subsequent pyelonephritis characterised by anorexia, arched back, caudal abdominal tenderness, haematuria, proteinuria, and leucocytosis due to neutrophilia. The hyperproteinaemia notice could be as a result of dehydration as supported by the urine specific gravity and pH, and normal PCV (despite gross haematuria).

The surgical treatment for this type of hypospadias was designed and planned by the authors to eliminate the source of inflammation and irritation from the exposed urethra, to help focus the urine stream to reduce urine scald and increase the length of the urethra (move the urethral meatus well away from the anus). However, it was not undertaken due to owner's refusal to accept the surgical option.

ACKNOWLEDGEMENT

The authors are grateful to Prof. S. U Abdullahi of the Department of Veterinary Medicine, Ahmadu Bello University, Zaria, Nigeria and Prof. D. A. Y. Adawa of the Veterinary Teaching Hospital, Ahmadu Bello University, Zaria, Nigeria for their kind assistance.

REFERENCES

- ADELSBERGER, M. E. and SMEAK, D. D. (2009): Repair of extensive perineal hypospadias in a Boston terrier using tubularized incised plate urethroplasty. *Canadian Veterinary Journal*, 50:937-942.
- ADER, P. L. and HOBSON, H. P. (1978): Hypospadias: A review of the veterinary literature and a report of three cases in the dog. *Journal of American Animal Hospitals Association*. 14: 721-727.
- BASKIN, L. S. (2000): Hypospadias and urethral development. *Journal of Urology*, 163: 951-956.
- BOOTHE, H. W. (2003): Penis, prepuce, and scrotum. In: Slatter D, ed. *Textbook of Small Animal Surgery*. 3rd ed. Philadelphia: WB Saunders. Pp. 1535-1536; 1640-1641.
- DELISSER, P. J., FRIEND, E. J., CHANOIT, G. P. and PARSONS, K. J. (2012): Static hydraulic urethral sphincter for treatment of urethral sphincter mechanism incompetence in 11 dogs. *Journal of Small Animal Practice*, 53(6):338-343.

- HARDY, R. M. and KUSTRITZ, M. V. (2005): Theriogenology question of the month. Hypospadias. *Journal of American Veterinary Medical Association*, 227:887-888.
- HAYES, H. M. and WILSON, G. P. (1986): Hospital incidence of hypospadias in dogs in North America. *Veterinary Record*, 118:605-607.
- HEDLUND, C. S. (2002): Surgery of the male reproductive tract. In: *Small Animal Surgery*. 2nd Ed. Fossum, T. W. Hedlund, C. S. Johnson, A. L. Seim, H. B. Willard, M. D. and Carroll, G. eds. St. Louis: Mosby, Publishers. Pp. 662- 665.
- HOBSON, H.P. (1998): Surgical procedures of the penis. In: *Current Techniques in Small Animal Surgery*, Fourth edition. Edited by M.J. Bojrab, G.W. Ellison and B. Slocum. Baltimore: Williams and Wilkins. pp527-534.
- JASON, N. (2005): A case of hypospadias in a dog. *Irish Veterinary Journal*, 58 (9): 504-506.
- KING, G. J. and JOHNSON, E. H. (2000): *Journal of Small Animal Practice*, 41:508.
- KLUTH, D., LAMBRECHT, W. and REICH, P. (1988): Pathogenesis of hypospadias – More questions than answers. *Journal of Pediatric Surgery*, 23, 1095–1101.
- MCFARLAND, L. Z. and DENIZ, E. (1961): Unilateral renal agenesis with ipsilateral cryptorchidism and perineal hypospadias in a dog. *Journal of American Veterinary Medical Association*, 139:1099-1100.
- RAJANKUTTY, K., BALAGOPALAN, T. P., AMMA, T. S. and VERKEY, C. A. (1994): *Journal of Veterinary Animal Science*, 25:172.
- MEYERS-WALLEN, V. N. and PATTERSON, D. F. (1986): Disorders of sexual development in the dog. In: *Current Therapy in Theriogenology*. Second edition. Edited by D.A. Morrow. Philadelphia: Saunders. pp567– 573.
- SASTRY, G. A. (1983): *Veterinary Clinical Pathology*, 6th edition. CBS Publishers and Distributors, Delhi, Pp 4-35.
- SMITH, K. C., BROWN, P. and PARKINSON, T. J. (2006): Hypospadias in rams. *Veterinary Record*, 158:789-795 doi:10.1136/vr.158.23.789.
- THOMAS, K. G. (2006): Diseases of the penis and Prepuce. In: *Saunders manual of small animal practice Third Edition*. Stephen J. Birchard, Robert G. Sherding (ed). Pp.973-977
- TIM, P. (2009): Fertility, subfertility and infertility in male animals. In: *Veterinary Reproduction and Obstetrics* (9th edition). Saunders Publishers. Pp. 70-727.
- UDA, A., KOJIMA, Y., HAYASHI, Y., MIZUNO, K., ASAI, N. and KOHRI, K. (2004): Morphological features of external genitalia in hypospadiac rat model: 3-dimensional analysis. *Journal of Urology*, 171, 1362–1366.
- VNUK, D., BOTTEGARRO, N. B., Slunjski, L., Skrlin, B., Musulin, A. and Stejskal, M. (2014): Prepubic urethrostomy opening within a prepuce in a dog: a case report. *Veterinarni Medicina*, 59, (2): 107–111
- YAMADA, G., SATOH, Y., BASKIN, L. S. and CUNHA, G. R. (2003): *Research in Biology Diversion*, 71: 445.