



## Tomato Consumption Protected Against Gamma Radiation-Induced Alterations in the Hippocampus and Cerebellum of Rats.

OWOEYE, O.<sup>1</sup> and ELUMELU, T.N.<sup>2</sup>

<sup>1</sup>Department of Anatomy, College of Medicine, University of Ibadan, Ibadan, Nigeria, <sup>2</sup>Department of Radiotherapy, College of Medicine, University of Ibadan, Ibadan, Nigeria.\*Corresponding Author:E-mail: [o.owoeye@mail.ui.edu.ng](mailto:o.owoeye@mail.ui.edu.ng), [owoeye2001@yahoo.com](mailto:owoeye2001@yahoo.com), Tel: +234-8033239973

### SUMMARY

Cancer causes great morbidity and mortality. Radiotherapy, one of the treatment modalities is associated with neurotoxicity; and oxidative damage has been reported to play an important role in the pathogenesis. Tomatopomace powder (TPP) may be a preventive agent by virtue of its known antioxidant property. The present study was carried out to investigate the possible protective role of TPP against radiation-induced alteration of the microanatomy of rat brain.

Thirty rats were divided equally into five groups of six each: control; propylene glycol, TPP, gamma radiation (5 Gy); gamma radiation (5 Gy) plus TPP 50 mg/kg. All administration was oral by gastric gavage given for 24 days except radiation which was administered as a single dose on day 25. Behavioural tests were conducted on the 26<sup>th</sup> day after which rats were euthanized. Blood parameters and brain tissue were examined with regard to micro-anatomical parameters. Data were analyzed using ANOVA with statistical significance set at  $p < 0.05$ .

Gamma radiation induced a significant ( $p < 0.05$ ) reduction in lymphocytes but an increase in eosinophils.

Neurobehavioural results showed that radiation caused a reduction in line crossing, rearing and forelimb grip. Microscopically, radiation induced histological alterations in the cerebellum, dentate gyrus and cornu ammonis 3. Co-treatment of radiation with TPP reduced the effect of radiation on the histological, haematological and, neurobehavioural alterations.

In conclusion, *Lycopersicon esculentum* as tomato pomace powder demonstrated neuroprotective effects against radiation-induced haematological, neurobehavioural alterations as well as alteration of microanatomy of rat cerebellum, dentate gyrus and cornu ammonis 3 of rat brain.

**Key words:** Gamma radiation, *Lycopersicon esculentum*, neuroprotection, cerebellum, hippocampus.

## INTRODUCTION

Cancer causes great morbidity and mortality and is therefore a major public health problem in many parts of the world (Siegal *et al.*, 2014). The projected cancer deaths in United States of America for the year 2014 was 585,720 people, out of the projected 1,665,540 new cancer cases for the same period (Siegal *et al.*, 2014). Radiotherapy is one of the main treatment regimens for cancer and it uses high-energy rays to kill cancer cells; thus preventing further cell division. It is used extensively to treat primary brain tumors, metastases, and prevent intracranial relapse in many malignancies (Wu *et al.*, 2012). During radiotherapy, ionizing radiation interacts with biological systems to induce excessive reactive oxygen species (ROS) which may be free radicals or non-radicals. ROS present a paradox in their biological functions: on one hand, they prevent disease by assisting the immune system, on the other hand, they damage biologically active molecules, leading to tissue damage and cell death (Adaramoye, 2010). Side effects may occur after radiation therapy largely due to radiation's non-discrimination between cancer and normal tissue adjacent to the cancer tissue (Malomo *et al.*, 2005; Owoeye *et al.*, 2010). Although ROS negatively affects intracellular concentrations of antioxidants, augmentation with exogenous antioxidants may reduce the effects of oxidative stress (Gracy *et al.*, 1999)

Protection for normal tissue adjacent to the target cancer cells during radiotherapy is as important as the destruction of the cancer cells, therefore methods that achieve radioprotection are beneficial during radio-therapeutic procedures. Naturally occurring and synthetic antioxidants reduce the toxicity associated with radiation by mopping up the excess free radicals (Maharwal *et al.*, 2005; Farombi and Owoeye, 2011). Antioxidant activities reported in some plants have been studied for their radio-protective properties, including: *Hibiscus sabdariffa* (Adaramoye *et al.*, 2008), *Vernonia amygdalina*, (Owoeye *et al.*, 2010), and

*Garcinia kola* (Adaramoye, 2010). Tomato (*Lycopersicon esculentum* Mill) is a source of antioxidant noted to be among reported plants that synthesize metal chelating proteins, peptides and phytochemicals (Wattanathorn *et al.*, 2012; Khalaf *et al.*, 2014). Antioxidant nutrients in the tomato fruit include carotenoids such as lycopene,  $\beta$ -carotene, phytofluene, vitamin C and vitamin E (Kanabur and Reddy, 2014). Tomatopomace powder (TPP) made from tomato has been beneficial in protecting against experimental stroke (Wattanathorn *et al.*, 2012).

The cerebellum regulates motor coordination, equilibrium, both saccadic and smooth eye movements and maintains muscle tone (Affi and Bergman, 2005), while the cerebral cortex and hippocampus are responsible for regulating cognition, primary sensory functions and memory storage respectively (Snell, 2006). Radiation injury of these neural components may adversely alter the anatomy and physiology of affected parts.

Literature is scanty concerning the effect of tomato on radiation-induced alteration of the microanatomy of the rats' brain hence this study is to investigate a possible protective role of tomato pomace powder, by utilizing its known antioxidant property. This study aimed to therefore seeks to answer the question: 'Can *Lycopersicon esculentum* as tomato pomace powder treatment have any protective role on radiation-induced neuropathy in rats?'

## MATERIAL and METHODS

### *Experimental animals*

This study was carried out using thirty male Wistar rats with initial weights of 77-94 kg, which were housed in the Animal House, of the Department of Veterinary Physiology, Biochemistry and Pharmacology, University of Ibadan, Nigeria. They were acclimatized to laboratory room conditions (12 hours dark – light periods) for a week before the onset of experiment. The rats were fed with rat chow

from Ladokun Feeds®, Ibadan, Nigeria and water *ad libitum*. The experimental protocols were carried out according to the approval and guidelines given by the University of Ibadan Ethical Committee which also conformed to the acceptable guidelines on the ethical use of animals in research (Public Health Service, 1996).

#### **Tomato Pomace Powder (TPP) Preparation and Administration**

Fresh tomato fruits (*Lycopersicon esculentum*) were purchased from Bodija market, Ibadan, Nigeria. TPP was prepared according to the published method of Wattanathorn *et al.* (2012). Briefly, the fresh tomatoes were washed, cut into small pieces, and the tomato juice was then extracted to retain the skin, pulp and seeds which were then dried in an oven at 50°C for 2 hours. Dried parts were weighed and grinded in a blender and the resulting powder termed *Tomato Pomace Powder (TPP)* was kept

in a clean airtight plastic container at room temperature. The administration of TPP was performed by using propylene glycol as vehicle.

#### **Chemicals**

Propylene glycol was obtained from Guangdong Guanghua Science Tech. Co Ltd. (China). Ketamine was manufactured by RotexMedica, Trittau, Germany. All other reagents were of analytical grade and were obtained from the British Drug Houses (Poole, Dorset, UK).

**Experimental design:** After the period of acclimatization, the rats were randomized into 5 groups of 6 each as shown in **Table I**. The dose of Gamma radiation using cobalt-60 was based on the method of Adaramoye (2010), while TPP's dose was based on the method of Wattanathorn *et al.* (2012) who gave 50 mg/kg body weight of rats.

**TABLE I: ANIMAL GROUPING AND TREATMENT DESIGN.**

Grouping	Treatment
Group I	Control, received rat chow and water daily.
Group II	Propylene glycol (PG), received 0.2 mL daily for 24 days.
Group III	TPP received a daily treatment of TPP dose of 50 mg/kg bwt for 24 days.
Group IV	Rad, 5 G of cobalt-60 as a single dose on experimental Day 25.
Group V	TPP+Rad, Rad, 5 G of cobalt -60 as a single dose on experimental Day 25 + TPP 50 mg/kg for 24 days.

PG: - propylene glycol; TPP: - tomato pomace powder; Rad: - radiation; bwt: -body weight.

#### **Irradiation procedures**

Dosimetry and irradiation procedures were carried out at the Radiotherapy Department of the University College Hospital, University of Ibadan, Nigeria. Irradiation procedure was done as described by Owoeye *et al.*, (2011). Briefly, on experimental day 25, rats in groups IV and V were weighed and given Ketamine hydrochloride injection at 10 mg/kg body weight and Diazepam injection at 3 mg/kg body weight intra-peritoneally (i.p). Rats were restrained by strapping in a prone position

within well-ventilated cardboard boxes using cotton strapping. A batch of five animals was irradiated (whole body) at a time with a single fraction of 5Gy of gamma rays obtained from a Bhabhatron II Telecobalt Unit with energy of 1.25 MeV, delivered at a dose rate of 212.561cGy/min for 2.35 minutes and a depth of 8 cm. With a field size of 18 cm by 18 cm, the percentage depth dose was 100%. Rats were thereafter placed in their cages and transferred to the animal house for recovery from anaesthesia, and after recovery were given

chow and water *ad libitum*.

### **Neurobehavioural tests**

The neurological tests done were: (1) forelimb grip test, (2) negative geotaxis, and (3) open field test. After weighing the rats, the tests were performed on the 26<sup>th</sup> day of the experiment so as to investigate the effects of radiation toxicity on the rat nervous system.

#### **Forelimb grip test**

This test was performed according to a modification of the method of VanWijk *et al.* (2008). Each rat was suspended with both forepaws on a horizontal steel wire (1 meter long, diameter 7 mm). The animal was held in a vertical position when its front paws were placed in contact with the wire. When the rat grasped the wire, it was released, and the latency to fall was recorded with a stopwatch. Rats were randomly tested and each animal was given two trials with a 30 min inter trial rest interval. This test assessed muscle strength and balance.

#### **Negative geotaxis**

Negative geotaxis was tested by placing rats head-down on an inclined plane and then watched the rat orient in a head-up direction (Kreider and Blumberg, 1999) The time it took for the rat to orient in a head-up direction was recorded with a stopwatch. The average of two trials was obtained.

#### **Open field test**

The apparatus used was a slight modification of the method of Mohammad *et al.*, (2010). It consisted of a square arena (56×56×20 cm) made of white wood and its floor divided by lines into 16 squares that allowed the definition of central and peripheral parts. At the beginning of the session, each rat was individually placed in the center of the arena and its activity was recorded for 5 min. The number of squares crossed with all paws (crossing) and standing on legs (rearing) were evaluated during 5 minute sessions. The crossing numbers were indicators of locomotor while the rearing numbers indicated vertical and exploratory activities. At the end of each session, rats were

removed from the open field and the experimental chamber was thoroughly cleaned with a damp cloth and dried.

### **Sample collection and histological preparation**

On day 26 of the experiment, all animals in both control and experimental groups were weighed, euthanized by ketamine (100 mg/kg) i.p. followed by cervical dislocation. Blood was collected via the retro-orbital venous sinus into heparinized bottles for haematological parameters. Each rat was decapitated at the cervico-medullary junction for uniformity and the skulls opened after which the brains were quickly extracted. The cerebellum and cerebral cortex of each animal were dissected, preserved in 10% formalin and processed for histology by paraffin embedment technique.

#### **Histology**

The cerebellum from each group was obtained and homologous sampling was assured by obtaining transverse sections of the right cerebellum from each specimen from the lateral zone portions of the cerebella hemisphere (vermal, paravermal and floculus portions were excluded) for uniformity. Coronal sections of the right half of each brain were made to obtain samples of the cerebral cortex and hippocampal tissue. The tissues were sectioned at 5-6 µm thickness and then stained with Haematoxylin and Eosin according to the method of Bancroft and Gamble(2008). Following mounting and staining, slides were examined on an Olympus CH (Japan) light microscope and photomicrographs acquired with a Sony DSC-W 3 digital camera (Japan).

#### **Determination of haematological values**

K2 EDTA-added whole blood samples were used for hematological analyses immediately after collection with the aid of Sysmex Automated Hematology (KX-21, Kobe, Japan) Analyzer. The haematocrit or packed cell volume (PCV), haemoglobin (Hb), red blood cell count (RBC), mean cell volume (MCV), mean cell haemoglobin (MCH), and mean cell haemoglobin concentration (MCHC) and white

blood cell count (WBC), were obtained.

#### **Statistical analysis**

All data were expressed as means  $\pm$  standard deviation. Data were analysed using one-way analysis of variance (ANOVA) using GraphPad Prism TM 4.0 version software, San Diego, CA, USA. Post hoc comparisons were performed

after ANOVA using Dunnett's test. Statistical significance was set at  $p < 0.05$ .

#### **RESULTS**

The body weights of animals were not significantly affected by either radiation or TPP

**TABLE II: WEIGHT CHANGES IN RADIATION AND TOMATO POMACE POWDER-TREATED MALE WISTAR RATS.**

Groups	Initial Weight (g)	Final Weight (g)	Weight Gain (g)	Brain Weight (g)	Relative brain Weight (%)
Control	...	132.00 $\pm$ 11.51	45.50 $\pm$ 8.509	1.50 $\pm$ 0.05	1.14 $\pm$ 0.05
PG	94.17 $\pm$ 13.57	130.83 $\pm$ 18.00	35.66 $\pm$ 8.17	1.60 $\pm$ 0.07	1.23 $\pm$ 0.11
TPP	77.50 $\pm$ 10.84	115.00 $\pm$ 14.29	37.50 $\pm$ 6.83	1.50 $\pm$ 0.09	1.30 $\pm$ 0.55
Rad	91.67 $\pm$ 9.83	128.75 $\pm$ 11.09	37.08 $\pm$ 2.50	1.48 $\pm$ 0.25	1.15 $\pm$ 0.17
TPP+Rad	83.33 $\pm$ 15.83	124.00 $\pm$ 19.23	40.67 $\pm$ 11.73	1.63 $\pm$ 0.09	1.31 $\pm$ 0.14

Data are expressed as mean  $\pm$  standard deviation. PG: - propylene glycol; TPP: - tomato pomace powder; Rad: - radiation.

#### **Haematological parameters**

Table III summarizes the effect of radiation and tomato pomace powder on erythrocyte indices of male Wistar rats. The slight alterations elicited by radiation and TPP either singly or in combination on the packed cell volume (PCV), haemoglobin

level (Hgb), total red blood cell count (RBC), mean corpuscular volume (MCV), and mean corpuscular haemoglobin concentration (MCHC) of the rats were not statistically significant. However, radiation was noted to significantly

**TABLE III: EFFECT OF RADIATION AND TOMATO POMACE POWDER ON ERYTHROCYTE INDICES OF MALE WISTAR RATS.**

Groups	PCV (%)	Hgb (g/dL)	RBC ( $\times 10^6/\mu\text{L}$ )	MCV (fL)	MCHC (g/dL)
Control	45.00 $\pm$ 4.10	15.23 $\pm$ 1.53	7.25 $\pm$ 0.09	60.00 $\pm$ 1.41	33.02 $\pm$ 0.27
PG	44.00 $\pm$ 3.2	15.25 $\pm$ 1.55	7.00 $\pm$ 0.62	60 $\pm$ 2.08	34.00 $\pm$ 0.35
TPP	44.50 $\pm$ 4.23	14.45 $\pm$ 2.02	7.52 $\pm$ 1.65	58.40 $\pm$ 2.12	33.00 $\pm$ 0.00
Rad	42.5 $\pm$ 0.71	13.23 $\pm$ 1	7.15 $\pm$ 0.1	60.00 $\pm$ 1.73	32.67 $\pm$ 0.45
TPP+Rad	40.1 $\pm$ 8.48	14.55 $\pm$ 1.44	8.16 $\pm$ 0.89	59.67 $\pm$ 2.89	32.67 $\pm$ 0.58

Data are expressed as mean  $\pm$  standard deviation. PG: - propylene glycol; TPP: - tomato pomace powder; Rad: - radiation..

**TABLE IV: EFFECT OF RADIATION AND TOMATO POMACE POWDER ON THE LEUKOCYTE INDICES OF MALE WISTAR RATS.**

Groups	WBC ( $\times 10^3/\mu\text{L}$ )	Lymphocytes ( $\times 10^3/\mu\text{L}$ )	Neutrophils ( $\times 10^3/\mu\text{L}$ )	Monocytes ( $\times 10^3/\mu\text{L}$ )	Eosinophils ( $\times 10^3/\mu\text{L}$ )
Control	5.63 $\pm$ 1.47.	2.12 $\pm$ 0.28	4.0 $\pm$ 0.70	1.58 $\pm$ 0.30	0.00 $\pm$ 0.00
PG	5.34 $\pm$ 1.51	2.75 $\pm$ 0.91	2.25 $\pm$ 0.74	1.52 $\pm$ 0.12	1.0 $\pm$ 0.02
TPP	4.14 $\pm$ 0.87	2.3 $\pm$ 0.45	3.12 $\pm$ 1.84	2.13 $\pm$ 0.1	1.01 $\pm$ 0.02
Rad	3.23 $\pm$ 0.58*	1.35 $\pm$ 0.20	1.047 $\pm$ 0.5*	1.22 $\pm$ 0.2	0.0 $\pm$ 0.0
TPP+Rad	5.95 $\pm$ 0.82**	2.48 $\pm$ 0.71	5.80 $\pm$ 1.02**	1.44 $\pm$ 0.13	0.0 $\pm$ 0.0

Data are expressed as mean  $\pm$  standard deviation. PG: - propylene glycol; TPP: - tomato pomace powder; Rad: - radiation. \* P<0.05 versus Control group; \*\* P<0.05 versus radiation group.

**TABLE V: EFFECT OF RADIATION AND TOMATO POMACE POWDER ON BEHAVIOURAL AND LOCOMOTOR ACTIVITIES OF MALE WISTAR RATS.**

Groups	Centre square	Line Crossing	Rearing	Forelimb grip(s)	Geotaxis (s)
Control	3.20 $\pm$ 2.2	42.20 $\pm$ 5.23	16.00 $\pm$ 4.321	6.11 $\pm$ 2.02	1.50 $\pm$ 0.51
PG	1.8 $\pm$ 1.6	22.77 $\pm$ 4.26	12.25 $\pm$ 2.53	4.80 $\pm$ 1.65	2.30 $\pm$ 1.01
TPP	3.5 $\pm$ 2.89	24.82 $\pm$ 4.27	8.33 $\pm$ 1.33	4.83 $\pm$ 0.95	2.47 $\pm$ 1.33
Rad	2.33 $\pm$ 1.52	18.55 $\pm$ 2.47*	7.67 $\pm$ 1.53*	2.1 $\pm$ 1*	1.43 $\pm$ 0.51
TPP+Rad	3.00 $\pm$ 2.92	38 $\pm$ 3.91**	13.67 $\pm$ 2.52**	7.33 $\pm$ 3.05**	2.20 $\pm$ 0.45

Data are expressed as mean  $\pm$  standard deviation. PG: - propylene glycol; TPP: - tomato pomace powder; Rad: - radiation. \* P<0.05 versus Control group; \*\*P<0.05 versus radiation group

### ***Behavioural parameters***

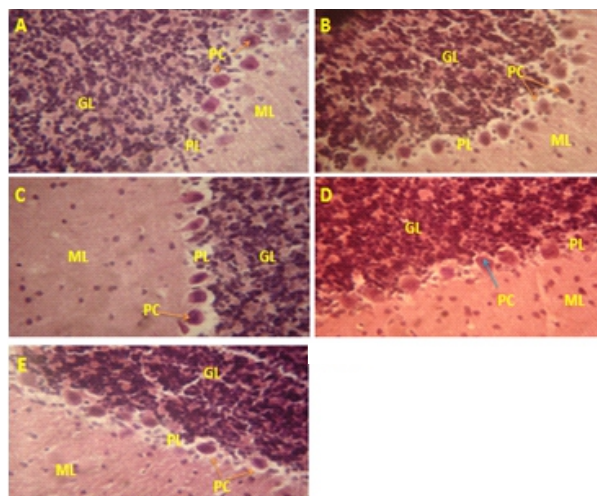
The behavioural tests conducted as shown in **Table V** summarizes the effect of radiation and tomato pomace powder on the behavioural and locomotor activities of male Wistar rats. The number of lines crossed, rearing, and forelimb grip was significantly reduced ( $p<0.05$ ) by radiation. There was however, significant increases in the TPP+Rad group compared with the radiation only group for all these parameters ( $p<0.05$ ).

### ***Histological parameters***

#### **Cerebellum**

The normal histological layers of an adult rat cerebellum namely: granular, molecular, and

Purkinje were observed in **Figs 1A, 1B, and 1C**. The Purkinje cells of the cerebellum of the irradiated rats are noted to be eosinophilic (**Fig 1D**) when compared with the control and the other groups. In **Fig 1E**, the basophilic staining of the Purkinje cells are noted compared with the irradiated group of **Fig 1D**.



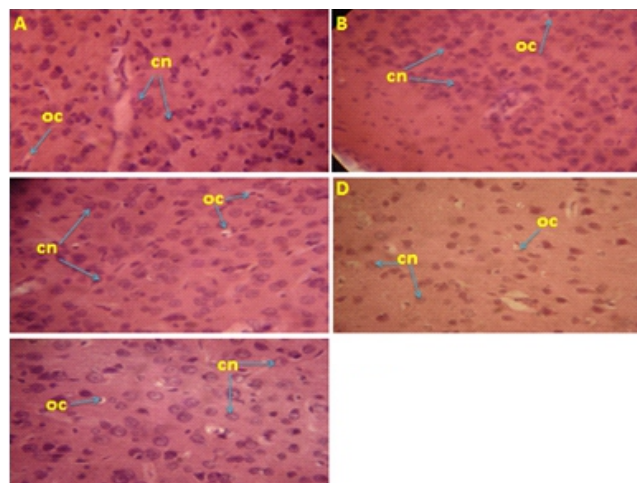
**Fig 1: Representative stained sections of cerebellum of rats:** (a) control rats, (b) PG-treated, (c) TTP-treated, (d) Rad-treated cerebellum with the Purkinje neurons exhibiting eosinophilia, and (e) Rad+TPP-treated. PG, propylene glycol; TTP, tomato pomace powder; Rad, radiation; ML - molecular layer; GL - granular layer; Pc - Purkinje cells. H&E. x960.

### Cerebral cortex

The cerebral cortex of the rats showed the normal histological features with the cortical neurons showing round or ovoid nuclei exhibiting dispersed chromatin as shown in all the groups. This was evident in **Figs 2A, 2B, 2C, 2D,** and **2E**.

### Cornuammonis 3 (CA3)

The CA3 subfield of the hippocampal formation of the control rats showed portions of the normal histological features of the stratum oriens, pyramidal cell layer and stratum radiatum, all of which show normal cytoarchitecture as shown in **Figs 3A, 3B,** and **3C**. In **Fig 3D**, radiation toxicity on the pyramidal neurons was exhibited by neuronal degeneration (arrow-heads). **Fig 3E** shows the effect of co-treatment of TPP with radiation, the pyramidal neurons are noted to be similar to the

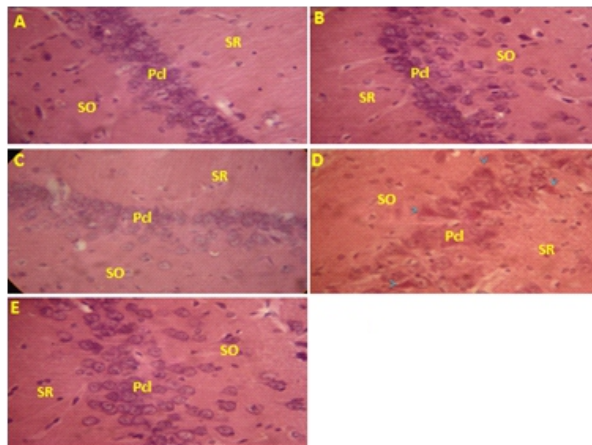


**Fig 2: Representative stained sections of cerebral cortex of rats:** (a) control rats, (b) PG-treated, (c) TTP-treated, (d) Rad-treated and (e) Rad+TPP-treated. PG, propylene glycol; TTP, tomato pomace powder; Rad, radiation; cn, cortical neuron; oc, oligodendrocyte. H&E. x 960.

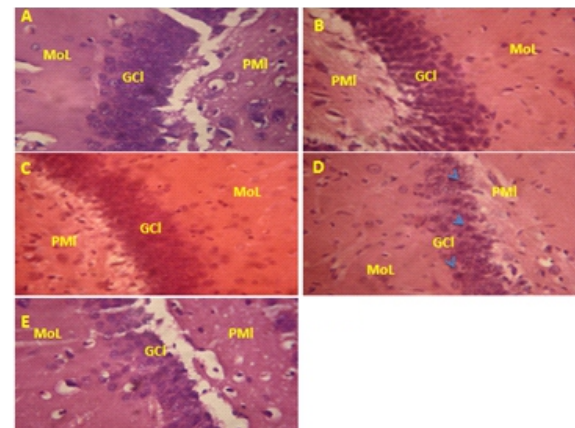
control when compared with the irradiated group of **Fig 3D**.

### Dentate gyrus

The histological features of dentate gyrus showing the molecular layer, granule cell layer and the polymorphic layer are shown in **Figs 4A, 4B,** and **4C**. The effect of radiation is shown in **Fig 4D** with some of the granule cell neurons undergoing pyknotic changes (arrow-heads). **Fig 4E** shows some ameliorative effect of co-treatment of radiation with TPP when compared with **Fig 4D**.



**Fig 3: Representative stained sections of Cornu Ammonis3 of rats.**(a) control rats, (b) PG-treated, (c) TTP-treated, (d) Rad-treated rats show degenerating and angulating pyramidal neurons (arrow-heads) and (e) Rad+TPP-treated. PG, propylene glycol; TTP, tomato pomace powder; Rad, Radiation; SO, stratum oriens layer; Pcl, pyramidal cell layer; SR, stratum radiatum. H&E. x 960.



**Fig 4: Representative stained sections of dentate gyrus of rats.** (a) Dentate gyrus of control rats, (b) PG-treated, (c) TTP-treated, (d) Rad-treated group shows scattered pyknotic neurons in GCl (arrow-heads), and (e) Rad+TPP-treated. PG, propylene glycol; TTP, tomato pomace powder; Rad, radiation; MoL, molecular layer; GCl, granular cell layer; PMI, polymorphic layer. H&E. x 960.

## DISCUSSION

In the present study we investigated the effect of radiation treatment with 5 Gy of gamma rays on some blood parameters and the cerebellum, dentate gyrus (DG) and cornu ammonis3 of rat brain. Data obtained showed alterations between the control and treated animals when compared with irradiated groups.

The alteration of the microanatomy of the cerebellum of rats by radiation shown by the loss of the basophilic staining of the Purkinje cell nuclei occurred in all irradiated rats. The eosinophilia observed in the Purkinje neurons in this experiment indicates complete dissolution of nuclei material termed 'karyolysis' (Stevens and Lowe, 2000). This might lead to poor control and processing of new neuronal protein synthesis, necessary for axonal flow and the maintenance of the integrity of the neuron itself. This might affect the function of the Purkinje cell which is responsible for the sole afferent fibres that

leaves the cerebellum as the superior cerebellar peduncle. This might ultimately affect the main function of the cerebellum which is the coordination of voluntary muscular movements, balance and posture in the affected rats. This was reflected in the reduction of muscle strength reflected by diminution of latency of the forelimb grip and the observed smaller number of crossing movement, which is related to locomotor activity (Reckziegela *et al.*, 2011), in the irradiated rats.

The alteration of the microanatomy of the cornu ammonis3 (CA3) subfield of the hippocampus of rats by radiation was observed by the degeneration of the pyramidal neurons. The implication of this is the possibility of interruption of the nervous impulses transmitted from the granule cell layer of the DG of the hippocampus to the CA3 (Viva and Praag, 2013). This might affect memory trace storage as well as behaviour in the rats as



indicated in the reduction of the number of lines crossed and rearing in the irradiated rats.

The microanatomy of the DGsubfield of the hippocampus of rats was altered by radiation as shown by scattered pyknosis of granule cells of the granule cell layer. This agrees with the findings of Nakaya *et al.* (2005) who reported that radiation may lead to apoptotic death of young neurons. Although markers for apoptosis or neurogenesis were not tested for in our experiment, we appreciate that pyknosis indicates cessation of DNA transcription which is an early sign of cell death (Stevens and Lowe, 2000). The implication of this is the possibility of altering the smooth generation of neural signals from these cells as Mossy fibres to the CA3 subfield of hippocampus. The DG is of particular interest as new dentate granule cells are generated continuously in the adult mammalian brain (Viva and Praag, 2013), and it plays a key role in memory formation (Wu *et al.*, 2012). The observed cell death might affect neuronal precursor cells and memory trace storage in the irradiated rats.

That the erythrocytes parameters remain unaltered despite irradiation is in agreement with Andersen (1970) who ranked them as more radio-resistant than other cellular components of blood. However, the reduction by radiation of the total white cells and especially the neutrophils and lymphocytes observed is supported by the report of Andersen's explanation that cells preparing to divide are more radiosensitive, an example of which these cells are.

Oxidative damage has been implicated as the basis of radiation injury in the brain and other organs by previous workers (Adaramoye, 2008; Owoeye *et al.*, 2010). The brain is particularly vulnerable to oxidative stress due to the high rate of ROS generation without commensurate levels of antioxidant defenses (Villeda-Hernandez *et al.*, 2001). Some plants contain radioprotective compounds that have been identified and are known to elicit strong antioxidant potentials against oxidative stress, these include: *Hibiscus sabdariffa*, *Vernonia*

*amygdalina*, and *Garcinia kola* (Adaramoye *et al.*, 2008; Owoeye *et al.*, 2010; Adaramoye, 2010) respectively. Tomato (*Lycopersicon esculentum* Mill) was considered a good source of antioxidants as previously reported (Wattanathorn *et al.*, 2012; Khalaf *et al.*, 2014), and in this experiment, it has shown radioprotection for the rats' brain and the neutrophils as co-treatment with TPP was able to ameliorate the effects of radiation significantly. The implication of this amelioration is the possibility of enhancing the learning and memory functions attributable to the hippocampus and improved locomotor ability associated with the cerebellum. Since tomato as a phytochemical contains known antioxidants like lycopene, its consumption in the diet may help protect humans who consume it from damage induced by radiation exposure or treatment (Maharwal *et al.*, (2005).

In conclusion, treatment with tomato as TPP was able to ameliorate the alterations elicited by gamma radiation in all the groups which suggests that the inherent property of antioxidant in tomato mitigated the damage caused by radiation.

#### Acknowledgements

Authors gratefully acknowledge Dr. B. O. Akinlade and Mrs A.O. Ekiola for technical assistance during the irradiation procedures at the Department of Radiotherapy, University College Hospital, Ibadan, Nigeria. The valuable review and comments of Prof. V. O. Taiwo, Head, Department of Veterinary Pathology, University of Ibadan on the histological slides are acknowledged and appreciated.

**Declaration of interest:** The authors declare that there is no conflict of interest in this study. The authors alone are responsible for funding of this research and the content and writing of this paper.

#### REFERENCES

ADARAMOYE, O., OGUNGBENRO, B., ANYAEGBU, O. and FAFUNSO, M.

- (2008). Protective effects of extracts of *Vernonia amygdalina*, *Hibiscus sabdariffa* and vitamin C against radiation-induced liver damage in rats. *J Radiat Res*, **49**: 123-131.
- ADARAMOYE, O.A. (2010). Protective effect of kolaviron, a biflavonoid from *Garcinia kola* seeds, in brain of Wistar albino rats exposed to gamma-radiation. *Biol. Pharm. Bull.* **33**(2): 260—266.
- AFIFI, A.K. and BERGMAN, R.A. (2005): Functional neuroanatomy: text and atlas, 2nd edition, McGraw–Hill, New York: 201–222.
- ANDERSEN, A.C. (1970): Effects of ionizing radiation on blood. In *Veterinary Haematology* (2nd edn), Schalm OW (Ed). Lea and Febiger: Philadelphia: 471-477.
- BANCROFT, J.D. and GAMBLE, M. (2008): Theory and practice of histology techniques, 6th edition. Churchill Livingstone Elsevier: 83 - 13
- BÜRGER, M.E. (2011). Locomotor damage and brain oxidative stress induced by lead exposure are attenuated by garlic acid treatment. *Toxicology Letters*, **203**: 74–81
- FAROMBI, E.O. and OWOEYE, O. (2011). Antioxidative and chemopreventive properties of *Vernonia amygdalina* and *Garcinia* biflavonoid. *Int. J. Environ. Res. Public Health*, **8**: 2533-2555; doi: 10.3390/ijerph8062533.
- GRACY, R.W., TALENT, J.M., KONG, Y. and CONRAD, C.C. (1999). Reactive oxygen species: the unavoidable environmental insult? *Mutat. Res.* **428**(1-2): 17-22.
- KHALAF, H.H., SHAROBA, A.M., SADANI, R.A.EL., NASHABY, F.M.EL., and ELSHIEMY, S.M. (2014). Antioxidant properties of some extracts from gamma irradiated tomato (*Lycopersicon esculentum* L.) pomace. *J. Food and Dairy Sci., Mansoura Univ.*, **5**(4): 247–263.
- KANABUR, V. and REDDY, R.P.L. (2014). A Study on antioxidant property of organic and conventional tomatoes. *IOSR J. Agric. and Vet. Sci.* **7**(5): 12-17.
- KREIDER, J.C and BLUMBERG, M.S.. (1999). Geotaxis in 2-week-old Norway rats (*Rattus norvegicus*): A reevaluation. *Dev Psychobiol.*, **35**(1):35-42.
- MAHARWAL, J., SAMARTH, R.M. and SAINI, M.R. (2005). Antioxidant effect of rajgira leaf extract in liver of Swiss albino mice after exposure to different doses of gamma radiation. *Phytother. Res.* **19**: 717-720.
- MALOMO, A.O., OWOEYE, O., ELUMELU, T.N., AKANG, E.E.U., ADENIPEKUN, A., CAMPBELL, O.B. and SHOKUNBI, M.T. (2005). The effect of dexamethasone, metronidazole and ascorbic acid on the morphological changes induced by gamma rays on the spinal cord of Wistar rats. *Afr. J. of Med. and med. sciences*, **34**(2): 161-165.
- MOHAMMAD, S., SHAHRNAZ, P., MASOUD, N., MOAZAMEHOSADAT, R., NASSER, Z., KHADIJE, E. and FATEMEH, A. (2010). Walnut consumption protects rats against cisplatin - induced neurotoxicity. *Neurotoxicology*. doi:10.1016/j.neuro.2012.08.004
- NAKAYA, K., HASEGAWA, T., FLICKINGER, J.C., KONDZIOLKA, D.S. and FELLOWS-MAYLE, W. (2005). Sensitivity to radiation-induced apoptosis and neuron loss declines rapidly in the postnatal mouse neocortex. *Int J Radiat Biol.*, **81**: 545–554.
- OWOEYE, O., FAROMBI, E. and ONWUKA, S.K. (2010). Cerebellar reduction in rats by gamma irradiation is mitigated by pretreatment with methanolic extract of *Vernonia amygdalina* and alpha-tocopherol. *Eur J Anat*, **14**(2): 49-58.
- OWOEYE, O., FAROMBI, E.O. and ONWUKA, S.K. (2011). Gross morphometric reduction of rats' cerebellum by gamma irradiation was mitigated by pretreatment with *Vernonia amygdalina* leaf extract. *Rom J Morphol Embryol* **52**(1): 81-88.
- PUBLIC HEALTH SERVICE (PHS), (1996). Public health service policy on humane care and use of laboratory animals. *US Department of Health and Human Services*, Washington, DC, PL. 99-158.
- RECKZIEGELA, P., DIASC, V.T., BENVENÚA, D., BOUFLEURA, N., BARCELOSA, R.C.S., SEGATC, H.J., PASEC, C.S., SANTOSB, C.M.M.D.,

- FLORESB, E.M.M. and BÜRGER, M.E. (2011). Locomotor damage and brain oxidative stress induced by lead exposure are attenuated by garlic acid treatment. *Toxicology Letters*, **203**: 74–81
- SIEGEL, R., MA, J., ZOU, Z. and JEMAL, A. (2014). Cancer Statistics. *Ca Cancer J. Clin*, **64**: 9-22.
- SNELL, R.S. (2006): Clinical Neuroanatomy. 6<sup>th</sup> Edition. Lippincott Williams & Wilkins co. Philadelphia: 298-308.
- STEVENS, A. and LOWE, J. (2000): Pathology. 2<sup>nd</sup> Edition. Mosby, Edinburgh: 18-33.
- VANWIJK, N., RIJNTJES, E. and VAN DE HEIJNING, B.J. (2008). Perinatal and chronic hypothyroidism impairs behavioural development in male and female rats. *Exp Physiol.*, **93**(11): 1199-209.
- VILLEDA-HERNANDEZ, J., BARROSO, R., MENDEZ, M., NAVA, C., HUERTA, R. and RIOS, C. (2001). Enhanced brain regional lipid peroxidation in developing rats exposed to low level lead acetate. *Brain Res. Bull.*, **55**(2), 247–251.
- VIVAR, C. and VANPRAAG, H. (2013). Functional circuits of new neurons in the dentate gyrus. *Front. Neural Circuits* 7:15. doi: 10.3389/fncir.2013.0001
- WATTANATHORN, J., THUKHAM-MEE, W., MUCHIMAPURA, S., TONG-UN, T. and WANNANON, P. (2012). Tomato, a potential yin food, protects against stroke. *Chinese Medicine*, **3**: 144-150.
- WU, P.H., COULTRAP, S., PINNIX, C., DAVIES, K.D., TAILOR, R., ANG, K.K., BROWNING, M.D., DAVID, R. and GROSSHANS, D.R. (2012). Radiation induces acute alterations in neuronal function. *PLoS ONE* 7 ( 5 ) : e 3 7 6 7 7 . doi:10.1371/journal.pone.003767.