



Vitamin A Deficiency in Commercial Layers - A Case Report

TIJANI, M.O.^{1*} and EMIKPE, B.O.¹

¹Department of Veterinary Pathology, Faculty of Veterinary Medicine, University of Ibadan, Ibadan, Nigeria. Corresponding Author: E-mail: darkman972001@yahoo.com, Tel: +2348035332224

INTRODUCTION

Poultry under intensive production systems are particularly susceptible to avitaminoses due to the fact that they have elevated requirements for vitamins and obtain little or no benefit from microbial production of vitamins in the gastrointestinal tract. High stocking density associated with many modern poultry operations, places immense stress on birds, resulting in an elevation of their vitamin requirements (McDowell, 2006). Vitamin A is essential in poultry diets for growth, optimal vision, and integrity of mucous membranes (Klasing, 2012). Vitamin A has also been reported to play an important role in immune response, cell differentiation, proliferation and morphogenesis by means of regulating gene expression (Surai *et al.*, 1998, Klasing, 2012). The disease condition resulting from lack of vitamin A in poultry diet causes huge losses in poultry farms (Seifried, 1930). The occurrence of this nutritional deficiency in birds has been widely reported by several authors (Paredes and Garcia, 1959; Nockels and Kienholz, 1967; Aye *et al.*, 1999; Uni *et al.*, 2000). Vitamin A deficiency causes squamous metaplasia of the nasal

mucosa and the pharyngeal glands. Grossly, small white nodules are usually found in the nasal passages, mouth, oesophagus, pharynx and in the crop. Yellow caseous masses are found in the eyes, between the turbinate bones, and within the nasolacrimal ducts nasal vestibule and sinuses. Chronic vitamin A deficiency causes damage to the renal tubules leading to azotaemia and visceral ureate deposits (Klasing, 2012). To the author's knowledge, there is no report on the pathology of this nutritional deficiency in commercial layers in Nigeria. Herein we present a case report of avitaminosis A in commercial layers in Ibadan, Nigeria.

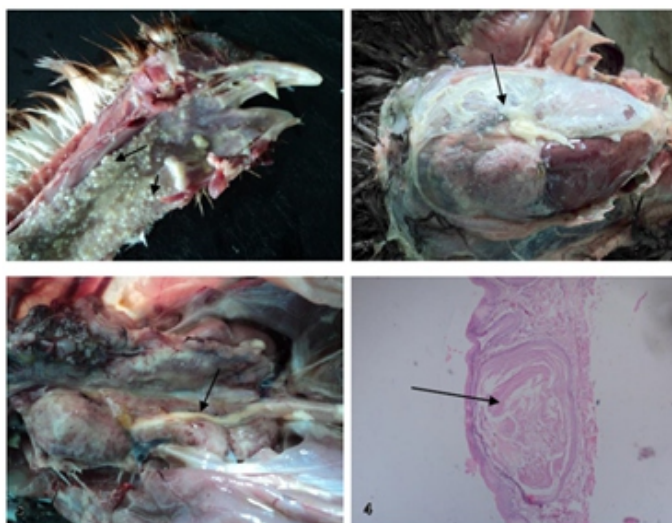
Case History and Diagnosis

Eleven carcasses and three moribund birds from a flock of 6222, seven weeks old Harco chicken layers raised in a poultry layer farm in Ibadan were presented for necropsy in the Department of Veterinary Pathology, University of Ibadan, Ibadan. The farm had recorded mortalities of 2652 over a period of seven weeks. At day old, most birds in the flock started to void greyish mucoid faeces. Mortalities started soon afterwards, averaging about 9 birds per day in the first week of life. At 2 weeks, some of the birds showed signs of leg

paralysis and tremors involving the leg muscles and head. Some of the apparently healthy birds died suddenly without showing any clinical sign. Subsequently, a vitamin supplement (vitalite®) was administered to the birds daily for 5 weeks. In spite of this intervention, mortalities increased dramatically in the fourth week of life. Average daily mortality from fourth week up till the seventh week of life was 100 birds. In the sixth week, the farmer noticed the following signs in most of the remaining birds: masses of thick yellowish cheesy exudates on the palpebral and bulbar conjunctiva, greenish white diarrhoea, anorexia, and emaciation. Postmortem was carried out on 14 carcasses. The 3 moribund birds were euthanized by cervical dislocation prior to necropsy. At necropsy, all the carcasses were severely emaciated and runtish. Ten out of fourteen carcasses had masses of yellowish white, caseous material in the bulbar and palpebral conjunctivae, and nasal sinuses. The mucosal surface of the oropharynx and buccal cavity in three carcasses exhibited multiple whitish

nodules with sizes ranging from 0.1 to 0.2 cm in diameter (Fig.1). Other lesions observed at necropsy include defeathering (four carcasses), ureate deposition in the pericardium, liver capsule, and in the kidneys/ureters (Figs.2 and 3) (7 carcasses), caecal caseous cores (5 carcasses), pulmonary haemorrhages (2 carcasses), pulmonary congestion (3 carcasses) and caecal tonsillar haemorrhages (3 carcasses). The oropharynx and oesophagus were collected, fixed in 10% neutral buffered formalin for 24 hours, routinely processed for histology and stained with haematoxylin and eosin. Histology of the oropharynx and oesophagus revealed markedly ectatic submucosal glands with lumina occluded by eosinophilic lamellations of keratin (Fig.4). The glandular epithelia of the submucosal glands are also completely replaced by lamellations of keratin. A few pharyngeal and submucosal glands show coagulative necrosis of the epithelium and infiltration with moderate numbers of heterophils.

PICTURES



LEGEND FOR PICTURES

Fig.1: Oral cavity and oesophagus of chicken showing numerous small nodules in the mucosa of the oropharynx and oesophagus (arrows)

Fig.2: Abdominal cavity of chicken showing abundant ureate deposit on the surfaces of the liver and abdominal viscera (arrow).

Fig.3: Abdominal cavity of chicken showing moderately enlarged, pale kidneys with ureters distended with ureate (arrow).

Fig.4: Photomicrograph of chicken oesophagus with nodules showing markedly distended, keratin filled submucosal gland (arrow). H&E, x40

DISCUSSION

The case was diagnosed as avitaminosis A based on the gross findings and histopathology. The findings here, with the exception of pulmonary haemorrhages and congestion and caecal tonsillar haemorrhages are similar to those reported for vitamin A deficiency in poultry by Seifried (1930); Aye *et al.* (1999); Cortes *et al.* (2006); and Klasing (2012). The gross lesions of pulmonary haemorrhages and congestion as well as caecal tonsillar haemorrhages are not characteristic of vitamin A deficiency in birds. These additional gross lesions as well as the very high mortality observed are similar to the features of Newcastle disease, though no further test was done to confirm this. Several authors have tried to establish a relationship between Newcastle disease and avitaminosis A in poultry. Squibb *et al.*, (1955) reported that naturally occurring infections of Newcastle disease significantly depressed serum vitamin A and carotenoids levels in New Hampshire chickens. Similarly, Sijtsma *et al.*, (1989a) reported that pre-existing marginal vitamin A status increases the severity of disease following NDV infection, and that infection with NDV reduces marginal plasma vitamin A levels to levels which can be regarded as deficient. Furthermore, Sijtsma *et al.*, (1989b) suggested that the reduced vitamin A status in marginally vitamin A-deficient chickens infected with NDV can be attributed to a combination of a direct effect of the virus on retinol-binding protein metabolism in the liver and an increased rate of utilization and catabolism of retinol and retinol-binding protein by extra hepatic tissues. In light of these facts, it is highly probable that the flock in this case was infected with NDV in the first week of life and as the disease progressed, it led to a marked reduction in serum vitamin A levels resulting in avitaminosis A which could not be resolved even with dietary vitamin supplementation for five weeks. In addition, it is also possible that the chickens were fed a diet severely deficient in vitamin A. This chronic deficiency of vitamin A consequently resulted in the damage of the renal tubules leading to

azotaemia and visceral ureate deposits. The other consequences of this vitamin deficiency in this flock include cessation of growth (runting), abundant caseous exudate in the eyes and sinuses, and severe defeathering. These lesions are consistent with reported lesions of vitamin A deficiency in poultry (Seifried, 1930; Aye *et al.*, 1999; Cortes *et al.*, 2006; and Klasing, 2012).

CONCLUSION

This case report has shown that there is a possible interaction between vitamin A deficiency and Newcastle disease in poultry. This possible association should be further elucidated by researchers in our environment.

REFERENCES

- AYE, P.P., MORISHITA, T.Y., SAIF, Y.M., LATSHAW, J.D., HARR, B.S., and CIHLA, F.B. (1999): Induction of vitamin A deficiency in turkeys. *Avian diseases*, 44(4), 809-817.
- CORTES, P.L., TIWARY, A.K., PUSCHNER, B., CRESPO, R.M., CHIN, R.P., BLAND, M., and SHIVAPRASAD, H.L. (2006): Vitamin A deficiency in turkey poults. *Journal of veterinary diagnostic investigation*, 18(5), 489-494.
- KLASING, K.C. (2012): Nutritional Diseases. In: Diseases of Poultry, ed. Saif Y.M., Fadly A.M., Glisson J.R., McDougald L.R., Nolan L.K. and Swayne D.E., 12th ed., pp. 1121–1148. Blackwell Publishing, Ames, IA.
- MCDOWELL, L.R. (2006): Vitamin nutrition of livestock animals: Overview from vitamin discovery to today. *Canadian journal of animal science*, 86(2), 171-179.
- NOCKELS, C.F. and KIENHOLZ, E.W. (1967): Influence of vitamin A deficiency on testes, bursa fabricius, adrenal and hematocrit in cockerels. *J. Nutr.* 92:384–388.
- PARADES, J.R., and GARCIA, T.P. (1959): Vitamin A as a factor affecting fertility in cockerels. *Poult. Sci.* 38:3–7.
- SEIFRIED, O. (1930): Studies on A-avitaminosis in chickens II. Lesions of the upper alimentary tract and their relation to some infectious diseases. *The Journal of*

experimental medicine, 52(4), 533-538.

SIJTSMA, S.R., WEST, C.E., ROMBOUT, J.H. and VAN DER ZIJPP, A.J. (1989a): The interaction between vitamin A status and Newcastle disease virus infection in chickens. *The Journal of nutrition*, 119(6), 932-939.

SIJTSMA, S.R., WEST, C.E., ROMBOUT, J.H. and VAN DER ZIJPP, A.J. (1989b): Effect of Newcastle disease virus infection on vitamin A metabolism in chickens. *The Journal of nutrition*, 119(6), 940-947.

SQUIBB, R.L., BRAHAM, J.E., GUZMAN, M. and SCRIMSHAW, N.S. (1955): Blood serum total proteins, riboflavin, ascorbic acid, carotenoids and vitamin A of New Hampshire chickens infected with coryza, cholera or Newcastle disease. *Poultry Science*, 34(5), 1054-1058.

SURAI, P.F., IONOV, I.A., KUKLENKO, T.V., KOSTJUK, I.A., ACPHERSON, A.M., SPEAKE, B.K. and SPARKS, N.H.C. (1998): Effect of supplementing the hen's diet with vitamin A on the accumulation of vitamins A and E, ascorbic acid and carotenoids in the egg yolk and in the embryonic liver. *British Poultry Science*, 39(2), 257-263.

UNI, Z., G. ZAIGER, O. GAL-GARBER, M. PINES, I. ROZENBOIM, and R. REIFEN. (2000): Vitamin A deficiency interferes with proliferation and maturation of cells in the chicken small intestine. *British Poult. Sci.* 41:410-415.